



Discover Generics

Cost-Effective CT & MRI Contrast Agents

 FRESENIUS
KABI

[WATCH VIDEO](#)

AJNR

High Uptake of ^{123}I -metaiodobenzylguanidine Related to Olfactory Neuroblastoma Revealed by Single-photon Emission CT

Toshio Sasajima, Hiroyuki Kinouchi, Noriaki Tomura, Jiro Watarai and Kazuo Mizoi

This information is current as of June 6, 2025.

AJNR Am J Neuroradiol 2000, 21 (4) 717-720
<http://www.ajnr.org/content/21/4/717>

High Uptake of ^{123}I -metaiodobenzylguanidine Related to Olfactory Neuroblastoma Revealed by Single-photon Emission CT

Toshio Sasajima, Hiroyuki Kinouchi, Noriaki Tomura, Jiro Watarai, and Kazuo Mizoi

Summary: We studied a case of olfactory neuroblastoma by noting ^{123}I -metaiodobenzylguanidine (MIBG) uptake revealed by single-photon emission CT (SPECT). MR imaging revealed an enhancing tumor extending from the left nasal cavity to the bilateral anterior frontal cranial fossae. SPECT revealed high ^{123}I -MIBG uptake in the enhancing tumor. SPECT-revealed ^{123}I -MIBG uptake appears to be clinically useful for distinguishing olfactory neuroblastomas from other tumors, especially suprasellar meningiomas.

An olfactory neuroblastoma is a rare malignant tumor that originates in the olfactory epithelium of the superior nasal cavity. CT scanning typically reveals adjacent bony destruction of adjacent bones, and postcontrast MR imaging has been shown to be helpful in depicting tumor extension and staging of olfactory neuroblastoma. Radiographic findings of olfactory neuroblastoma, however, are usually similar to those of other tumors of the paranasal sinuses, and a definitive tumor diagnosis often is not possible to make on the basis of MR imaging alone (1).

Neuroblastomas belong to a group of neuroendocrine tumors that are thought to arise from cells in the neural crest. Recently, newly developed radiopharmaceutical agents have had an impact on the diagnosis of neural crest tumors on the basis of specific uptake and storage mechanisms, whereas radionuclide methods for imaging olfactory neuroblastomas have not substantially advanced. Ramsay et al described a case of olfactory neuroblastoma with strong expression of somatostatin receptors, shown by gamma imaging with ^{111}In -octreotide, a somatostatin analog (2). This tracer, however, is not suitable for distinguishing olfactory neuroblastomas from other tumors, especially suprasellar meningiomas, because somatostatin receptor expression has been shown in various brain

tumors (eg, meningiomas, gliomas, and pituitary adenomas) (3).

In contrast, the accumulation of metaiodobenzylguanidine (MIBG), a functional analog of the neurotransmitter norepinephrine, has been related to specific uptake and storage mechanisms in neuroblastomas (4). Abnormally high uptake of MIBG has been documented in 73–96 % of patients with extracranial neuroblastoma, and the specificity has been extremely high (5–8). To our knowledge, however, ^{123}I -MIBG uptake in olfactory neuroblastomas is not described in the literature. In the present study, we applied single-photon emission CT (SPECT) to examine ^{123}I -MIBG uptake in olfactory neuroblastoma to establish a preoperative diagnosis.

Case Report

A 66-year-old man presented with a 6-month history of epistaxis. Just before admission to the hospital, he had suffered from bilateral visual disturbance. Neurologic examination disclosed anosmia, papilledema, and decreased bilateral visual acuity. CT scanning revealed a huge enhancing tumor without calcification, extending from the left nasal cavity into the anterior frontal cranial fossae, and destroying the surrounding bone. The tumor was slightly hypointense on T1-weighted MR images (380/13/2 [TR/TE/excitations]), hyperintense on T2-weighted MR images (4800/108/2), and strongly enhanced after administration of contrast medium (Fig 1, 2). Cerebral angiograms revealed a tumor blush fed by bilateral anterior ethmoidal arteries and the left posterior ethmoidal artery.

On the basis of the neuroradiologic findings, olfactory neuroblastoma was suspected as a preoperative diagnosis. Because ^{123}I -MIBG has been shown to accumulate in the neural crest tumors, we examined ^{123}I -MIBG uptake by imaging this patient with SPECT. SPECT images 30 minutes after IV injection of ^{123}I -MIBG at a dose of 111 MBq revealed the accumulation of ^{123}I -MIBG in the tumor. The ratio of tumor (area of highest uptake)/nontumor (T/NT), as an indicator of selective uptake in the tumor, was 2.3. The bilateral temporal lobes were considered representative of nontumor regions (Fig 3).

Total removal of the tumor was performed successfully through extended bifrontal craniotomy. The histologic diagnosis was neuroblastoma. Fourteen months after postoperative radiotherapy (54 Gy to the tumor bed), the patient has been free of symptoms, showing no evidence of tumor regrowth on follow-up MR images.

Discussion

To our knowledge, this is the first report of ^{123}I -MIBG accumulation in the presence of olfactory neuroblastoma. MIBG was developed as a func-

Received October 11, 1999; accepted after revision November 22.

From the Neurosurgical Service (T.S., H.K., K.M.) and Department of Radiology (N.T., J.W.), Akita University School of Medicine, Akita, Japan.

Address reprint requests to Toshio Sasajima, M.D., Neurosurgical Service, Akita University School of Medicine, 1-1-1 Hondo, Akita 010-8543 Japan.

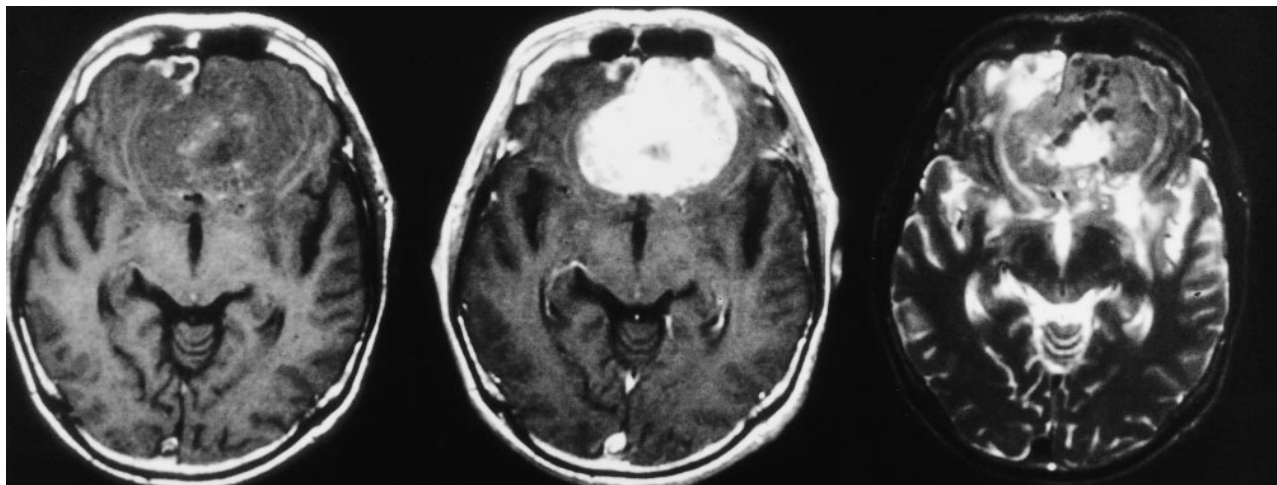
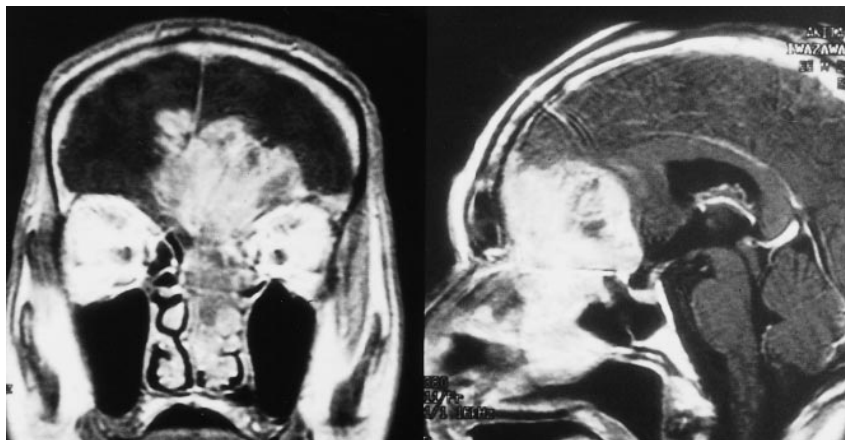


FIG 1. Axial-plane MR images show expansile bifrontal tumor with dense enhancement (from *left to right*: T1-weighted image [380/13/2], postcontrast T1-weighted image [380/13/2], and T2-weighted image [4800/108/2]).

FIG 2. Coronal (*left*) and sagittal (*right*) planes on postcontrast T1-weighted images (380/13/2) reveal an enhancing tumor extending from the left nasal cavity into anterior frontal cranial fossae.



tional analog of the neurotransmitter norepinephrine. MIBG enters adrenergic cells through a sodium- and energy-dependent uptake mechanism (so-called uptake-one amine transport mechanism) and then resides in and leaves the chromaffin storage vesicles of adrenomedullary tissue (9). The success of MIBG as an imaging agent for neural crest tumors is derived from its chemical similarities to norepinephrine. In neural crest tumor cells, such as pheochromocytomas and paragangliomas, MIBG is specifically taken up by the uptake-one amine transport mechanism at the cell membrane and then transported into and stored within the neurosecretory granules in the cytoplasm. More than 90% of storage occurs in the granules, and a positive relationship between the amount of neurosecretory granules and radioiodinated MIBG uptake has been found. In neuroblastomas, although MIBG is predominantly taken up by the uptake-one amine transport mechanism (10, 11), the lack of a relationship between the amount of neurosecretory granules and radioiodinated MIBG uptake (4), and the finding that up to 60% of storage is extragranular (11), have been documented. Regarding the intracellular localization of MIBG in neuroblastoma

cells, most of the ^{131}I -labeled MIBG is found within mitochondria, whereas electron spectroscopic imaging shows fewer are present in specific neurosecretory granules of human neuroblastoma cells (12).

The clinical utility of MIBG as a tracer for detection of neural crest tumors has been well publicized. Abnormally high uptake of MIBG has been documented in 73–96% of patients with extracranial neuroblastoma (5–8), whereas the reported specificity is 93% or more (5–8). In a retrospective study of 100 children with nonsympathomedullary lesions, all had negative MIBG scans except four who had lesions, two of which were diagnosed as neural crest tumors (primitive neuroectodermal tumor and neuroendocrine carcinoma) and two of which were diagnosed as non-neural crest tumors (pancreaticoblastoma and infantile myofibromatosis) (13). The diagnostic value of MIBG scintigraphy in extracranial neuroblastomas is the result of the combination of its high sensitivity and specificity.

In normal distribution, MIBG accumulates in the salivary glands, liver, urinary bladder, gastrointestinal tract, heart, and lung (14, 15). Intracra-

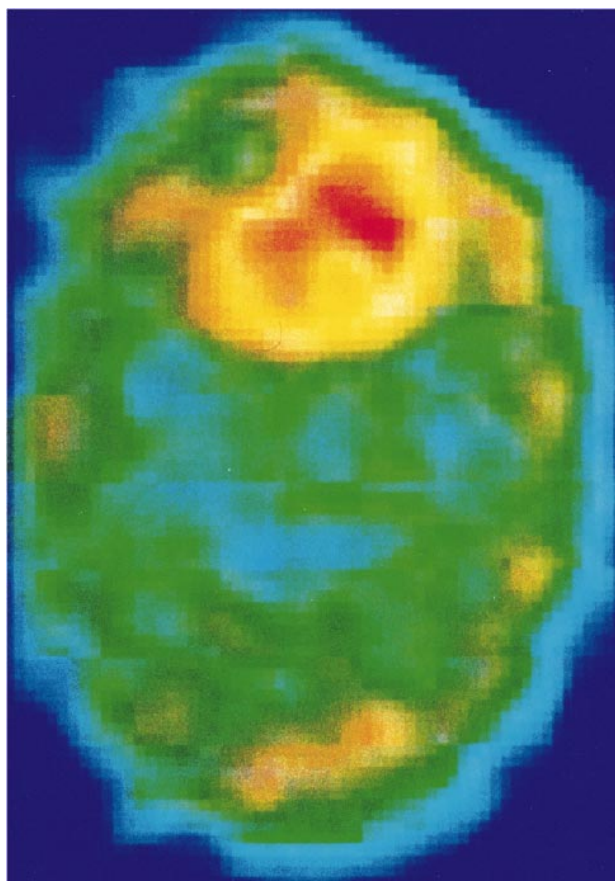


FIG 3. Axial-plane ^{123}I -MIBG SPECT image 30 minutes after IV injection of ^{123}I -MIBG at a dose of 111 MBq shows intense uptake in the tumor.

nial MIBG uptake is only occasionally and faintly visible because of the intact blood-brain barrier (BBB), although the brain is richly endowed with adrenergic neurons (16, 17). In this study, ^{123}I -MIBG SPECT was therefore proposed for the detection of intracranial lesions of neural crest tumors, because SPECT has been a common imaging technique for the investigation of brain tumors. SPECT performed after IV injection of ^{123}I -MIBG for detecting olfactory neuroblastomas has not been previously described. In this case, we confirmed the increased accumulation of ^{123}I -MIBG on the early SPECT images in a case of olfactory neuroblastoma. We concurrently examined ^{123}I -MIBG SPECT in four consecutive patients with meningiomas, including one case of planum sphenoidale meningioma. Among four patients with meningiomas, the T/NT ratio on the early SPECT images obtained 30 minutes after tracer administration was 1.33 ± 0.32 (range, 1.1–1.6), which was much lower than that of olfactory neuroblastoma (unpublished data [personal experience in our hospital]). Based on ^{123}I -MIBG SPECT findings, we could preoperatively distinguish olfactory neuroblastomas from suprasellar meningiomas.

Some authors (18, 19) have suggested strategies for the rational use of preoperative radiochemotherapy for this tumor type, which was thought to be inoperable. Goldsweig et al (18) documented that cisplatin-based combinations of chemotherapy in a patient with advanced disease converted a previously inoperable tumor into one that could be resected. At surgery, they confirmed that most of the tumor was necrotic, representing a true response to chemotherapy. This tumor type is sensitive to radiotherapy and several different combinations of chemotherapy, whereas meningioma is less sensitive to radiochemotherapy. Therefore, on the basis of ^{123}I -MIBG SPECT findings, preoperative differential diagnosis of olfactory neuroblastoma from suprasellar meningioma might provide important information for selecting optimal therapeutic strategies for this tumor.

Conclusion

These results support the conclusion that preoperative, accurate diagnosis of olfactory neuroblastoma achieved using ^{123}I -MIBG SPECT may be important for choosing the appropriate strategy in the management of this kind of tumor type.

References

1. Derdeyn CP, Moran CJ, Wippold II FJ, Chason DP, Koby MB, Rodriguez F. **MRI of esthesioneuroblastoma.** *J Comput Assist Tomogr* 1994;18:16–21
2. Ramsay HA, Kairemo KJA, Jekunen AP. **Somatostatin receptor imaging of olfactory neuroblastoma.** *J Laryngol Otol* 1996;110:1161–1163
3. Lamszus K, Meyerhof W, Westphal M. **Somatostatin and somatostatin receptors in the diagnosis and treatment of gliomas.** *J Neurooncol* 1997;35:353–364
4. Wafelman AR, Hoefnagel CA, Maes RAA, Beijnen JH. **Radioiodinated metaiodobenzylguanidine: a review of its biodistribution and pharmacokinetics, drug interactions, cytotoxicity and dosimetry.** *Eur J Nucl Med* 1994;21:545–559
5. Hoefnagel CA. **Metaiodobenzylguanidine and somatostatin in oncology: role in the management of neural crest tumours.** *Eur J Nucl Med* 1994;21:561–581
6. Lumbroso JD, Guermazi F, Hartmann O, et al. **Meta-iodobenzylguanidine (mIBG) scans in neuroblastoma: sensitivity and specificity, a review of 115 scans.** *Prog Clin Biol Res* 1988;271:689–705
7. Rufini V, Giordano A, Di Giuda D, et al. **[^{123}I] MIBG scintigraphy in neuroblastoma: a comparison between planar and SPECT imaging.** *Q J Nucl Med* 1995;39 (suppl 4):25–28
8. Troncone L, Rufini V, Montemaggi P, Danza FM, Lasorella A, Mastrangelo R. **The diagnostic and therapeutic utility of radioiodinated metaiodobenzylguanidine (MIBG) 5 years of experience.** *Eur J Nucl Med* 1990;16:325–335
9. Sisson JC, Wieland DM, Sherman P, Mangner TJ, Tobes MC, Jacques S. **Metaiodobenzylguanidine as an index of the adrenergic nervous system integrity and function.** *J Nucl Med* 1987;28:1620–1624
10. Buck J, Bruchelt G, Girgert R, Treuner J, Niethammer D. **Specific uptake of m-[^{123}I] iodobenzylguanidine in the human neuroblastoma cell line SK-N-SH.** *Cancer Res* 1985;45:6366–6370
11. Smets LA, Loesberg C, Janssen M, Metwally EA, Huiskamp R. **Active uptake and extravesicular storage of m-iodobenzylguanidine in human neuroblastoma SK-N-SH cells.** *Cancer Res* 1989;49:2941–2944
12. Gaze MN, Huxham IM, Mairs RJ, Barrett A. **Intracellular localization of metaiodobenzyl guanidine in human neuroblastoma cells by electron spectroscopic imaging.** *Int J Cancer* 1991;47:875–880

13. Leung A, Shapiro B, Hattner R, et al. **Specificity of radioiodinated MIBG for neural crest tumors in childhood.** *J Nucl Med* 1997;38:1352–1357
14. Nakajo M, Shapiro B, Copp J, et al. **The normal and abnormal distribution of the adrenomedullary imaging agent m-[I-131] iodobenzylguanidine (I-131 MIBG) in man: evaluation by scintigraphy.** *J Nucl Med* 1983;24:672–682
15. Paltiel HJ, Gelfand MJ, Elgazzar AH, et al. **Neural crest tumors: I-123 MIBG imaging in children.** *Radiology* 1994;190:117–121
16. Bomanji J, Moyes J, Huneidi AHS, et al. **Cerebral uptake of MIBG: adrenoceptors visualized?** *Nucl Med Commun* 1991;12:3–13
17. Dwamena BA, Zempel S, Klopper JF, Van Heerden B, Wieland D, Shapiro B. **Brain uptake of iodine-131 metaiodobenzylguanidine following therapy of malignant pheochromocytoma.** *Clin Nucl Med* 1998;23:441–445
18. Goldsweig HG, Sundaresan N. **Chemotherapy of recurrent esthesioneuroblastoma.** *Am J Clin Oncol* 1990;13:139–143
19. Polin RS, Sheehan JP, Chenelle AG, et al. **The role of preoperative adjuvant treatment in the management of esthesioneuroblastoma: the University of Virginia experience.** *Neurosurgery* 1998;42:1029–1037