



Discover Generics

Cost-Effective CT & MRI Contrast Agents



WATCH VIDEO

AJNR

Hemangioendothelioma of the Parotid Gland in Infants: Sonography and Correlative MR Imaging

Derek J. Roebuck and Anil T. Ahuja

AJNR Am J Neuroradiol 2000, 21 (1) 219-223

<http://www.ajnr.org/content/21/1/219>

This information is current as of June 6, 2025.

Hemangioendothelioma of the Parotid Gland in Infants: Sonography and Correlative MR Imaging

Derek J. Roebuck and Anil T. Ahuja

BACKGROUND AND PURPOSE: Hemangioendothelioma is the most common parotid gland tumor of childhood, and is diagnosed on clinical grounds, supported by imaging findings. Previous work has suggested that MR is the best imaging technique for assessment of parotid hemangioendothelioma. Demonstration of a reliable sonographic appearance would reduce the need for MR imaging in infants with this lesion.

METHODS: We performed high-frequency sonography (including color Doppler and power Doppler imaging) in three patients, each with a diagnosis of parotid hemangioendothelioma confirmed by clinical follow-up. Two patients were also examined with MR imaging and labeled red cell scintigraphy.

RESULTS: All sonographic studies showed a homogeneous mass enlarging and replacing most or all of the visualized parotid gland, with a lobular internal structure, fine echogenic internal septations, and a mildly lobulated contour. Color Doppler and power Doppler imaging showed extremely high vascularity within the mass. Correlative MR images in two infants showed a well-defined lesion with uniform intense contrast enhancement. Labeled red cell scintigraphy showed a well-defined area of intense activity.

CONCLUSION: In the presence of a typical clinical history, sonography and clinical follow-up alone may prove to be sufficient for safe management of parotid hemangioendothelioma. MR imaging or labeled red cell scintigraphy may only be required if the sonographic features are atypical. These findings require confirmation in a larger series of patients.

Hemangioendothelioma (HAE), or hemangioma, of the parotid gland is a benign tumor that presents in infancy as a large, rapidly growing mass that is either small or not noticed at birth, but becomes apparent soon after (1, 2). There may be one or more cutaneous ("strawberry") hemangiomas, or the parotid lesion itself may extend to involve the skin.

Accurate identification of parotid HAE is important in order to avoid unnecessary biopsy or therapy (1). Confirmation of the clinical diagnosis with MR imaging has been recommended, but the use of sonography as an alternative has not been widely adopted. We reviewed the sonographic findings of HAE of the parotid in three infants, two of whom also underwent MR imaging and labeled red cell scintigraphy (RCS).

Methods

Three infants, two female and one male, aged 1, 2, and 3 months at presentation, were diagnosed with parotid HAE on the basis of the typical clinical signs and natural history. Sonography was performed in each patient by using 10-MHz linear-array transducers. All patients were imaged with color Doppler and power Doppler imaging, as well as pulsed-wave Doppler interrogation.

Two patients underwent further imaging by MR and RCS. MR examinations were performed at 1.5 T, using head coils and surface coils. Transverse T1-weighted and fat-suppressed T2-weighted as well as contrast-enhanced T1-weighted transverse and coronal images were obtained. A modified in vitro labeling technique was used for RCS. Planar and single-photon-emission CT (SPECT) images were obtained.

Case Histories

Case 1

A 2-month-old female infant presented with a right-sided facial mass that had first been noticed 1 month previously. The child was otherwise well and the pregnancy and delivery had been unremarkable. Sonography (Fig 1A-B) and MR imaging (Fig 1C-D) were performed immediately. RCS (Fig 1E) was performed at the age of 3 months. The lesion was not treated, and subsequently increased in size. A significant decrease in size was

Received April 15, 1999; accepted after revision July 7, 1999.
From the Department of Diagnostic Radiology and Organ Imaging, Chinese University of Hong Kong, Hong Kong, China.

Address reprint requests to Derek Roebuck, Department of Radiology, Great Ormond Street Hospital for Children, Great Ormond Street, London WC1N 3JH England.

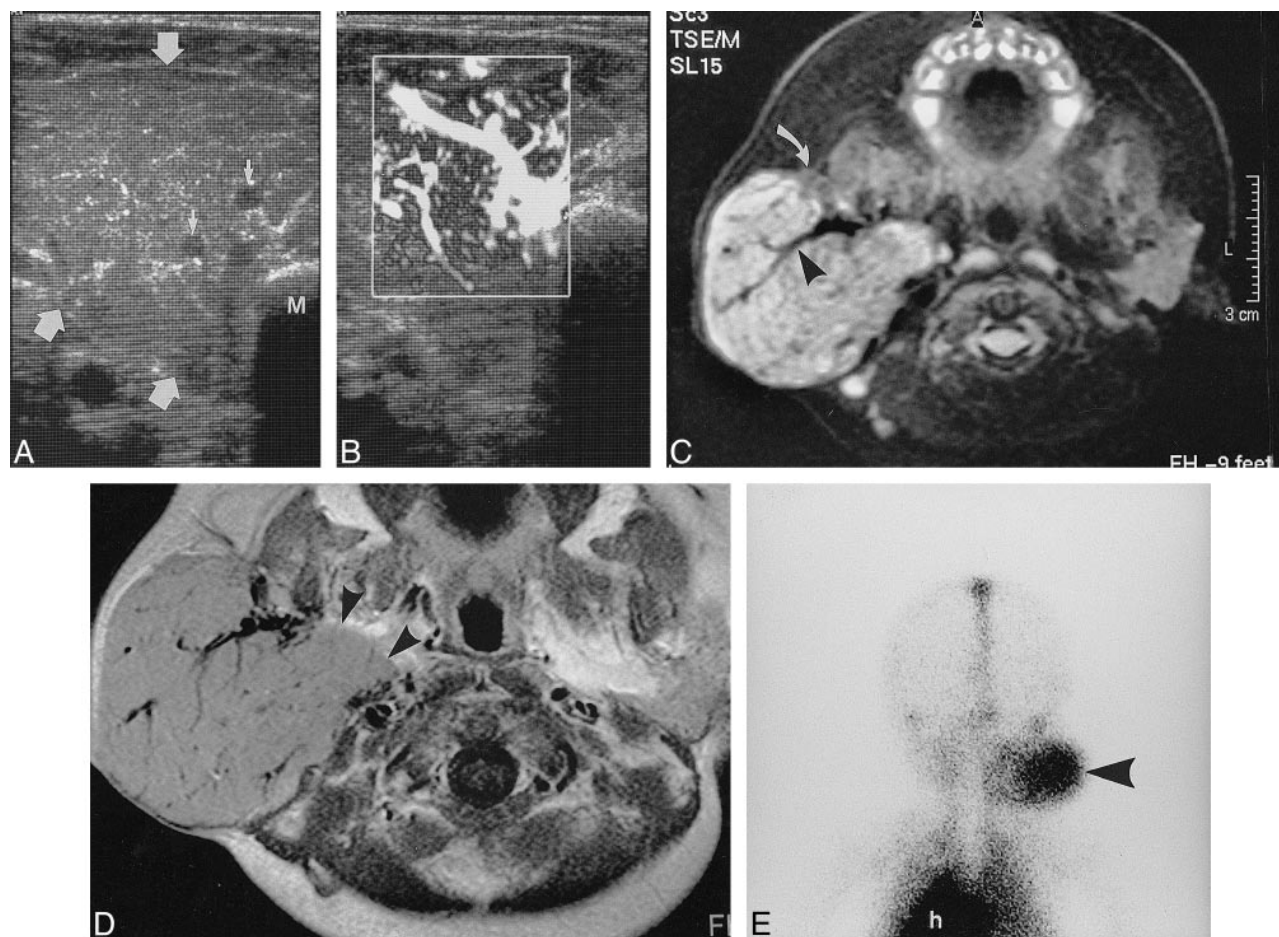


FIG 1. Two-month-old female infant with right parotid hemangioendothelioma.

A, Transverse sonographic image shows a mildly lobulated tumor of intermediate echogenicity (*large arrows*) that enlarges and almost completely replaces the normal parotid gland. There are fine echogenic septations and large intratumoral blood vessels (*small arrows*). Note that involvement of the deep lobe of the gland is incompletely assessed because of the intervening mandibular angle (M).

B, Power Doppler imaging shows numerous large vessels within the tumor.

C, Fat-suppressed T2-weighted transverse image shows the mass to be hyperintense to the small amount of residual normal parotid (*curved arrow*, see also contralateral side). Large flow voids (*arrowhead*) represent intratumoral vessels.

D, Contrast-enhanced T1-weighted transverse image shows enhancement of the solid portion of the mass, which extends to involve the entire deep lobe (*arrowheads*).

E, Delayed planar image from ^{99m}Tc -labelled red cell scintigraphy (*posterior view*) shows uniform, well-circumscribed uptake (*arrowhead*), similar to that in the heart (h). Early dynamic images (not shown) revealed greater activity in the lesion than the heart in the first minute after injection.

apparent when the child was last seen, at the age of 15 months.

Case 2

A female infant was born prematurely at a gestational age of 34 weeks, and remained in hospital for 3 weeks because of neonatal jaundice. Approximately 1 week later, the parents noticed a right-sided facial mass. This gradually increased in size, and sonography (Fig 2A-B), MR imaging (Fig 2C-D), and RCS (Fig 2E-F) were performed at 3 months of age. Treatment with subcutaneous injections of interferon $\alpha 2a$ was commenced at 4 months because of further increase in size. When last seen at the age of 11 months, the lesion was becoming slightly smaller according to the child's mother.

Case 3

A male infant was delivered by cesarean section owing to post-maturity. A small red skin lesion was noticed in the right parotid region at birth. A slowly growing mass was first noted at 2 weeks. The child presented at 2 months, and sonography was performed. The findings (not shown) were identical to those found in the first two patients. At 12 months, the lesion had started to decrease in size. The patient was last seen at 42 months; the lesion had become progressively smaller.

Results

Gray-scale sonography showed a homogeneous mass enlarging and replacing most or all of the visualized parotid gland in all patients. The internal

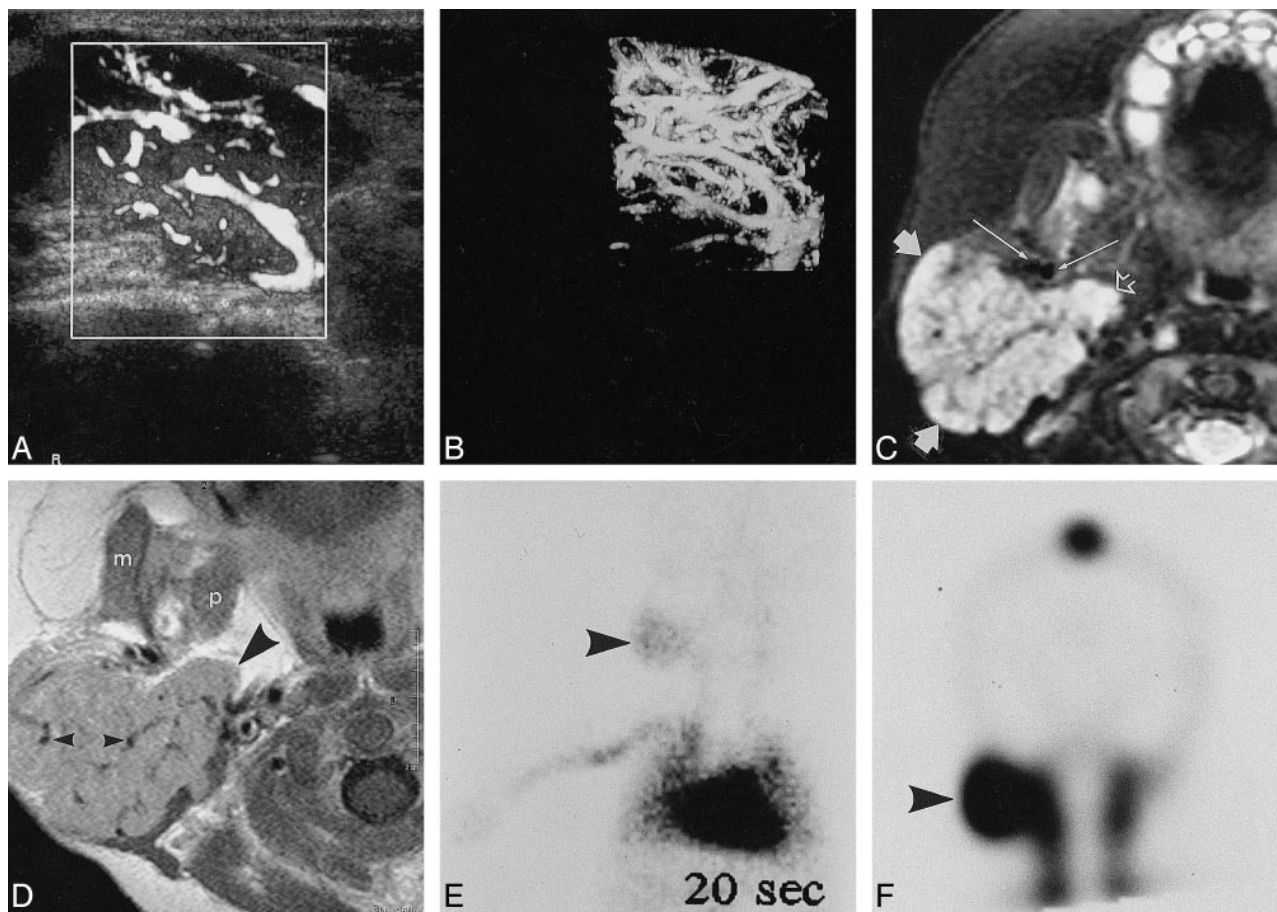


FIG 2. Three-month-old female patient with right parotid hemangioendothelioma.

A, Power Doppler imaging shows numerous large intratumoral vessels, demonstrated to be branches of the external carotid artery and tributaries of the retromandibular vein.

B, Three-dimensional power Doppler imaging confirms the extreme vascularity of the parotid mass.

C, Fat-suppressed T2-weighted transverse image shows a hyperintense mass (*small solid arrows*) with numerous intratumoral vessels. Extension into the deep lobe (*open arrow*) is well shown. Long arrows identify the external carotid artery (*medial*) and retromandibular vein (*lateral*).

D, Contrast-enhanced T1-weighted transverse image shows enhancement of the solid portion of the mass, which involves the entire deep lobe (*large arrowhead*), and contains numerous large vessels (*small arrowheads*). The masseter (m) and medial pterygoid (p) are not involved.

E, Dynamic image from ^{99m}Tc -labelled red cell scintigraphy (*anterior view*, acquired at 20 seconds) shows uptake in the lesion (*arrowhead*), less than that in the heart.

F, Delayed coronal SPECT image shows intense uptake in a sharply defined lesion (*arrowhead*).

structure was lobular, with fine echogenic internal septations and a mildly lobulated contour (Fig 1A). Color Doppler and power Doppler imaging demonstrated numerous large blood vessels within the mass in each case (Figs 1B, 2A, and 2B). Pulsed-wave Doppler examination of the intratumoral vessels confirmed that these comprised both arteries and veins.

Fat-suppressed T2-weighted MR images showed enlargement of the parotid gland, which was almost entirely replaced by a markedly hyperintense lesion (Figs 1C and 2C). T1-weighted images showed the lesion to be approximately isointense to skeletal muscle, with marked and uniform contrast enhancement (Figs 1D and 2D). All sequences showed large vessels within the mass as flow voids (Figs 1C–D and 2C–D).

RCS showed early uptake of labeled red cells in the lesions on dynamic images. In both patients, delayed images showed a well-defined area of intense activity, similar to that in the heart and great vessels (Figs 1E and 2E–F).

Discussion

HAE of the parotid gland is the most common parotid tumor of childhood (3, 4). Because of its benign clinical course, it is underrepresented in biopsy series. The median age at presentation is about 4 months (3), and the diagnosis is rarely made after 16 months (3). Girls are more commonly affected than boys, by a ratio of about 3:1 (3, 5).

Because of the benign nature of this lesion, accurate clinical and radiologic diagnosis is important so that unnecessary biopsy may be avoided (1). Any large, rapidly growing parotid mass in an infant, particularly if it is small or unnoticed at birth, is most likely to be HAE. HAEs are often multiple, and the diagnosis is supported, but not proved, by the presence of a cutaneous lesion ("strawberry hemangioma"), either locally (3, 5) or at a remote site (1, 5). The natural history of HAE is rapid enlargement in infancy (the proliferative phase), followed by gradual spontaneous involution, starting at about 8 to 18 months, and continuing until the age of 5 to 8 years (2). Significant systemic complications such as cardiac failure (6) or Kasabach-Merritt syndrome (7) are rare. When they occur, therapy with oral corticosteroids or interferon $\alpha 2a$ or both may be used, although these may be less successful for parotid lesions than for hemangiomas arising at other sites (5). Surgical resection is not recommended because of the risk of damage to the facial nerve and favorable prognosis with expectant management (3).

Sonography (Figs 1A–B and 2A–B) has important advantages as a single imaging investigation for parotid masses of infancy. It is safe, inexpensive, and does not require sedation of the patient. In our patients, sonography at 10 MHz showed a homogeneous mass enlarging and replacing most of the parotid gland, a lobular structure with fine echogenic internal septations (Fig 1A), and numerous large intratumoral vessels (Figs 1B, 2A, and 2B). None of our patients showed an inhomogeneous pattern at sonography. In infantile HAE occurring in other locations in the head and neck, we have observed large vascular spaces, with flow evident at gray-scale imaging, but too slow to be detected at color or power Doppler sonography.

A previously published case (8) showed similar sonographic findings to those found in our patients. Huchzermeyer and colleagues, in a paper on MR imaging in parotid HAE (1), stated that sonography was not diagnostically helpful, but did not describe their technique or findings. Another article (9) failed to distinguish between HAE and vascular malformations, and therefore did not separately report the findings in HAE.

Our findings at sonography correlate well with published descriptions of histologic characteristics of HAE. HAE causes enlargement of the parotid gland, with retention of its overall shape and maintenance of the lobular pattern (3, 4). Significant extension beyond the parotid is uncommon (3), but HAE may also occur in accessory parotid tissue, which is often found anterior to the superficial lobe of the parotid gland. The identification of numerous large vessels in the mass is crucial to the radiologic diagnosis of HAE, and sonography and MR imaging are ideal for this purpose.

Non-contrast CT shows no specific features (10). There may be intense enhancement after intravenous administration of contrast agent (1, 8). CT,

however, carries an unnecessary risk of ionizing radiation, and appears to be inferior to MR imaging in this context.

On MR images (Figs 1C–D and 2C–D), HAE demonstrates characteristic prominent flow voids within a mass that is isointense to muscle on T1-weighted images and hyperintense on T2-weighted images (10). The conspicuity of the vessels may be increased by using "white blood" gradient-echo sequences (11). Contrast enhancement is uniform, apart from the flow voids. MR imaging is superior to sonography for evaluation of the deep lobe (Fig 1), but this is not important in the management of HAE.

RCS (Figs 1E and 2E–F) is very accurate in the diagnosis of head and neck hemangiomas in children (12). When red cells are labeled *ex vivo* and reinjected as a bolus, dynamic planar images can be acquired. Infantile hemangiomas, including HAE of the parotid, typically show very early uptake of red cells (Fig 2E). In this phase, activity in the lesion may be equal to or less than cardiac activity. Delayed images show a pathognomonic pattern of a well-defined region of intense uptake, similar to that seen in the heart and great vessels (12). This is distinct from the pattern seen in lymphatic malformations and benign and malignant neoplasms, which are photopenic, and nonlymphatic vascular malformations, which show a poorly defined area of uptake or enlarged vessels or both (12). Single-photon emission CT images are probably not necessary, although they do confirm the sharply circumscribed nature of the lesion (Fig 2F), which is characteristic of HAE (12). Because RCS permits whole-body imaging, it will reveal any other hemangiomas elsewhere in the body. The clinical importance of the identification of asymptomatic hemangiomas is unknown.

Certain other lesions may occur in the parotid region in infancy, and must be considered in the differential diagnosis of HAE. In particular, a large mass that was present at birth is unlikely to be HAE (13).

The large, solid component of HAE shown by sonography and MR imaging distinguishes this lesion from most vascular malformations, including cystic lymphatic malformations (cystic hygromas). Solid lymphatic malformations usually show extension beyond the parotid (3, 14), and do not contain prominent blood vessels (1, 10). In general, vascular malformations grow at about the same rate as the child, which also helps distinguish them from HAE.

Although rhabdomyosarcoma often arises in the head and neck region, it is unusual in infancy. Rhabdomyosarcoma is rarely confined to the parotid gland (15), but often arises in the infratemporal fossa and involves neighboring structures with an infiltrative growth pattern. It appears to be less vascular than HAE (16).

Congenital infantile fibrosarcoma (CIFS) may mimic HAE clinically. The sonographic findings of parotid CIFS have not been reported, but at other locations, Doppler sonography may show a highly

vascular pattern similar to HAE (13, 17). CIFS, however, is usually an inhomogeneous lesion (13, 18). Nerve sheath tumors are very rarely diagnosed in this region at this age (3).

About 4% of cases of solitary infantile myofibromatosis occur in the parotid region (3, 19, 20). Like HAE, this lesion may show rapid growth followed by involution. Infantile myofibromatosis, however, is hypovascular (16), with poorly circumscribed margins (21).

Sialoblastoma, which has several synonyms, including congenital carcinoma, is an extremely rare tumor of the salivary glands that arises during infancy (3, 22). It may be clinically indistinguishable from HAE (3). MR imaging performed in a case of recurrent sialoblastoma (22) showed inhomogeneous signal on T2-weighted images and inhomogeneous contrast enhancement. No flow voids were demonstrated in the tumor.

Conclusion

In patients with the typical clinical history, the probability of HAE is very high. Sonography using a high-frequency (10-MHz) transducer is the ideal first imaging investigation. It appears from these cases that a homogeneous, lobulated mass that replaces and enlarges the parotid, with preservation of its overall shape and numerous large intratumoral vessels, is typical of HAE. If these findings are confirmed in a larger series, sonography may prove to be the only imaging investigation required in the majority of cases. HAE appears to have a reasonably specific appearance on MR images, with prominent flow voids in a homogeneously enhancing mass. RCS permits confident diagnosis of HAE, but involves the risk of ionizing radiation, and is therefore less attractive than MR imaging, especially as it contributes little information if the diagnosis is not HAE. CT has no advantage over MR imaging in this context, and should not be used when MR imaging is available.

References

1. Huchzermeyer P, Birchall MA, Kendall B, et al. **Parotid haemangiomas in childhood: a case for MRI.** *J Laryngol Otol* 1994; 108:892-895

2. Ezekowitz RAB, Mulliken JB, Folkman J. **Interferon alfa-2a therapy for life-threatening hemangiomas of infancy.** *N Engl J Med* 1992;326:1456-1463
3. Lack EE, Upton MP. **Histopathologic review of salivary gland tumors in childhood.** *Arch Otolaryngol Head Neck Surg* 1988; 114:898-906
4. Nagao K, Matsuzaki O, Shigematsu H, et al. **Histopathologic studies of benign infantile hemangioendothelioma of the parotid gland.** *Cancer* 1980;46:2250-2256
5. Blei F, Isakoff M, Deb G. **The response of parotid hemangiomas to the use of systemic interferon alfa-2a or corticosteroids.** *Arch Otolaryngol Head Neck Surg* 1997;123:841-844
6. Robertson JS, Wiegand DA, Schaitkin BM. **Life-threatening hemangioma arising from the parotid gland.** *Otolaryngol Head Neck Surg* 1991;104:858-862
7. Takato T, Komuro Y, Yonehara Y. **Giant hemangioma of the parotid gland associated with Kasabach-Merritt syndrome: a case report.** *J Oral Maxillofac Surg* 1993;51:425-428
8. García CJ, Flores PA, Arce JD, Chuquib B, Schwartz DS. **Ultrasonography in the study of salivary gland lesions in children.** *Pediatr Radiol* 1998;28:418-425
9. Bradley M, Stewart I, King W, et al. **The role of ultrasound and 99mTc RBC scintigraphy in the diagnosis of the salivary gland haemangioma.** *Br J Oral Maxillofac Surg* 1991;29:164-166
10. George CD, Ng YY, Hall-Craggs MA, et al. **Parotid haemangioma in infants: MR imaging at 1.5 T.** *Pediatr Radiol* 1991; 21:483-485
11. Meyer JS, Hoffer FA, Barnes PD, et al. **Biological classification of soft-tissue vascular anomalies: MR correlation.** *AJR Am J Roentgenol* 1991;157:559-564
12. Barton DJ, Miller JH, Allwright SJ, et al. **Distinguishing soft-tissue hemangiomas from vascular malformations using technetium-labeled red blood cell scintigraphy.** *Plast Reconstr Surg* 1992;89:46-52
13. Boon LM, Fishman SJ, Lund DP, et al. **Congenital fibrosarcoma masquerading as congenital hemangioma: report of two cases.** *J Pediatr Surg* 1995;30:1378-1381
14. Luna MA, Batsakis JG, El-Naggar AK. **Salivary gland tumors in children.** *Ann Otol Rhinol Laryngol* 1991;100:869-871
15. Blatt J, Snyderman C, Wollman MR, et al. **Delayed resection in the management of non-orbital rhabdomyosarcoma of the head and neck in childhood.** *Med Pediatr Oncol* 1997;28:294-298
16. Dubois J, Patriquin HB, Garel L, et al. **Soft-tissue hemangiomas in infants and children: diagnosis using doppler sonography.** *AJR Am J Roentgenol* 1998;171:247-252
17. Lee MJ, Cairns RA, Munk PL, Poon PY. **Congenital-infantile fibrosarcoma: magnetic resonance imaging findings.** *Can Assoc Radiol J* 1996;47:121-125
18. Wong CH, Dietrich RB, Pais MJ, et al. **Pediatric case of the day.** *Radiographics* 1994;14:1428-1430
19. Chung EB, Enzinger FM. **Infantile myofibromatosis.** *Cancer* 1981;48:1807-1818
20. Coffin CM. **Fibroblastic-myoblastic tumors.** In: Coffin CM, Dehner LP, O'Shea PA, eds. *Pediatric Soft Tissue Tumors: a Clinical, Pathological, and Therapeutic Approach.* Baltimore: Williams and Wilkins;1997;133-178
21. Patrick LE, O'Shea P, Simoneaux SE, et al. **Fibromatoses of childhood: the spectrum of radiographic findings.** *AJR Am J Roentgenol* 1996;166:163-169
22. Som PM, Brandwein M, Silvers AR, Rothschild MA. **Sialoblastoma (embryoma): MR findings of a rare pediatric salivary gland tumor.** *AJNR Am J Neuroradiol* 1997;18:847-850