



## Discover Generics

Cost-Effective CT & MRI Contrast Agents



FRESENIUS  
KABI

WATCH VIDEO

# AJNR

## Long-Term Outcomes of Guglielmi Detachable Coil Packing for Acutely Ruptured Cerebral Aneurysms

J.V. Byrne

*AJNR Am J Neuroradiol* 1999, 20 (6) 1184

<http://www.ajnr.org/content/20/6/1184.2>

This information is current as  
of June 1, 2025.

## Long-Term Outcomes of Guglielmi Detachable Coil Packing for Acutely Ruptured Cerebral Aneurysms

The excellent series of special reports on controversies in neuroradiology included that of Bryan, Rigamonti, and Mathis on the treatment of acutely ruptured cerebral aneurysms (1). These authors deftly picked their way through the dilemmas currently facing us in selecting patients for endovascular treatment. Confining themselves to a discussion of the use of the Guglielmi detachable coil (GDC), they suggest that the efficacy of coils to pack aneurysms now has been resolved by published reports of the device's clinical performance and the approval of GDCs by the Food and Drug Administration (FDA). They attribute current uncertainties to a lack of published data regarding outcomes of GDC packing as compared to conventional neurosurgical clipping.

The authors make only the briefest reference to the uncertainty that remains concerning the long-term biological response to coils that is fundamental to the efficacy of this form of treatment. It is a remarkable fact that the FDA approved GDCs for clinical use in 1995, though very little was known about the cellular response to this implant. The published studies at the time consisted of reports of the device's use in experimental animal models (eg, in dogs, rabbits, and pigs) and a single, post-mortem report (2). The FDA presumably based their approval on the excellent safety record of platinum for other human implants. The results of subsequent studies of the cellular response to GDCs in experimental aneurysms are conflicting (3, 4), and substantial human histologic data are still lacking.

It is intuitive that the long-term safety of this type of embolization depends on the formation of stable fibrosis around the coils. We know that aneurysms treated with GDCs are liable to regrow, and that this tendency is proportional to the extent to which coils continue to be exposed to arterial blood flow. What remains unknown is how long it takes, if ever, for the coil-thrombosis complex to become completely stable. We, therefore, need studies to monitor the efficacy of endovascular therapy in order to answer the patient who asks, "Will the aneurysm ever bleed again?"

J.V. Byrne  
Department of Neuroradiology  
Radcliffe Infirmary  
Woodstock Road  
Oxford, OX2 6HE  
United Kingdom

## References

1. Bryan RN, Rigamonti D, Mathis JM. **The treatment of acutely ruptured cerebral aneurysms: endovascular therapy versus surgery.** *AJNR Am J Neuroradiol* 1997;18:1826-1830

2. Molyneux AJ, Ellison DW, Morris J, Byrne JV. **Histological findings in giant aneurysms treated with Guglielmi detachable coils: report of two cases with autopsy correlation.** *J Neurosurg* 1995; 83:129-132
3. Reul J, Weis J, Spetzger U, Konert T, Fricke C, Thron A. **Long-term angiographic and histopathologic findings in experimental aneurysm of the carotid bifurcation embolized with platinum and tungsten coils.** *AJNR Am J Neuroradiol* 1997;18:35-42
4. Byrne JV, Hope JKA, Hubbard N, Morris JH. **The nature of thrombosis induced by platinum and tungsten coils in saccular aneurysms.** *AJNR Am J Neuroradiol* 1997;18:29-33

## Reply

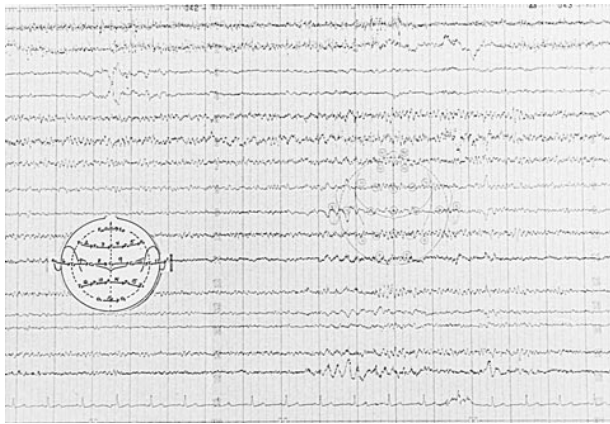Dr. Byrne's letter emphasizes a critical factor necessary for the final determination of GDC coil effectiveness for the treatment of intracranial aneurysms; that is, the long-term biological response to coil implants. Our previous commentary on the endovascular coil treatment of aneurysms addresses the persisting uncertainty of long-term outcomes of such therapy as compared with conventional surgical clipping, but Dr. Byrne more elegantly poses specific questions related to long-term outcome. The biological tolerance to the coils and their induction (direct versus indirect) of stable clot and fibrosis will indeed be determining factors in successful treatment. This critical information remains lacking, and we concur with Dr. Byrne's plea for more basic and clinical investigation of these topics.

Nick Bryan, M.D., Ph.D.  
John Mathis, M.D.  
Daniele Rigamonti, M.D.  
National Institutes of Health  
Bethesda, MD

## The Use of Hyperventilation in Contrast-Enhanced MR Imaging of Brain Tumors

Pronin et al investigated the use of hyperventilation in contrast-enhanced MR imaging of brain tumors as an inexpensive and safe method to increase sensitivity for visualizing brain tumors (1). They mentioned the importance of determining the safety of hyperventilation, which occasionally causes seizures. Although we agree with the safety of hyperventilation in general, we recently saw a rare complication of hyperventilation.

A 74-year-old right-handed man, who had a history of migraine headaches with aura for 20 years, was hospitalized. Two years previously Desyrel was prescribed for him (100 mg at bedtime). Prior to admittance, he complained of a 1-week course of intermittent right hemihypesthesia and aphasia (anomia with semantic paraphasia), culminating in intermittent episodes of right hemiparesis that lasted minutes. During hospitalization, he was treated with low-molecular-weight Heparin and his usual daily 5 grains of aspirin, and his symptoms resolved.



During his EEG, after 2 minutes of hyperventilation, he developed frontal intermittent rhythmic activity of 70  $\mu$ V 2 Hz  $\Delta$ , accompanied by right hemiparesis and aphasia. For 2 seconds, there was intermittent diffuse bilateral activity of 40  $\mu$ V 3 Hz  $\Delta$ , then an acceleration to 35  $\mu$ V 5–6 Hz  $\theta$ , which disappeared when his right hemiparesis and aphasia subsided (Fig).

A CT scan showed a 4-cm left parietal decreased density with mild mass effect flattening the wall of the lateral ventricle. On an MR scan, this area was hypointense on T1-weighted images and hyperintense on T2-weighted images, enhancing with contrast material. Biopsy of this mass showed a glioblastoma multiforme.

Ross (2) described transient tumor attacks in 1983, which was followed by a related large multicenter trial in 1993 (3) and a review of four cases by Cameron 1994 (4). One of Cameron's four cases of meningioma yielded an EEG showing "bursts of . . . activity below 8 Hz in the . . . midtemporal region . . . consistent with a slowly growing neoplasm."

Shregel et al (5) and Pronin et al (1, 6) have demonstrated that there is decreased autoregulation and CO<sub>2</sub> sensitivity or, paradoxically, increased blood flow within brain tumors with hyperventilation. If hyperventilation can lead to paradoxically increased blood flow within a tumor, but normal physiologic decreased blood flow in the normal brain around a tumor, it may lead to relatively more tumor mass effect. This would rarely result in focal neurologic signs and EEG slowing that could be reversed by stopping hyperventilation.

Rollin James Hawley, M.D.  
Jon Michael Payne, M.D.  
Linda S. Giannola, R.N.  
Radford, VA

#### Reply

We would like to thank Drs. Hawley and Payne and Ms. Giannola for their letter in which they de-

scribe a "rare complication of hyperventilation" in a patient with glioblastoma multiforme. They describe a patient who developed transient focal neurologic symptoms during hyperventilation. The mechanism of these clinical findings, however, is unclear. Notwithstanding the described focal neurologic symptoms (right hemiparesis and aphasia), the accompanying EEG showed generalized slowing. It is well known that hyperventilation is associated with intermittent focal EEG slowing in patients with mass lesion, and Hawley et al provide an interesting hypothesis as to the cause. They note that hyperventilation may unmask the clinical effects of a focal CNS lesion. They hypothesize that because hyperventilation increased the tumor blood flow, it will produce increased mass effect on the adjacent brain and cause the focal findings. We welcome further investigation into this interesting effect.

An important issue is whether hyperventilation can be performed safely in the presence of brain tumor. Hyperventilation typically precipitates absence (petit mal) seizures with a generalized spike and slow wave discharge (1). It is distinctly uncommon for hyperventilation to precipitate partial (focal) seizures, which is the seizure type associated with intracranial mass lesions (2). Because the individuals in the group we studied had focal brain lesions, it is unlikely that hyperventilation would have triggered partial seizures in this group. The findings described by Hawley were easily reversible when hyperventilation was terminated, and should not cause long-term sequelae.

Andrei I. Holodny  
Department of Radiology

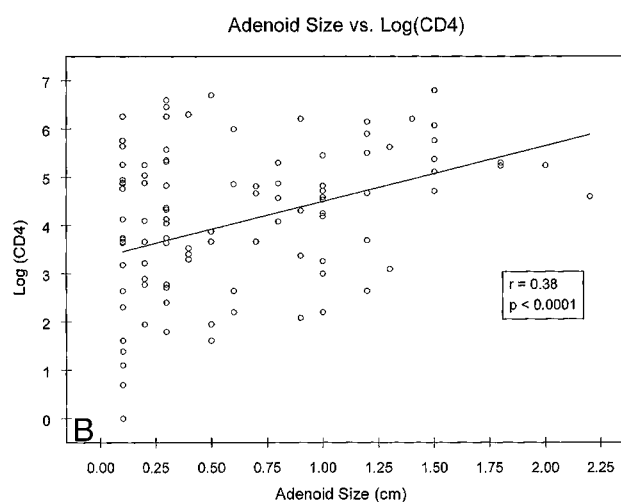
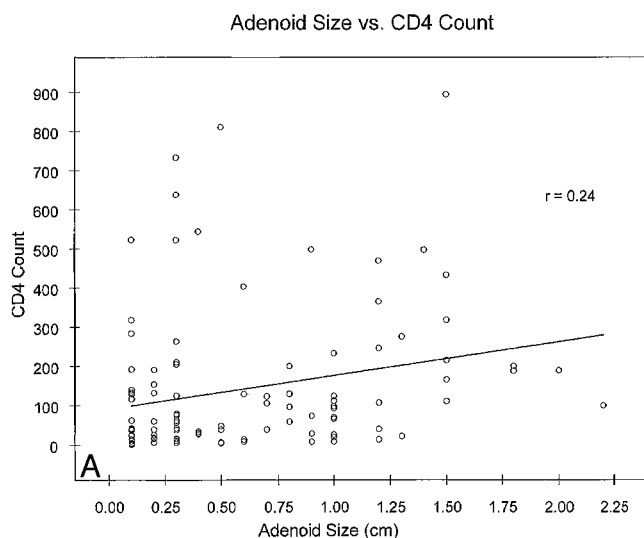
David Marks  
Department of Neurology  
UMDNJ—New Jersey Medical School  
Newark, NJ

Igor N. Pronin  
Valery N. Kornienko  
Alexei Petraikin  
Department of Radiology

AV Golanov  
Department of Neurosurgery  
Burdenko Institute of Neurosurgery  
Moscow, Russia

#### References

1. Esquivel E, Chaussain M, Plouin P, Ponsot G, Arthuis M. **Physical exercise and voluntary hyperventilation in childhood absence epilepsy.** *Electroencephalogr Clin Neurophysiol* 1991;79:127–132
2. Spencer DD, Spenser SS, Mattson RH, Williamson PD. **Intracerebral masses in patients with intractable partial epilepsy.** *Neurology* 1984;34:432–436



### Adenoid Enlargement and CD4 Counts in HIV-Positive Patients

We read with interest the article by Yousem et al in which the size of adenoids in 21 HIV-positive patients was studied as a function of other clinical parameters (1). We are interested in this topic because our experience indicates that large adenoids usually are seen in patients with relatively high CD4 counts. We, therefore, were surprised to learn that Yousem et al's study reported no significant correlation between the number of CD4 antigens and adenoid size. This was particularly surprising because their results were in apparent conflict with the findings reported by Zagdanski et al of 33 HIV-positive patients (2). Because of the differing conclusions, we studied 107 HIV-positive patients at our institution to summarize our experience, and to attempt to understand what factors may underlie the apparently disparate results of these other two studies.

Adenoid diameters were measured on sagittal T1-weighted brain MR images, and correlated with CD4 counts in the same manner described by Yousem et al (1). Correlations were recalculated after clustering the data by adenoid size (< 5 mm, 5–7 mm, 8–12 mm, and > 12 mm), similar to the approach used by Zagdanski et al. When analyzed, using Yousem's approach, our data similarly indicated no significant correlation between adenoid size and CD4 counts. When analyzed, using Zagdanski's technique, the data suggested a positive correlation between size and CD4 counts ( $r = 0.84$ ), supporting the conclusions of those authors. Thus, our data support both opposing conclusions, depending on the technique used to analyze the data. Nonetheless, important deficiencies exist in both of these techniques, which when resolved, permit a reasonable understanding of the relationship between CD4 counts and adenoid size.

Using the method employed by Zagdanski, all data are compressed into only four data points. By

compressing the 107 observations into four "pseudo observations," the inherent variability of the data set is lost, limiting the ability to assess errors or trends. Also, the selection of four groups is arbitrary and allows for artificially easy linear regression line fitting. After all, it would be impossible not to find a high correlation had only two groups been selected. Finally, there is no weighting to account for the large variation in the number of patients assigned to each group.

Although Yousem's approach importantly retains the intersubject variation inherent to the data set, inspection of the resulting regression plot indicates that, for many adenoid sizes, CD4 counts do not distribute normally about the regression line (Fig 1A). Because testing associated with standard linear regression analysis assumes a normal distribution of data, an F test (and significance testing) is inappropriate for the data set in question until a normalizing transformation is made.

To normalize the data distribution, the log of CD4 counts was plotted against adenoid size. Using this transformation, the data points distribute symmetrically about the regression lines (Fig 1B), and modest correlation is obtained that is highly significant ( $r = .38$ ;  $P < .0001$ ). Thus, the data support the notion that adenoid size correlates with CD4 counts.

Our analysis of a relatively large group of patients also helps resolve the apparent conflict between the previous studies. The study supports Yousem et al's conclusion that there is not a simple linear relationship between adenoid size and CD4 counts in HIV disease, but we have refined the viewpoint. At the same time, our data support the view of Zagdanski et al that intense adenoid "hypertrophy" tends to occur in patients with relatively high CD4 counts.

James L. Fleckenstein, MD  
Southwestern Medical School Dallas, TX



## References

1. Yousem DM, Loevner LA, Tobey JD, et al. **Adenoidal width and HIV factors.** *AJNR Am J Neuroradiol* 1997;18:1721-1725
2. Zagdanski A, Cyna-Gorse F, De kerviler E, Feger C, Molina J, Fuja J. **Correlation between nasopharyngeal pattern at CT and CD4 lymphocyte count in HIV-positive patients.** *Radiology* 1995;197(suppl):-346

## Reply

The abstract in the RSNA guide for Dr. Zagdanski's presentation actually refers to "intense hypotrophy" for the patients with the *lowest* CD4 lymphocyte counts, and the authors say the "finding is probably due to the reduction of the lymphoid tissue and may reflect the degree of immunodeficiency." Thus, Dr. Fleckenstein's demonstration that "intense hypertrophy" of the adenoidal tissue is seen in patients with higher CD4 lymphocyte counts, though supportive of a relationship between adenoidal width and CD4 counts, does not "concur" with Zagdanski et al's work on adenoidal "hypertrophy." Fleckenstein's approach is from the opposite direction; ie, when adenoids are large, not small. I believe that Dr. Fleckenstein may have been misled by the unusual term "hypotrophy," which the French authors meant to imply a reduction in adenoidal size.

I appreciate Dr. Fleckenstein's clarification on the relationship between CD4 counts and adenoidal width. It makes sense. Nonetheless, I have always been of the belief that someone with the right background can always use data in the appropriate manner to arrive at a statistically significant result. I regret that I have a limited prowess at biostatistics because a number of my "negative" studies (that could never get published) could have used the right "grouping" and sphericity analyses.

David M. Yousem, M.D.  
*Johns Hopkins University  
 Baltimore, MD*

## Clinical Perspective in Normal Pressure Hydrocephalus

In the commentary on our paper concerning shunt-responsive normal-pressure hydrocephalus (NPH) in the August issue of the *American Journal of Neuroradiology*, Dr. Bradley stressed the importance of clinical perspective in medical studies (1). We agree with his intention, but we do not accept his clinical perspective. Although it is very important to view a study from a clinical perspective, the issue is—what perspective is important for the management of NPH? In this context, his comments need to be examined closely.

Dr. Bradley advised that "anyone publishing a new sign should ensure the sign has not been previously published." He cited an article of George (2), and maintained that the finding of large Sylvian

cisterns with NPH is not a new observation but a rehash of a previously reported finding, obtained this time with a "high-tech" tool. That article is actually a commentary on a report by Dr. Bradley and colleagues, published in the same issue of the *AJNR* (3). We carefully read it. George's commentary did not contain anything about large Sylvian cisterns with NPH, but did include criticisms of the value of the CSF flow void in determining shunt-responsive NPH. In Bradley's original paper, there was no statement about large Sylvian cisterns. Although a patient with moderate NPH (illustrated in Figure 1 of their paper) has large Sylvian cisterns, this was not mentioned, and they seemed unaware of the significance of the finding. We have found no report indicating that large Sylvian cisterns are supportive of the diagnosis of NPH. This is probably because the finding is seemingly counter-intuitive, although "it is not surprising given that NPH is a form of communicating hydrocephalus" (1). In our article (4), we have stressed the significance of this finding on clinical and imaging grounds.

The diagnosis of idiopathic NPH in the elderly remains a substantial issue in the field of dementia, memory disorders, neurosurgery, and neuroradiology (5, 6). Many patients with possibly curable NPH often are misdiagnosed as having Alzheimer's disease or vascular dementia. In fact, most of our subjects were referred to us with such diagnoses, even with cranial CTs showing prominent Sylvian cisterns. Large Sylvian cisterns, with focally dilated sulci, often are misinterpreted as atrophy. Recognition of NPH in those patients is of great importance. Determination of patients likely to respond to shunts and those who will not is important, and disregarding the possibility of NPH before further diagnostic workup would be unfortunate. Dr. Bradley, citing studies with colleagues (3, 7), claimed that their finding of an increased CSF flow void reliably determines those likely to respond to shunts from those unlikely to do so. Other investigators have not replicated their view (8, 9), and the CSF flow-void sign generally has not been accepted as a good indicator of shunt responsiveness (2, 5). In our 11 subjects, the CSF flow void sign was noted in only six patients on either proton density-weighted or cardiac-gated gradient-echo images or both. A comparison between shunt responders and nonresponders is obviously important to identify predictive signs. A prospective trial in which all patients fulfilling some criteria, including those thought not to have NPH who also would undergo a shunting procedure, would be difficult to justify ethically, as perioperative mortality and risk of shunt-related complications are considerably high in the elderly. In addition, a retrospective study would suffer from the small number of patients with negative imaging sign or with negative shunt result, as Bradley discussed in his own article (7). In this circumstance, we believe that identifying MR features of idiopathic NPH in confirmed cases (ie, those who responded to shunts) is worthwhile. We specifically have selected candi-

dates for shunts, and a positive response to shunt surgery is confirmatory for NPH (6).

Dr. Bradley claimed that 5-mm images with a 2.5-mm interslice gap were not appropriate for volumetry. As he pointed out, the 3D gradient-echo thin-slice images are now applied for hippocampal volumetry. The ability to resolve spatially two adjacent areas of brain structure is a function of the inherent spatial resolution of the images, and the imaging voxels must be of a size that is appropriately matched to the object being measured. We agree with Bradley's view that bad data subjected to sophisticated processing are still bad data. In fact, we are using 3D images and processing them mainly for research purposes (Mori et al *Am J Psychiatry* 1997; Mori E et al *J Neurol Neurosurg Psychiatry* 1997; Kitagaki et al *Radiology* 1998; Hashimoto et al *Neurology* 1998; Yasuda et al *Am J Psychiatry* 1998); however, unlike small structures such as the hippocampus, high spatial resolution images are not required for volumetry of large objects such as CSF spaces, which have a high contrast difference compared to neighboring structures. We chose this imaging technique for this reason and also for the practical availability of images and processing. One must allocate enormous time and labor to processing 3D images in the absence of an automated software system.

In summary, it remains necessary to maintain broad and objective clinical perspectives when evaluating new findings.

Etsuro Mori  
Hajime Kitagaki

*Departments of Clinical Neurosciences  
and Neuroimaging Research  
Hyogo Institute for Aging Brain  
and Cognitive Disorders*

## References

1. Bradley WG Jr. **MR prediction of shunt response in NPH: CSF morphology versus physiology.** *AJNR Am J Neuroradiol* 1998;19:1285-1286
2. George AE. **Chronic communicating hydrocephalus and periventricular white matter disease: a debate with regard to cause and effect.** *AJNR Am J Neuroradiol* 1991;12:42-44
3. Bradley WG Jr, Whittemore AR, Watanabe AS, Davis SJ, Teresi LM, Homyak M. **Association of deep white matter infarction with chronic communicating hydrocephalus: implications regarding the possible origin of normal-pressure hydrocephalus.** *AJNR Am J Neuroradiol* 1991;12:31-39
4. Kitagaki H, Mori E, Ishii K, Yamaji S, Hirono N, Imamura T. **CSF spaces in idiopathic normal pressure hydrocephalus: morphology and volumetry.** *AJNR Am J Neuroradiol* 1998;19:1277-1284
5. Holodny AI, Waxman R, George AE, Rusinek H, Kalnin AJ, de Leon M. **MR differential diagnosis of normal-pressure hydrocephalus and Alzheimer disease: significance of perihippocampal features.** *AJNR Am J Neuroradiol* 1998;19:813-819
6. Vanneste JA. **Three decades of normal pressure hydrocephalus: are we wiser now?** *J Neurol Neurosurg Psychiatry* 1994;57:1021-1025
7. Bradley WG Jr, Scalzo D, Queralt J, Nitz WN, Atkinson DJ, Wong P. **Normal-pressure hydrocephalus: evaluation with cerebrospinal fluid flow measurements at MR imaging.** *Radiology* 1996;198:523-529

8. Krauss JK, Regel JP, Vach W, Jungling FD, Droste DW, Wakhloo AK. **Flow void of cerebrospinal fluid in idiopathic normal pressure hydrocephalus of the elderly: can it predict outcome after shunting?** *Neurosurgery* 1997;40:67-73
9. Hakim R, Black PM. **Correlation between lumbo-ventricular perfusion and MRI-CSF flow studies in idiopathic normal pressure hydrocephalus.** *Surg Neurol* 1998;49:14-19

## Reply

I have read Dr. Mori's letter concerning my commentary (1) on his article (2) and I wish to thank him for pointing out a mistake in a cited reference (3). Specifically, I had assumed that Dr. George's 1991 *AJNR* paper (3) contained information similar to his group's presentation (4) at the 1989 ASNR on large Sylvian cisterns in patients with NPH. Dr. Mori is correct in stating that large Sylvian cisterns are not mentioned as a feature of NPH in this article. On the other hand, the sign had been published by Dr. George 3 years earlier in a well-known textbook (5) in which he wrote, "Hydrocephalus, however, may coexist with large sulci and in particular with large Sylvian fissures. . . This occurs when the block is at the level of the high convexity or the pacchionian granulations. Consequently, the sulci and fissures dilate because of the damming of fluid proximal to the block. In effect, the sulci dilate in the same way as the ventricular system because of the distal obstruction."

Having read this chapter and heard Dr. George's presentation, I naturally assumed that he was the first to describe the sign of large Sylvian cisterns in NPH; however, he never claimed priority. When I called him to confirm the references, he pointed out that Vassilouthis first described the sign in 1984 by using CT (6). Thus, I was correct in indicating that the sign of large Sylvian cisterns in NPH had been published previously; however, I was incorrect in my specific reference.

Concerning the issue of increased CSF flow void as an indicator of shunt-responsive NPH, I wish to point out that Dr. Mori's comments do not reflect the results as stated in either of his references, specifically in references 3 or 7. His reference 3 describes the finding of deep white matter ischemic changes with NPH (8). His reference 7 points out that the aqueductal CSF stroke volume (from quantitative phase contrast CSF velocity imaging) is increased with shunt-responsive NPH (9) not the flow void in itself.

Dr. Mori points out two articles (10, 11) that challenge the hyperdynamic CSF flow-void sign in NPH. The first of these investigators (10) used a fast spin-echo technique, and found the CSF flow void to be insensitive for predicting outcome in NPH. This is not surprising and, in fact, could have been predicted from our 1996 article in which we specifically stated that the current ubiquitous use of flow compensation minimizes the degree of signal loss attributable to CSF motion in the aqueduct (9). In that paper, 50% of the patients who were found to have hyperdynamic CSF flow by quantitative

phase-contrast techniques did not have an increased flow void because the proton density-weighted images were flow-compensated. Similarly, with fast spin-echo images, the multiple 180° pulses achieve a marked degree of flow compensation, minimizing the degree of signal loss in the aqueduct and adjacent portions of the ventricular system (12). As noted (9), if flow-compensation (or fast spin-echo) techniques are used, the CSF flow void is intrinsically less marked, and if it is not seen in appropriately symptomatic patients, quantitative flow measurements should be made. The second citation (11) is an article written by two neurosurgeons. Unfortunately, they have not provided enough technical MR imaging information in their article to enable the reader to assess whether the CSF flow quantitation techniques were adequate or if the criteria for determining normal versus increased flow were appropriate.

In summary, we continue to believe firmly in the finding of hyperdynamic CSF flow as an indicator of shunt-responsive NPH—whether this is documented on proton density-weighted or conventional spin-echo images or through direct, quantitative phase-contrast CSF flow measurements. It has served us well for over 10 years of observation. Furthermore, we are grateful to Dr. Mori for making the finding of large Sylvian cisterns with NPH more accessible in the peer-reviewed radiologic literature.

William G. Bradley, Jr., M.D., Ph.D.  
*Long Beach Memorial Medical Center*  
*Long Beach, CA*

## References

1. Bradley WG. **MR prediction of shunt response in NPH: CSF morphology versus physiology.** *AJNR Am J Neuroradiol* 1998; 19:1285–1286
2. Kitagaki H, Mori E, Ishii K, et al. **CSF spaces in idiopathic normal pressure hydrocephalus: morphology and volumetry.** *AJNR Am J Neuroradiol* 1998;19:1277–1284
3. George AE. **Chronic communicating hydrocephalus and periventricular disease: a debate with regard to cause and effect.** *AJNR Am J Neuroradiol* 1991;12:42–44
4. Shier CR, George AE, DeLeon MJ, Sheer-Williams M, Scyloponlos LA, Pinto R. **CT and MR features of hydrocephalus: paradoxical sylvian fissure enlargement and significance of the hippocampal luency.** Presented at 27<sup>th</sup> Annual Meeting of American Society of Neuroradiology, March 18–24, 1989, Orlando, Florida
5. George AE, DeLeon MJ. **Hydrocephalus, cerebral atrophy, and related disorders.** In: Haaga JR, Alfidi RJ, eds. *Computed Tomography of the Whole Body*, Chapter 10. St. Louis, Mo: CV Mosby & Co; 1988:326
6. Vassilouthis J. **The syndrome of normal-pressure hydrocephalus.** *J Neurosurg* 1984;61(3):501–509
7. Bradley WG, Whittemore AR, Kortman KE, Homyak M, Teresi LM, David SJ. **Marked CSF flow void: an indicator of successful shunting in patients with suspected normal pressure hydrocephalus.** *Radiology* 1991;178:459–466
8. Bradley WG, Whittemore AR, Watanabe AS, Davis SJ, Teresi LM, Homyak M. **Association of deep white matter infarction with chronic communicating hydrocephalus: implications regarding the possible origin of normal-pressure hydrocephalus.** *AJNR Am J Neuroradiol* 1991;12:31–39
9. Bradley WG, Scalzo D, Queralt J, Nitz WN, Atkinson DJ, Wong P. **Normal-pressure hydrocephalus: evaluation with cerebrospinal fluid flow measurements at MR imaging.** *Radiology* 1996;198:523–529
10. Krause JK, Regel JP, Vach W, Jungling FD, Droats DW, Wakhloo AK. **Flow void of cerebrospinal fluid in idiopathic normal pressure hydrocephalus of the elderly: can it predict outcome after shunting.** *Neurosurgery* 1997;40:67–73
11. Hakim R, Black PM. **Correlation between lumbo-ventricular perfusion and MRI-CSF flow studies in idiopathic normal pressure hydrocephalus.** *Surg Neurol* 1998;49:14–19
12. Bradley WG, Chen D-Y, Atkinson CJ. **Fast spin echo.** In: Bradley WG, Bydder GM, eds. *Advanced MR Imaging Technology*, Chapter 1. London: Martin Dunitz; 1997



### Safety of Angioplasty for Intracranial Artery

We read with interest the article "Intracranial Angioplasty: Experience and Complication" by Takis et al (1) in the October 1997 issue of the *American Journal of Neuroradiology*. The authors performed angioplasty in intracranial arteries in 10 patients with TIA or minor stroke and reported a relatively high rate of intraprocedural complications, including vasospasm (63%), dissection (25%), and compromise of perforating vessels (25%). We speculate that perhaps technical differences in their procedures may have contributed to their unfavorable results. In our previous study of angioplasty for the basilar artery (2), we suggested less invasive techniques, such as lowering inflation pressure ( $<3$  atm), dilating fewer times (once or twice), and using a smaller balloon catheter (2.0 mm). It is also important to inflate the balloon catheter slowly. These techniques could minimize the intimal damage and prevent occlusion of the perforating artery and excessive dissection. In addition, significant hemodynamic disturbance is reported to occur only with more than 70% stenosis; further dilatation of less than 50% stenosis may not always be necessary to achieve adequate cerebral blood flow. The purpose of angioplasty should be to provide sufficient perfusion to reduce ischemic symptoms, not to achieve an angiographic cure, which is often associated with an unacceptable complication rate. Nevertheless, the restenosis rate of our techniques is to be determined by a larger number of patients and long-term follow-up data. In our limited experience with 25 cases that have been followed up more than one year, the restenosis rate has been less than 10% (two cases). This is relatively low when compared with the reported data regarding angioplasty for the intracranial artery (30% [3]) and angioplasty for the coronary artery. Most important, our complication rate, based on our 30 cases, is much lower (6%, unpublished data) than that reported by Takis et al.

In general, mechanical vasospasm is temporary and responsive to vasodilators, as suggested by the authors. Persistent vasospasm is mostly related to arterial dissection, particularly the dissection of small vessels, such as intracranial arteries, and may not always be apparent on cerebral angiograms. Because silent dissection does not commonly cause stroke, systemic heparinization administered for 3 days after angioplasty is the preferred treatment of patients with potential arterial dissection in our institution.

Toshihiro Ueda, MD, PhD  
William T. C. Yuh, MD  
Division of Neuroradiology and MRI Center  
Department of Radiology  
The University of Iowa College of Medicine  
Iowa City, IA

### References

1. Takis C, Kwan E, Pessin M, Jacobs D, Caplan L. **Intracranial angioplasty: experience and complication.** *AJNR Am J Neuroradiol* 1997;18:1661-1668
2. Nakatsuka H, Ueda T, Ohta S, Sakaki S. **Successful percutaneous transluminal angioplasty for basilar artery stenosis: technical case report.** *Neurosurgery* 1996;39:161-164
3. Mori T, Mori K, Fukuoka M, et al. **Percutaneous transluminal angioplasty for total occlusion of middle cerebral arteries.** *Neuroradiology* 1997;39:111-116

### Reply

We appreciate the interest of Drs Ueda and Yuh in our article *Intracranial Angioplasty: Experience and Complication*. We agree that submaximal percutaneous transluminal angioplasty (PTA) of intracranial arteries with balloons inflated slowly and at low pressure is probably a safer technique, because it is less traumatic to the intima and media of treated arteries. Nevertheless, only careful long-term follow-up in a larger series of patients can determine the efficacy and restenosis rate with this approach.

Eddie Kwan, MD  
New England Medical Center  
Boston, MA

### Direct Angioplasty for Acute Occlusion of Intracranial Artery

We have read with interest the article *Direct Percutaneous Transluminal Angioplasty for Acute Middle Cerebral Artery Occlusion* by Nakano and colleagues (1). The authors report their experience using direct percutaneous angioplasty (PTA) as the sole means of treating 10 patients with acute middle cerebral artery (MCA) occlusion when the initial CT scans demonstrate early ischemic changes or involvement of lenticulostriate arteries or both. The authors' rationale for choosing direct PTA alone to establish blood flow without using thrombolysis is based on the high risk of hemorrhagic complications in this group of patients. The authors believe that avoiding thrombolytic therapy can reduce such a risk. The angiographic success rate in their patients was relatively high (80%), and there were no hemorrhagic complications; however, only two patients had full recovery. With 20% clinical recovery and 20% distal embolization, the rationale for their method becomes debatable despite a high rate of angiographic success without hemorrhagic complications.

We wonder whether the authors may have overlooked the fundamental pathophysiology that causes hemorrhagic complications during acute ischemic stroke. Patients with early ischemic findings on initial CT scans have a high risk of hemorrhage after re-established blood flow primarily because of the high incidence of reperfusion of irreversibly damaged ischemic tissue. The thrombolytic agent



can contribute to but is not the primary cause of hemorrhagic complications (ie, reperfusion of dead tissue). The most effective way to prevent such complications is either to avoid reperfusion of irreversibly damaged tissue or to recanalize the occluded vessel as early as possible. In some patients, the blood flow of the cortex in the distal MCA territory can be rescued by recanalization of the occluded M1 segment by using direct angioplasty. Angioplasty alone, however, will not dissolve the clot nor re-establish the blood flow effectively, particularly in the perforators, but will further propagate the clot distally. Therefore, the relatively low rates of hemorrhage and clinical recovery suggest that their technique of performing angioplasty alone may not be as effective in re-establishing the blood flow. If the authors believe that early ischemic findings on the initial CT scan suggest irreversibly damaged tissue and a high risk of hemorrhage, then early interventional treatment, including PTA, should not be performed in patients who have such findings.

One important question in the treatment of acute stroke is whether we are treating reversible ischemia. Our previous reports suggest that reversibility of ischemic tissue can be assessed by single-photon-emission CT of pretreatment CBF, which can help in the selection of appropriate patients for thrombolysis by reducing hemorrhagic complications and improving outcome (2, 3). Our previous experience also suggests that a combination of thrombolysis and angioplasty is effective in failed thrombolysis cases or reocclusion cases (4). We strongly believe that angioplasty is an effective option in reperfusion therapy for acute ischemic stroke and can shorten the duration of ischemia and improve the success rate of recanalization. Most importantly, the purpose of angioplasty should be to improve the neurologic systems of stroke patients by increasing CBF, not to improve angiographic results.

Toshihiro Ueda, M.D., Ph.D.

William T.C. Yuh, M.D.

*Division of Neuroradiology and MRI Center*

*Department of Radiology*

*The University of Iowa College of Medicine*

## References

1. Nakano S, Yokogami K, Ohta H, Yano T, Ohnishi T. **Direct percutaneous transluminal angioplasty for acute middle cerebral artery occlusion.** *AJNR Am J Neuroradiol* 1998;19:767-772
2. Ueda T, Hatakeyama T, Kumon Y, Sakaki S, Uraoka T. **Evaluation of risk of hemorrhagic transformation in local intra-arterial thrombolysis in acute ischemic stroke by initial SPECT.** *Stroke* 1994;25:298-303
3. Ueda T, Sakaki S, Yuh W, Nochide I, Ohta S. **Outcome in acute stroke with successful intra-arterial thrombolysis and predictive value of initial SPECT.** *J Cereb Blood Flow Metab* 1998;(in press)
4. Ueda T, Hatakeyama T, Kohno K, Kumon Y, Sakaki S. **Endovascular treatment for acute thrombotic stroke of the middle cerebral artery: local intra-arterial thrombolysis combined with**

**percutaneous transluminal angioplasty.** *Neuroradiology* 1997;39:99-104

## Reply

We appreciate the interest of Ueda and Yuh in our report about direct percutaneous transluminal angioplasty (PTA) for acute middle cerebral artery (MCA) occlusion. To our regret, however, they misinterpreted our thesis and results. We reported that four (57%) of seven patients with embolic MCA trunk occlusion showed marked clinical improvement. All patients had early ischemic findings on the initial CT scan, however, and lenticulostriate artery (LSA) involvement, both of which have been reported to be predictive signs of hemorrhagic complications after thrombolytic therapy (1, 2). This good result indicates that early ischemic findings on the initial CT don't always suggest irreversibly damaged tissue.

In patients with these findings, urgent recanalization should be undertaken prior to the onset of irreversible brain damage. In patients with embolic MCA trunk occlusion, the embolus is often so large that it is resistant to thrombolysis and mechanical crushing of the embolus by direct PTA is preferred to time-consuming thrombolytic therapy. Our rationale for choosing direct PTA for these patients is based on the high risk of hemorrhagic complication when time-consuming high-dose thrombolytic therapy is performed. We chose direct PTA in order to achieve rapid recanalization, not to avoid using thrombolytic agents. We agree with Ueda and Yuh that angioplasty is an effective option in reperfusion therapy for acute ischemic stroke and it can achieve rapid recanalization (3).

In patients with embolic MCA trunk occlusion, conservative treatment often leads to extended space-occupying cerebral edema or massive intracerebral hemorrhage owing to late spontaneous recanalization after complete damage of the vessel wall (4). Even if most of the ischemic tissue cannot escape cerebral infarction, therapeutic recanalization might be effective if recanalization could be performed without hemorrhagic complications and the goal of rehabilitation could be improved. The purpose of recanalization therapy should be to improve clinical outcome, not solely to achieve an excellent full recovery. We have never aimed to improve angiographic results. We do aim to improve clinical outcome.

In our study, three (43%) of seven patients with embolic MCA occlusion had cerebral infarctions in spite of rapid recanalization, suggesting irreversible ischemic damage. In these three patients, however, neither space-occupying cerebral edema nor massive intracerebral hemorrhage was found in the course of treatment because of the rapid recanalization prior to the damage of the vessel wall. Rehabilitation of these three patients went well and we believe that their clinical outcome was improved by the urgent recanalization therapy.

We have also demonstrated that direct PTA alone could achieve complete recanalization in five (71%) of seven patients with embolic MCA occlusion. Crushed fragments of the embolus migrate distally and often lyse spontaneously, resulting in complete recanalization without thrombolysis. In the other two patients, additional thrombolysis was required because of the distal embolization. Although distal embolization by crushed fragments is a noteworthy problem of direct PTA for cerebral embolism, thrombolysis of these fragments is likely to be easy with small amounts of thrombolytic agents. We agree with Ueda and Yuh that a combination of angioplasty and thrombolysis is effective in some patients. In order to recanalize the occluded vessel as early as possible, direct PTA and subsequent thrombolysis of crushed thrombi should be effective.

Angioplasty is effective in patients with atherothrombotic stroke, particularly in failed thrombolysis or reocclusion cases; however, in patients with atherothrombotic MCA branch occlusion, sufficient arterial patency was not achieved with the minimum dilatation force of 2 to 3 atm because of the small diameter of the vessel.

In summary, angioplasty is an effective option in reperfusion therapy for acute MCA occlusion, particularly in patients with atherothrombotic stroke. Even in patients with embolic MCA occlusion, when early ischemic findings and LSA involvement is present, urgent recanalization by direct PTA should be performed and additional thrombolysis may be required in some patients.

Shinichi Nakano  
Department of Neurosurgery  
Junwakai Memorial Hospital  
Miyazaki, Japan

## References

1. Yokogami K, Nakano S, Ohta H, Goya T, Wakisaka S. **Prediction of hemorrhagic complications after thrombolytic therapy for middle cerebral artery occlusion: value of pre- and post-therapeutic computed tomographic findings and angiographic occlusive site.** *Neurosurgery* 1996;39:1102-1107
2. Larue V, von Kummer R, del Zoppo G, Bluhmki E. **Hemorrhagic transformation in acute ischemic stroke. Potential contributing factors in the European Cooperative Acute Stroke Study.** *Stroke* 1997;28:957-960
3. Nakano S, Yokogami K, Ohta H, Goya T, Wakisaka S. **Direct percutaneous transluminal angioplasty for acute embolic middle cerebral artery occlusion: report of two cases.** *Angiology* 1997;6:254-256
4. von Kummer R, Meyding LU, Forsting M, et al. **Sensitivity and prognostic value of early CT in occlusion of the middle cerebral artery trunk.** *AJNR Am J Neuroradiol* 1994;15:9-15

## In Re: Reversible Ischemia Determined by Xenon-Enhanced CT after 90 Minutes of Complete Basilar Artery Occlusion

In their case report, *Reversible ischemia determined by xenon-enhanced CT after 90 minutes of*

*complete basilar artery occlusion*, Levy et al describe a patient with acute basilar artery occlusion whose right occipital lobe remained viable after reperfusion, despite 90 minutes with blood flow to this region reduced to 6 mL /100 g per minute (1). This finding—the rationale for their report—suggests a lower threshold for reversible ischemia at 90 minutes (at least in the posterior circulation) than the 10–12 mL /100 g per minute that is generally accepted.

The basis for their diagnosis of reversible ischemia, however, is the finding of resolution of hypodensity in the medial right occipital lobe on a CT scan done 12 days after stroke, as compared with a scan obtained 2 days after stroke. The authors do not provide a late CT scan (2 to 3 months after ictus), an MR scan, or an autopsy report that documents that cavitation has not subsequently evolved. Such documentation is necessary to prove that the normal attenuation coefficients found at 12 days were because of preservation of normal tissue rather than the result of a more likely phenomenon—fogging of an evolving infarction (2–4).

Infarct fogging, the apparent normalization of the CT scan hypodensity associated with an acute stroke, typically occurs between the second and third weeks after infarction. It is believed to be caused by the capillary proliferation and macrophage invasion into infarcted brain parenchyma that occurs after the resolution of acute edema but before the development of tissue cavitation.

Michael H Lev, MD  
Director of Emergency Neuroradiology  
Department of Radiology  
Massachusetts General Hospital

Robert H Ackerman, MD  
Director of the Neurovascular Laboratory  
Departments of Radiology and Neurology  
Massachusetts General Hospital

## References

1. Levy EI, Scarrow AM, Kanal E, Rubin, G, Yonas H, Kirby L. **Reversible ischemia determined by xenon-enhanced CT after 90 minutes of complete basilar artery occlusion.** *AJNR Am J Neuroradiol* 1998;19:1943-1946
2. Skriver EB, Olsen TS. **Transient disappearance of cerebral infarcts on CT scan, the so-called fogging effect.** *Neuroradiology* 1981;22:61-65
3. Becker H, Desch H, Hacker H, Pencz A. **CT fogging effect with ischemic cerebral infarcts.** *Neuroradiology* 1979;18:185-192
4. Ackerman RH, Lev MH, Alpert NM, et al. **Infarct fogging on CT: prevalence, features, and PET/MRI correlates.** In: Proceedings of the 28th Annual Meeting of the American Society of Neuroradiology; 1990; Los Angeles, CA

## Reply

In regard to the comment by Lev and Ackerman concerning our article, *Reversible Ischemia Determined by Xenon-Enhanced CT After 90 Minutes of Complete Basilar Artery Occlusion*, we agree that

the fogging effect may have initially introduced error into our ability to define infarction. Nonetheless, subsequent studies not cited in this article demonstrated retained tissue volume. Additionally, it must be noted that hemorrhage transformation of infarcted tissue occurred only on the left, where the PCA territory remained occluded despite attempted thrombolysis. The fact that hemorrhagic transformation was absent on the right, with Xe/CT and angiographic evidence of normal parenchymal blood flow, leads us to believe that this tissue was viable with intact perfusion regulatory mechanisms.

It should be clarified that the region with flow values less than 6 cc/100 g/min were primarily within the deep white matter of the occipital lobe. These therefore did not represent the more traditional mixed cortical flow values for the threshold of infarction that are more commonly referred to in the physiologic literature.

Howard Yonas, M.D.

Peter J. Jannetta, M.D.

Elad Levy, M.D.

*Department of Neurological Surgery  
University of Pittsburgh  
School of Medicine*

### Pathogenesis of Syringomyelia

I read with great interest the article, *The Presyrinx State: A Reversible Myelopathic Condition that May Precede Syringomyelia*, by Nancy J. Fischbein et al (1). Although their theory of pathogenesis for the formation of the presyrinx state and syringomyelia is provocative, several areas need further clarification. The authors propose, as have others, that increased pressure in the subarachnoid space of the spinal canal in patients with Chiari malformation or other causes of relative blockage of CSF flow at the foramen magnum would cause the CSF to flow along the perivascular spaces and accumulate either in the central canal, causing syringomyelia, or in the cord substance itself, causing a "presyrinx" state. Nonetheless, as has been pointed out by others, increased pressure applied to a fluid (CSF) surrounding a distensible semisolid structure (the spinal cord) would have a tendency to compress that structure rather than force fluid into it (2). The only way there can be net flow of fluid into the spinal cord from the CSF surrounding it is if there is a pressure differential from the subarachnoid space to the central canal or to the spinal cord substance.

The authors state it has been proved that CSF flows from the subarachnoid space into the perivascular spaces of the spinal cord and from there along the interstitial spaces toward the central canal. For support of this, the authors reference Stoodley et al, among others (3). To summarize the experiment of Stoodley et al briefly, they injected

horseradish peroxidase into the subarachnoid space of sheep and, by reducing arterial pulsations by ligating the brachiocephalic trunk, they demonstrated a reduction in the distribution of the horseradish peroxidase tracer through the perivascular spaces and central canal. They felt this experiment supported the hypothesis of arterial-driven flow of fluid from the subarachnoid space into the perivascular spaces across the interstitial space and into the central canal. In my opinion, however, this does not prove that there is bulk flow of fluid in that direction. It only proves that the cerebrospinal fluid is anatomically continuous with the central canal through a series of perivascular and interstitial spaces (4) and that when you impart energy (arterial pulsations) to a solid (horseradish peroxidase tracer) in solution (CSF) that solid will be distributed more rapidly and over a greater volume than if no energy is imparted to the mixture.

Liquids flow along the path of least resistance and from regions of high pressure to regions of low pressure. In order for there to be a net flow of fluid from the subarachnoid space through the very small (high resistance) perivascular and interstitial spaces into the very small (high resistance) central canal of the cord, and then possibly out the central canal at the level of the obex, there must be a significant pressure differential between the cerebrospinal fluid surrounding the spinal cord and the pressure in the central canal. Or, the resistance to flow from the subarachnoid space surrounding the spinal cord to the cisterna magna or basilar subarachnoid space must be greater than the combined resistances of the perivascular spaces, interstitial spaces, and central canal. This seems unlikely.

As we have previously proposed, we believe that the spinal cord is a net producer of extracellular fluid (5), and that this fluid normally flows along the perivascular spaces either into the subarachnoid space or possibly even into the central canal and is ultimately absorbed at the arachnoid villi with the rest of the CSF (6). We feel that increased resistance to flow at the foramen magnum by either Chiari I malformations or other causes prevents this extracellular fluid from exiting, and it accumulates in the spinal cord. This explanation appears more reasonable to us than the hypothesis that cerebrospinal fluid is somehow forced from the subarachnoid space through channels of very high resistance into the spinal cord and accumulates there.

William C. Olivero, M.D.

*Associate Professor of  
Neurological Surgery and Pediatrics  
University of Illinois  
College of Medicine at Peoria*

### References

1. Fischbein NJ, Dillon WP, Cobbs C, Weinstein PR. The "presyrinx" state: a reversible myelopathic condition that may precede syringomyelia. *AJNR Am J Neuroradiol* 1999;20:7-20

2. Cahan LD, Bentson JR. **Considerations in the diagnosis and treatment of syringomyelia and the Chiari malformation.** *J Neurosurg* 1982;57:24–31
3. Stoodley MA, Brown SA, Brown CJ, Jones NR. **Arterial pulsation-dependent perivascular cerebrospinal fluid flow into the central canal in the sheep spinal cord.** *J Neurosurg* 1997;86:686–693
4. Milhorat TH, Nakamura S, Heger IM, Nobanegani F, Murray S. **Ultrastructural evidence of sink function of central canal of spinal cord as demonstration by clearance of horseradish peroxidase.** *Procedure, Electronic Microscope Society, America* 1992;50:700–701
5. Sato O, Asai T, Amano Y, Hara M, Tsugane R, Yagi M. **Extra-ventricular origin of the cerebrospinal fluid: formation rate quantitatively measured in the spinal subarachnoid space of dogs.** *J Neurosurg* 1972;36:267–282
6. Olivero WC, Dinh Z. **Chiari I malformation with traumatic syringomyelia and spontaneous resolution: case report and literature review.** *Neurosurgery* 1992;30:758–760

### Reply

We appreciate Dr. Olivero's letter and his interest in our article. In their paper (1), Drs. Olivero and Dinh describe a patient with post-traumatic acquired Chiari I malformation and syringomyelia that spontaneously resolved without intervention. They review multiple theories of the pathogenesis of syringomyelia and hypothesize that head trauma in this 28-year-old woman resulted in elevated intracranial pressure and secondary tonsillar herniation that then led to obstruction of CSF flow at the level of the foramen magnum. They hypothesize that this resulted in elevated pressure in the spinal subarachnoid space, preventing egress of fluid normally produced in the spinal cord and resulting in syrinx formation. When the elevated intracranial pressure resolved, normal CSF flow across the foramen magnum was reestablished, and the syrinx resolved.

We appreciate Dr. Olivero's emphasizing that the source of CSF within hydromyelic cavities associated with the Chiari I malformation is controversial and by no means firmly established. He reviews the evidence that, in the context of a Chiari I malformation and accentuation of systolic pressure waves within the spinal subarachnoid space, CSF may not be driven into the spinal cord parenchyma along the perivascular spaces. Rather, the CSF produced within the cord substance may be prevented from exiting because of elevated pressure in the spinal

subarachnoid space. We failed to mention this theory in our report (2). Nonetheless, if true, this theory regarding the directionality of CSF flow is not inconsistent with our hypothesis that a presyrinx state may depend upon the patency of the central canal and, more importantly, is associated with CSF obstruction which, if relieved, may reverse the condition.

Nancy J. Fischbein, M.D.  
William P. Dillon, M.D.

Department of Radiology  
University of California, San Francisco  
San Francisco, CA

### References

1. Olivero WC, Dinh DH. **Chiari I malformation with traumatic syringomyelia and spontaneous resolution: case report and literature review.** *Neurosurgery* 1992;30:758–760
2. Fischbein NJ, Dillon WP, Cobbs C, Weinstein PR. **The "presyrinx" state: a reversible myelopathic condition that may precede syringomyelia.** *AJNR Am J Neuroradiol* 1999;20:7–20

### Erratum:

The correct references for the letter to the editor—Hawley RJ, Payne JM, Giannola LS. **The Use of Hyperventilation in Contrast-Enhanced MR Imaging of Brain Tumors.** *AJNR Am J Neuroradiol* 1999;20:1184–1185—are:

1. Pronin IN, Holodny AI, Kornienko VA, Petraiikin AV, Golovanov AV, Lee HJ. **The use of hyperventilation in contrast-enhanced MR of brain tumors.** *AJNR Am J Neuroradiol* 1997;18:1705–1708
2. Ross RT. **Transient tumor attacks.** *Arch Neurol* 1983;40:633–636
3. UK TIA Study Group. **Intracranial tumors that mimic transient cerebral ischemia: lessons from a large multicentre trial.** *J Neurol Neurosurg Psychiatry* 1993;56:563–566
4. Cameron EW. **Transient ischemic attacks due to meningioma: report of 4 cases.** *Clin Radio* 1994;49:416–418.
5. Schregel W, Geissler C, Winking M, Schaefermeyer H, Cunitz G. **Transcranial Doppler monitoring during induction of anesthesia: effects of propofol, thiopental, and hyperventilation in patients with large malignant brain tumors.** *J Neurosurg* 1993;5:86–93
6. Pronin IN, Kornienko VN, Petraiikin AV, Golanov AV. **The use of hyperventilation for improving the visualization of glial tumors of the brain in magnetic resonance tomography using the contrast substance Gd-DTPA.** *Zh Vopr Neirokhir Im N Burdenko* 1995;3:10–13