



Discover Generics

Cost-Effective CT & MRI Contrast Agents



WATCH VIDEO

AJNR

Simultaneous Subarachnoid Hemorrhage and Carotid Cavernous Fistula after Rupture of a Paraclinoid Aneurysm during Balloon-Assisted Coil Embolization

Constantine C. Phatouros, Van V. Halbach, Adel M. Malek, Christopher F. Dowd and Randall T. Higashida

This information is current as of June 7, 2025.

AJNR Am J Neuroradiol 1999, 20 (6) 1100-1102
<http://www.ajnr.org/content/20/6/1100>

Case Report

Simultaneous Subarachnoid Hemorrhage and Carotid Cavernous Fistula after Rupture of a Paraclinoid Aneurysm during Balloon-Assisted Coil Embolization

Constantine C. Phatouros, Van V. Halbach, Adel M. Malek, Christopher F. Dowd, and Randall T. Higashida

Summary: We describe an iatrogenic perforation of a paraclinoid aneurysm during balloon-assisted coil embolization that resulted in simultaneous subarachnoid contrast extravasation and a carotid cavernous fistula. The causative factors specifically related to the balloon-assisted method that led to aneurysm rupture are discussed as well as strategies for dealing with this complication.

The neck remodeling or balloon-assisted embolization technique originally described by Moret et al (1) can be used in the endovascular treatment of wide-necked aneurysms or in aneurysms with an unfavorable neck-to-fundus ratio in which a standard embolization technique may be unsuccessful. The inflated balloon prevents coil herniation into the parent artery and allows for denser coil packing at the aneurysmal neck. Potential complications associated with this technique, such as rupture of the parent artery or aneurysmal sac from balloon expansion, vasospasm, thromboembolism, and perforator occlusion, have been described previously (2). Additional technical considerations not present when using a standard endovascular approach that can predispose the patient to iatrogenic rupture may not be as apparent. We describe some of the supplementary technical aspects relevant to the balloon-assisted method that the endovascular therapist should be aware of in order to avoid iatrogenic perforation, and discuss a management approach in the event this complication occurs.

Case Report

A 68-year-old left-handed woman presented with a left hemiparesis and dysphasia secondary to a right posterior frontal and temporal lobe hematoma. She was found to have an underlying small arteriovenous malformation (AVM) in the right angular gyrus region with an associated unruptured me-

dially projecting aneurysm arising from the ophthalmic segment of the ipsilateral internal carotid artery (ICA) (Fig 1A and B). Initially, a conventional endovascular approach under general anaesthesia and full systemic heparinization was used but was unsuccessful because of an unfavorable neck-to-fundus ratio, which resulted in persistent coil loop herniation into the parent artery. A balloon-assisted or neck remodeling technique was then employed.

A Rapid Transit microcatheter (Cordis, Miami Lakes, FL) and Solstice balloon catheter (Micro Interventional Systems, Sunnyvale, CA) primed with a 0.010-inch guidewire were used through a 7F guide catheter. With the tip of the microcatheter within the aneurysm and the balloon inflated, a 0.018-inch soft Guglielmi detachable coil (GDC, Target Therapeutics, Fremont, CA) measuring 5 mm × 8 cm was advanced into the aneurysm. Following reformation of three loops within the aneurysm, a fluoroscopically obvious herniation of the next loop through the aneurysmal dome was immediately recognized. Thus, with the balloon still inflated, anticoagulation was immediately reversed. This coil was not withdrawn but rather advanced with the balloon inflated in an attempt to position the remainder of it within the aneurysmal sac. The coil loops, however, preferentially entered the subarachnoid space, necessitating brief deflation of the balloon while the catheter tip was repositioned. The remaining coil was then satisfactorily positioned within the aneurysmal sac and detached (Fig 1C). After detachment, the balloon was briefly deflated to allow for an angiographic run, which depicted subarachnoid contrast extravasation and, in addition, unexpected retrograde opacification of the right superior ophthalmic vein, indicating a simultaneous direct carotid cavernous fistula (Fig 1D and E).

The balloon was immediately reinflated, and a GDC-10 soft coil measuring 3 mm × 4 cm was quickly deployed and detached. A subsequent contrast injection performed on a blank roadmap showed persisting contrast extravasation into both spaces and hence a third coil, a soft GDC-10 measuring 3 mm × 4 cm, was positioned and detached within the aneurysm (with the aid of the balloon), finally resulting in hemostasis and satisfactory packing of the aneurysmal sac (Fig 1F).

The time from perforation to hemostasis was approximately 14 minutes, and the balloon was inflated for a total of 12 minutes, with the longest uninterrupted period of inflation being 6 minutes. The patient's vital signs remained stable aside from an approximately 30 mm Hg rise in systolic blood pressure; however, as there was no attendant angiographic evidence of raised intracranial pressure, an emergency ventricular drain was not inserted. An immediate postprocedural CT scan showed increased attenuation throughout the basal cisterns, consistent with extravasated blood and contrast medium; however, this cleared 24 hours later. The patient recovered from anesthesia without neurologic deficit and subsequently underwent surgical removal of the AVM approximately 1 month later.

Discussion

Inflation of a balloon with the microcatheter tip within the aneurysmal sac not only results in an

Received August 14, 1998; accepted after revision November 6.

Presented at the 11th Interventional Neuroradiology Peer Review Conference, Jackson Hole, WY, July 1998.

From the Neurovascular Medical Group, University of California at San Francisco Medical Center, 505 Parnassus Ave, Room L-352, San Francisco, CA 94143.

Address reprint requests to Constantine C. Phatouros MBBS, FRACR

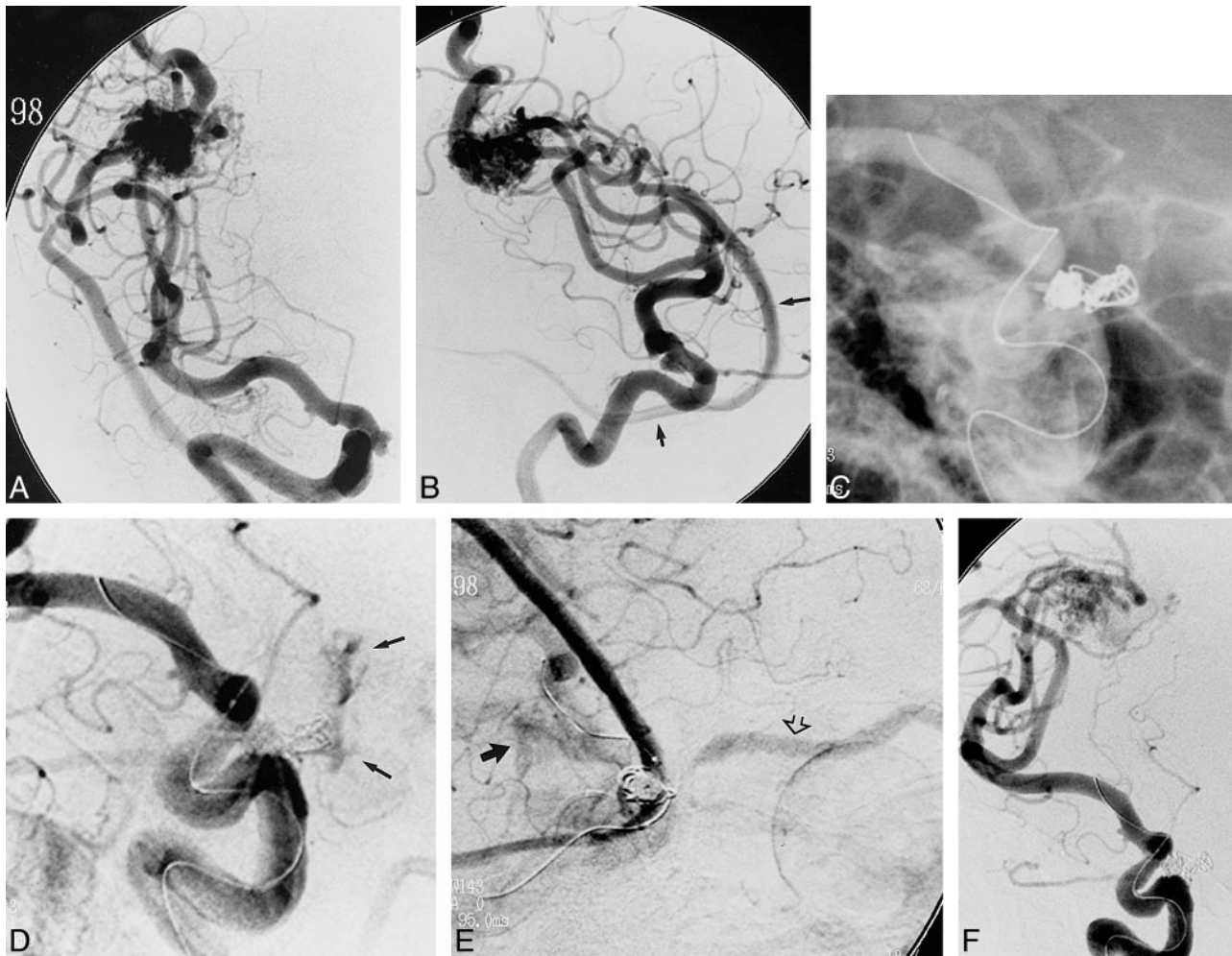


FIG 1. 68-year-old woman with left hemiparesis and dysphasia secondary to a right posterior frontal and temporal lobe hematoma.

A and B, Towne (A) and lateral (B) projections show the right ICA ophthalmic segment aneurysm and AVM. The bilobate aneurysm projects inferomedially and posteriorly. Note the anteriorly draining sylvian vein connecting to the vein of Labbe (arrows, B).

C, Unsubtracted magnified left anterior oblique projection after detachment of the first coil shows coil loops herniating through the aneurysmal fundus.

D, Left anterior oblique projection shows subarachnoid contrast extravasation from the perforated aneurysm (arrows).

E, Lateral oblique projection shows concurrent subarachnoid contrast extravasation (solid arrow) and opacification of the superior ophthalmic vein (open arrow). Note the AVM venous drainage that was previously present.

F, Left anterior oblique projection shows the final angiographic result after packing with three coils.

obvious physical barrier at the aneurysmal neck but may also displace the microcatheter peripherally toward the perimeter of the aneurysm ("perimeterization"), which may in turn alter the spatial orientation of the catheter tip. The microcatheter tip should therefore be carefully observed during inflation of the balloon and an understanding of its final position sought. In addition, the catheter may be pinned between the inflated balloon and the aneurysmal neck, thereby restricting its mobility and hindering the often observed to-and-fro ("painting") motion of the tip. The deleterious consequence of this is a loss of tip safety recoil, which can potentially result in increased coil tension against the aneurysmal fundus and hence predispose to perforation. This is particularly relevant when treating small aneurysms, especially in combination with stiffer or oversized coils and stiffer microcatheters (particularly a braided catheter tip).

In our case, all these factors pertained. The dome of a relatively small aneurysm was perforated using an oversized 0.018-inch series coil delivered through a relatively stiff microcatheter. The coil was, however, soft, with a stiffness closely approximating that of a 0.010-inch-diameter series coil (personal communication, Michael Wallis, Target Therapeutics).

The measures for reducing the risk of perforating an aneurysm when using the balloon-assisted method can be inferred from the above discussion. The position of the catheter tip is important, as catheter tip freedom and safety recoil may be restricted by the inflated balloon. In this respect, it is prudent, particularly in small aneurysms, to advance the tip, if possible, no farther than one third of the way into the sac, allowing the coils sufficient space between the catheter tip and the aneurysmal fundus to reform. Although it is unlikely that the balloon

will form a perfect seal at the base of the aneurysm, there is nonetheless the theoretical consideration that when the balloon is inflated, anything delivered into the now closed intraaneurysmal space may cause an increase in intraaneurysmal pressure. Avoiding microcatheter injections with the balloon inflated is therefore desirable; and, in this regard, continuous saline flush infusion of the microcatheter (especially if pressurized) may be hazardous. Aside from increasing the risk of parent artery rupture, full inflation of the balloon may also predispose to a potential, albeit in most cases theoretical, aneurysmal sac seal, and is therefore probably best avoided.

In the untoward event of aneurysm rupture, the inflated balloon can be advantageously used to control subarachnoid hemorrhage. In our case, until hemostasis had been achieved, our aim was to deflate the balloon for as brief a time as possible, allowing only for angiographic runs or repositioning of the catheter tip. The longest period of uninterrupted inflation was 6 minutes. It is desirable to keep this time as brief as possible in order to prevent distal ischemia. However, if rupture is fluoroscopically recognized (as in our case) and the balloon is inflated when heparinization is reversed with protamine sulphate, the blood column distal to the balloon (and aneurysm) remains to some extent anticoagulated, thereby lessening the risk of distal thrombosis. This distal protective effect is, however, lost after the first balloon deflation.

The simultaneous angiographic occurrence of subarachnoid hemorrhage and carotid cavernous fistula, that to our knowledge has not been reported previously, implies that aneurysm rupture can indeed result in concurrent hemorrhage both above and below the dura. According to the criteria established by Day (3), the bilobate aneurysm in this case is best described as a paraclinoid variant of a superior hypophyseal type, as it arose from the ophthalmic segment of the right ICA, independent

of the origin of the ophthalmic artery, and projected inferomedially (see Fig 1A and B). Nutik (4, 5) refers to these as ventral paraclinoid aneurysms and notes their potential to straddle the intracavernous and intradural spaces (intradural neck with a partially intracavernous fundus). This salutary anatomic observation is angiographically underscored by this case.

Conclusion

The balloon-assisted technique is a useful method for coil embolization of wide-necked aneurysms. This case highlights technical aspects of this procedure that potentially may predispose the patient to iatrogenic aneurysmal rupture and also may be an effective management strategy in the event of this complication. In our case, rupture of a ventral paraclinoid aneurysm resulted in angiographic demonstration of a simultaneous subarachnoid hemorrhage and direct carotid cavernous fistula that, to our knowledge, has not been reported previously.

Acknowledgment

We acknowledge Daryl R. Gress for his assistance in the management of this patient and advice in preparing the manuscript.

References

1. Moret J, Pierot L, Boulin A, Castaings L. **"Remodeling" of the arterial wall of the parent vessel in the endovascular treatment of intracranial aneurysms (abstr).** *Neuroradiology* 1994; 36(Suppl 1):S83
2. Mericle RA, Wakhloo AK, Rodriguez R, Guterman LR, Hopkins LN. **Temporary balloon protection as an adjunct to endosaccular coiling of wide-necked cerebral aneurysms: technical note.** *Neurosurgery* 1997;41:975-978
3. Day AL. **Aneurysms of the ophthalmic segment: a clinical and anatomical analysis.** *J Neurosurg* 1990;72:677-691
4. Nutik S. **Carotid paraclinoid aneurysms with intradural origin and intracavernous location.** *J Neurosurg* 1978;48:526-533
5. Nutik SL. **Ventral paraclinoid carotid aneurysms.** *J Neurosurg* 1988;69:340-344