

# Generic Contrast Agents

Our portfolio is growing to serve you better. Now you have a *choice*.



FRESENIUS  
KABI

[VIEW CATALOG](#)

# AJNR

## **Imaging of a Stafne Bone Cavity: What MR Adds and Why a New Name Is Needed**

Barton F. Branstetter, Jane L. Weissman and Sheldon B. Kaplan

*AJNR Am J Neuroradiol* 1999, 20 (4) 587-589

<http://www.ajnr.org/content/20/4/587>

This information is current as  
of May 31, 2025.

## Imaging of a Stafne Bone Cavity: What MR Adds and Why a New Name Is Needed

Barton F. Branstetter, Jane L. Weissman, and Sheldon B. Kaplan

**Summary:** Stafne bone cavities are asymptomatic radiolucencies seen at the angle of the mandible. Although plain films are often sufficient for diagnosis, confirmatory imaging is needed in atypical cases. We describe the MR imaging findings of a Stafne bone cavity, describe the contents, explain why a new name is needed, and discuss the relative merits of different radiologic techniques for establishing this diagnosis.

In 1942, Edward Stafne reported 35 radiolucent lesions in the mandibular angle discovered on intraoral dental films (1). These radiolucencies, now called Stafne bone cavities, represent cortical defects caused by an extension of the submandibular salivary gland (2). A Stafne bone cavity is usually an incidental radiologic finding, most often appearing as a unilateral, ovoid, radiolucent, corticate defect near the angle of the mandible below the inferior alveolar canal. However, bilobate lesions (2), bilateral lesions (3), lesions above the inferior alveolar canal (4), and lesions without sclerotic margins (5) have also been described. The differential diagnosis of mandibular radiolucencies includes benign entities, such as traumatic bone cyst, but also more insidious lesions, such as ameloblastoma (2). Thus, in cases in which the plain film findings are not completely diagnostic, confirmatory testing with sialography, CT, or MR imaging is warranted. To our knowledge, the literature contains no reports of the MR appearance of a Stafne bone cavity.

### Case Report

A 51-year-old man with sinus congestion underwent plain radiography of the paranasal sinuses (Fig 1A). Incidentally noted on these films was a radiolucent defect at the right mandibular angle. Although the patient had no complaints referable to the mandible, he consulted an oral surgeon for further evaluation. The oral surgeon obtained an orthopantomograph, which again showed the corticate radiolucency, and a dental CT scan.

Contiguous, unenhanced, 1-mm-thick, axial CT scans obtained with bone reconstruction algorithms showed the ovoid defect in continuity with the lingual cortex of the mandible (Fig 1B). Parasagittal curved reformatting along the mandible demonstrated the relationship of the radiolucency to the inferior alveolar canal (Fig 1C).

No soft-tissue algorithms were used for the dental CT study. The referring oral surgeon remained unconvinced of the diagnosis, and requested an MR study. MR was performed with a 1.5-T magnet. Axial fast spin-echo proton density-weighted images (3300/17 [TR/TE], 3.0-mm-thick sections with a 0.5-mm gap) (Fig 1D) and coronal spin-echo T1-weighted images (600/16, 3.0-mm-thick sections with a 0.5-mm gap) (Fig 1E) were obtained. The right mandible defect was again identified. It contained soft tissue that was continuous with the adjacent submandibular gland, and was identical in signal intensity to the gland on both sequences. A diagnosis of Stafne bone cavity was made, and no further therapy was instituted.

### Discussion

Many terms have been used to describe asymptomatic radiolucencies at the angle of the mandible: Stafne bone cyst, Stafne bone cavity, static bone cavity, latent bone cyst, developmental bone defect of the mandible, lingual mandibular salivary gland depression, aberrant salivary gland defect, lingual cortical mandibular bone defect, mandibular embryonic defect, submandibular salivary gland inclusion, and combinations of the above (4, 6-8). Similar defects related to the sublingual and parotid glands have been described, located at the mandibular symphysis and the mandibular rami, respectively (9-11). Some authors apply the term Stafne bone cyst to lesions associated with any of the salivary glands (2), while others restrict the term to the submandibular gland, preferring more specific terms, such as anterior lingual mandibular salivary gland defect for the sublingual gland (12).

Stafne bone cavities are most frequent in middle-aged men. The prevalence in published series ranges from 0.10% to 0.48%, but the higher value may be inflated, as that study was performed at a Veterans' hospital with a high proportion of middle-aged men (5). Early reports suggested that the lesion is congenital, but documentation of development in middle age has disputed this contention (13, 14).

Stafne bone cavities are presumed to form by the remodeling of the mandibular cortex around an extension of salivary tissue (4, 15, 16). This theory is supported by findings of radiolucencies in association with each of the three salivary glands. Furthermore, there is a report of Stafne bone cavity

Received April 21, 1998; accepted after revision October 15.

From the Departments of Radiology and Otolaryngology, University of Pittsburgh Medical Center, Presbyterian University Hospital (B.F.B., J.L.W.); and New Jersey Diagnostic Imaging and Therapy Center, Brick, NJ (S.B.K.).

Address reprint requests to Jane L. Weissman, MD, Department of Radiology, University of Pittsburgh Medical Center, PUH D-132, 200 Lothrop St, Pittsburgh, PA 15213.

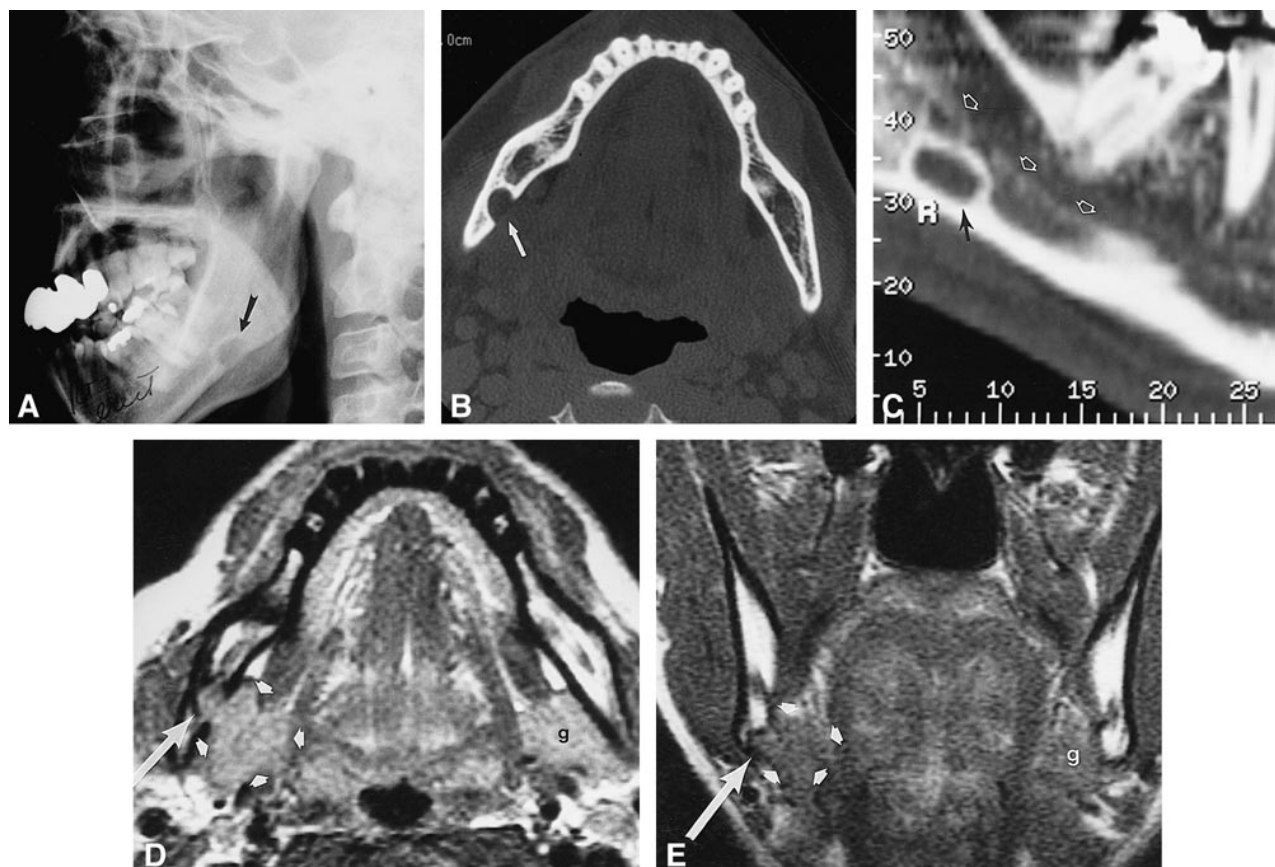


FIG 1. 51-year-old man with a history of sinus congestion.

- A, Lateral radiograph shows a radiolucent, ovoid, corticate lesion anterior to the right mandibular angle (*arrow*).  
 B, Dental CT scan, axial view, shows the radiolucency (*arrow*) to be a corticate defect on the lingual surface of the mandible.  
 C, On parasagittal curved reformatted image, the defect (*black arrow*) is seen to lie below the lower margin of the inferior alveolar canal (*white arrows*).  
 D, Axial proton density-weighted MR image (3300/17/1) shows that the mandibular defect (*long arrow*) contains soft tissue in continuity with, and isointense with, the submandibular salivary gland (*short arrows*). The contralateral gland (*g*) is marked for comparison.  
 E, Coronal T1-weighted MR image (600/16/1) again shows that the bony defect (*long arrow*) contains an extension of tissue from the submandibular gland (*short arrows*).

regression after surgical resection of the herniated gland (15). Most surgical series have noted salivary tissue within the bony defect, but muscle, lymphatic tissue, and blood vessel have also been reported (4). The lack of uniform findings in surgical reports may be explained by intermittent gland herniation, regression of the herniated gland, or surgical disruption of cavity contents (4). Alternative etiologies, such as bone ischemia, have also been proposed (7).

Most case reports of Stafne bone cavities have discussed the findings on intraoral dental films, plain films of the mandible, or orthopantomographs. Although these imaging techniques are often sufficient for diagnosis, they may not be definitive when the lesion is atypical (eg, lobulated, incompletely corticate, multiple, or in an uncharacteristic location). In these situations, confirmatory testing is warranted, as the differential diagnosis for mandibular radiolucencies includes traumatic bone cyst, simple bone cyst, periapical cyst, dentigerous cyst, odontogenic keratocyst, nonossifying fibroma, fibrous dysplasia, ameloblastoma, metastasis, giant

cell tumor, vascular malformation, focal osteoporotic bone marrow defect, basal cell nevus syndrome, and the brown tumor of hyperparathyroidism (2, 4, 12, 17).

Sialography has been used to confirm the diagnosis by depicting salivary ducts within the bony defect (18), but there are case reports of surgically proved Stafne bone cavities with negative sialograms (19). Sialography can be difficult to perform and uncomfortable for the patient, and it exposes the patient to ionizing radiation.

Most CT evaluations of Stafne bone cavities have shown salivary tissue within the defect (18, 20–22), but the largest CT series noted that small Stafne bone cavities may appear to contain only fat or soft tissue (20). As stated above, these findings may be explained by regression of the gland or intermittent herniation. CT has the disadvantages of radiation exposure and possible contrast reactions. These considerations have led some authors to advocate MR imaging as the primary confirmatory technique (12, 23).

MR imaging has the advantages of multiple imaging planes and different echo sequences. Its major disadvantages are cost and field distortion artifacts from dental material. We believe that the diagnosis of Stafne bone cavity may be confirmed with a limited MR examination that shows the mandibular defect containing soft tissue continuous with, and isointense with, the submandibular gland on both proton density- and T1-weighted sequences.

The inherent soft-tissue contrast on both CT and MR studies should be adequate to make the diagnosis of a Stafne bone cavity without intravenous contrast material. (Of course, the CT study must show soft-tissue detail. "Dental"-type CT software programs often display only bone detail.) Should contrast material be administered, the salivary gland contents of a Stafne bone cavity should enhance to the same degree as the adjacent submandibular gland.

The term cyst reflects the initial description on conventional X-ray studies (1), but the so-called Stafne bone "cyst" is not truly a cyst. Fluid contents have never, to our knowledge, been reported. The diagnosis is made when a corticate radiolucency is identified in the characteristic location. Cross-sectional imaging that shows the submandibular gland (or, rarely, other soft tissues) within the bone cavity confirms the diagnosis. For these reasons, a more accurate term is Stafne bone cavity (2). This name acknowledges the initial description by Stafne while introducing the more precise term cavity, which can be applied equally well to conventional X-rays and tomograms, CT, and MR studies.

### Conclusion

Although the diagnosis of a Stafne bone cavity can often be established with plain radiographs, confirmatory testing is sometimes required. In these situations, a limited examination with MR imaging can be definitive, without exposing the patient to ionizing radiation, contrast material, or the discomfort of sialography.

### References

1. Stafne EC. **Bone cavities situated near the angle of the mandible.** *J Am Dent Assoc* 1942;29:1969-1972

2. Prapanpoch S, Langlais RP. **Lingual cortical defect of the mandible: an unusual presentation and tomographic diagnosis.** *Dentomaxillofac Radiol* 1994;23:234-237
3. Sakashita H. **Bilateral static bone defects [letter].** *Oral Surg Oral Med Oral Pathol* 1996;81:380-381
4. Tsui SH, Chan FF. **Lingual mandibular bone defect: case report and review of the literature.** *Aust Dent J* 1994;39:368-371
5. Correll RW, Jensen JL, Rhyne RR. **Lingual cortical mandibular defects: a radiographic incidence study.** *Oral Surg Oral Med Oral Pathol* 1980;50:287-291
6. Thunthy KH. **Dental Radiographic Diagnosis.** Springfield, IL: Charles C Thomas; 1988;259
7. Lello GE, Makek M. **Stafne's mandibular cortical defect: discussion of aetiology.** *J Craniomaxillofac Surg* 1985;13:172-176
8. Archer WH. **Oral and Maxillofacial Surgery.** 5th ed. Philadelphia: Saunders; 1975;1:655-656
9. Richard EL, Ziskind J. **Aberrant salivary gland tissue in the mandible.** *Oral Surg Oral Med Oral Pathol* 1957;10:1086-1090
10. Wolf J. **Bone defects in mandibular ramus resembling developmental bone cavity.** *Proc Finn Dent Soc* 1985;81:215-221
11. Barker GR. **A radiolucency of the ascending ramus of the mandible associated with invested parotid salivary gland material and analogous with a Stafne bone cavity.** *Br J Oral Maxillofac Surg* 1988;26:81-84
12. Barak S, Katz J, Mintz S. **Anterior lingual mandibular salivary gland defect: a dilemma in diagnosis.** *Br J Oral Maxillofac Surg* 1993;31:318-320
13. Wolf J, Mattila K, Ankkuriniemi O. **Development of a Stafne mandibular bone cavity.** *Oral Surg Oral Med Oral Pathol* 1986; 61:519-521
14. Hansson LG. **Development of a lingual mandibular bone cavity in an 11-year-old boy.** *Oral Surg Oral Med Oral Pathol* 1980; 49:376-378
15. Shibata H, Yoshizawa N, Shibata T. **Developmental lingual defect of the mandible: report of a case.** *Int J Oral Maxillofac Surg* 1991;20:328-329
16. Salman L, Chaudhry AP. **Malposed sublingual gland in the anterior mandible: a variant of Stafne's idiopathic bone cavity.** *Compendium* 1991;12:40-43
17. Adra NA, Barakat N, Melhem RE. **Salivary gland inclusion in the mandible: Stafne's idiopathic bone cavity.** *AJR Am J Roentgenol* 1980;134:1082-1083
18. Tominaga K, Kuga Y, Kubota K, Ohba T. **Stafne's bone cavity in the anterior mandible: report of a case.** *Dentomaxillofac Radiol* 1990;19:28-30
19. Oikarinen VJ, Wolf J, Julku M. **A stereosialographic study of developmental mandibular bone defects (Stafne's idiopathic bone cavities).** *Int J Oral Surg* 1975;4:51-54
20. Arijji E, Fugiwara N, Tabata O, et al. **Stafne's bone cavity: classification based on outline and content determined by computer tomography.** *Oral Surg Oral Med Oral Pathol* 1993;76: 375-380
21. Slasky BS, Bar-Ziv J. **Lingual mandibular bone defects: CT in the buccolingual plane.** *J Comput Assist Tomogr* 1996;20:439-443
22. Bourjat P, Cavezian R, Pasquet G. **Stafne's lacuna, a salivary inclusion in the mandible [in French].** *J Radiol* 1985;66:71-73
23. Grelliner TJ, Frost DE, Brannon RB. **Lingual mandibular bone defect: report of three cases.** *J Oral Maxillofac Surg* 1990;48: 288-296