



Providing Choice & Value

Generic CT and MRI Contrast Agents



**FRESENIUS
KABI**

CONTACT REP

AJNR

Transluminal Angioplasty for Middle Cerebral Artery Stenosis in Patients with Acute Ischemic Stroke

Dae Chul Suh, Kyu-Bo Sung, Yong Soo Cho, Choong Gon Choi, Ho Kyu Lee, Jae Hong Lee, Jong Sung Kim and Myoung Chong Lee

This information is current as of July 14, 2025.

AJNR Am J Neuroradiol 1999, 20 (4) 553-558

<http://www.ajnr.org/content/20/4/553>

Transluminal Angioplasty for Middle Cerebral Artery Stenosis in Patients with Acute Ischemic Stroke

Dae Chul Suh, Kyu-Bo Sung, Yong Soo Cho, Choong Gon Choi, Ho Kyu Lee,
Jae Hong Lee, Jong Sung Kim, and Myoung Chong Lee

BACKGROUND AND PURPOSE: Percutaneous transluminal angioplasty (PTA) is currently performed to treat supraprostatic atherosclerotic lesions. Our purpose was to evaluate the safety and efficacy of PTA for middle cerebral artery (MCA) stenosis in patients with acute ischemic stroke.

METHODS: We performed PTA with the use of a microballoon (2–2.5 mm in diameter and 10–13 mm in length) in 10 consecutive patients (mean age, 48 years) who met the following criteria: high-grade M1 stenosis ($> 70\%$) and mild neurologic deficits (NIH stroke scale < 4) and/or recurrent transient ischemic attacks (TIAs) resistant to anticoagulation, or a large area of hypoperfusion in the MCA territory on brain perfusion SPECT scans. During follow-up, we administered antiplatelet agents and evaluated the status of restenosis by angiography ($n = 2$), brain perfusion SPECT ($n = 4$), and/or transcranial Doppler sonography (TCD) ($n = 7$).

RESULTS: Stenotic arteries were successfully dilated in nine of 10 patients. Angioplasty failed in one patient because the balloon could not pass through the tortuous cavernous internal carotid artery. None of the patients experienced either peri- or postangioplasty complications. Residual stenosis was less than 50%, and clinical improvement, including elimination of TIAs in four patients who had suffered resistant TIAs, was observed in all patients; improvement of the cerebral perfusion was also noted in two patients with a large hypoperfusion area in the MCA territory. The average follow-up period was 11 months (range, 2 to 36 months). None experienced recurrent stroke during the follow-up period. TCD revealed decreased flow velocity of the MCA after angioplasty in seven patients.

CONCLUSION: PTA of the proximal portion of the MCA seems to be a safe and effective therapeutic technique for the prevention of secondary ischemic stroke.

Percutaneous transluminal angioplasty (PTA) is currently performed to treat supraprostatic atherosclerotic lesions. The development of microballoon catheter technology has made PTA possible in the intracranial arteries, even in occluded vessels (1–10). Several reports have been published concerning the usefulness of angioplasty in the treatment of atherosclerotic stenosis of intracranial vessels (8–10). They also noted that PTA in the middle cerebral artery (MCA) carries a significant risk of complications. We present a retrospective review of

our experience in 10 patients with M1 stenosis treated with PTA.

Methods

From 1995 to 1998, 10 patients with symptomatic stenosis of the MCA were treated using PTA. They included seven men and three women, with a mean age of 48 years (range, 31–62 years). The clinical presentations were ischemic stroke in six patients and transient ischemic attacks (TIAs) in four patients (Table). Neurovascular examination consisted of CT, MR imaging, MR angiography, or transcranial Doppler sonography (TCD). Brain perfusion single-photon emission CT (SPECT) was performed in nine patients before PTA and showed decreased perfusion on the lesion side in eight patients and was normal in one patient with TIA (patient 2). All patients were treated with maximum medical therapy, consisting of anticoagulants and/or antiplatelet agents. Warfarin was introduced to maintain INR between 2.0 to 3.0. Heparin was given to maintain activated partial thromboplastin time at two to three times the baseline level. Antiplatelet agents were given orally with the doses of aspirin, 100 mg, and/or ticlopidine, 250 mg.

Cerebral angiography documented the stenosis, and PTA was subsequently performed. An endovascular technique was used with a transfemoral approach under local anesthesia. All patients were sedated with intravenous midazolam. Systemic

Received August 21, 1998; accepted after revision November 20.

From the Departments of Radiology (D.C.S., K-B.S., Y.S.C., C.G.C., H.K.L.) and Neurology (J.H.L., J.S.K., M.J.L.), Asan Medical Center, University of Ulsan, College of Medicine, Seoul, Korea.

Address reprint requests to Dae Chul Suh, MD, Department of Radiology, Asan Medical Center, University of Ulsan, College of Medicine, 388–1, Poongnap-Dong, Songpa-Ku, Seoul 138–736, Korea.

Summary of clinical findings and outcomes in 10 patients

Case	Age/Sex	Stenosis Site	Clinical Findings	Percentage (%) of Stenosis		Diam. × Length of Balloon (mm)	Time to Follow-up Studies			Period of Clinical Follow-up (mo)
				Pre	Post		SPECT	Angiography	TCD (R/L cm/s)	
1	31/M	R M1	Multiple TIAs	90	0	2 × 10	5d; NC	2 mo; remodeling 8 mo; no restenosis	8 mo; 151/71	10
2	49/M	R M1	TIA with L hemiparesis	80	0	2.5 × 10	ND	ND	29 mo; 186/81 36 mo; 170/77	36
3	62/M	L M1	Stroke with aphasia, R hemiparesis	80	20	2 × 10	1 d; NC	ND	ND	6
4	50/M	L M1	Stroke with aphasia	70	40	2.5 × 13	ND	7 mo; NC	Pre; 43/215 2 d; 42/119	11
5	43/M	L M1	Stroke with R hemiparesis, dysarthria	70	30	2.5 × 13	1 d; incr	ND	9 mo; 48/157 1 mo; 52/107 4 mo; 55/111	10
6	49/M	R M1	Stroke with L hemiparesis	70	...	Failed PTA	1 mo; decr	ND	ND	10
7	45/F	R M1	Stroke with L hemiparesis	70	40	2 × 13	ND	ND	Pre; 281/110 4 d; 154/102	11
8	53/M	R M1	Stroke with L hemiparesis	70	0	2 × 10	ND	ND	ND	10
9	60/F	L M1	TIA	70	30	2 × 10	ND	ND	Pre; 60/346 1 d; ND/168	2
10	42/F	L M1	TIA with R hemiparesis	90	40	2 × 10	ND	ND	Pre; 113/300 2 d; 82/218	2

Note.—Diam. indicates diameter; TCD, transcranial Doppler sonography; L, left; R, right; TIA, transient ischemic attack; ND, not done; NC, no change; e, Incr; Increased; Decr, decreased; Pre, preangioplasty; Post, postangioplasty; PTA, percutaneous transluminal angioplasty.

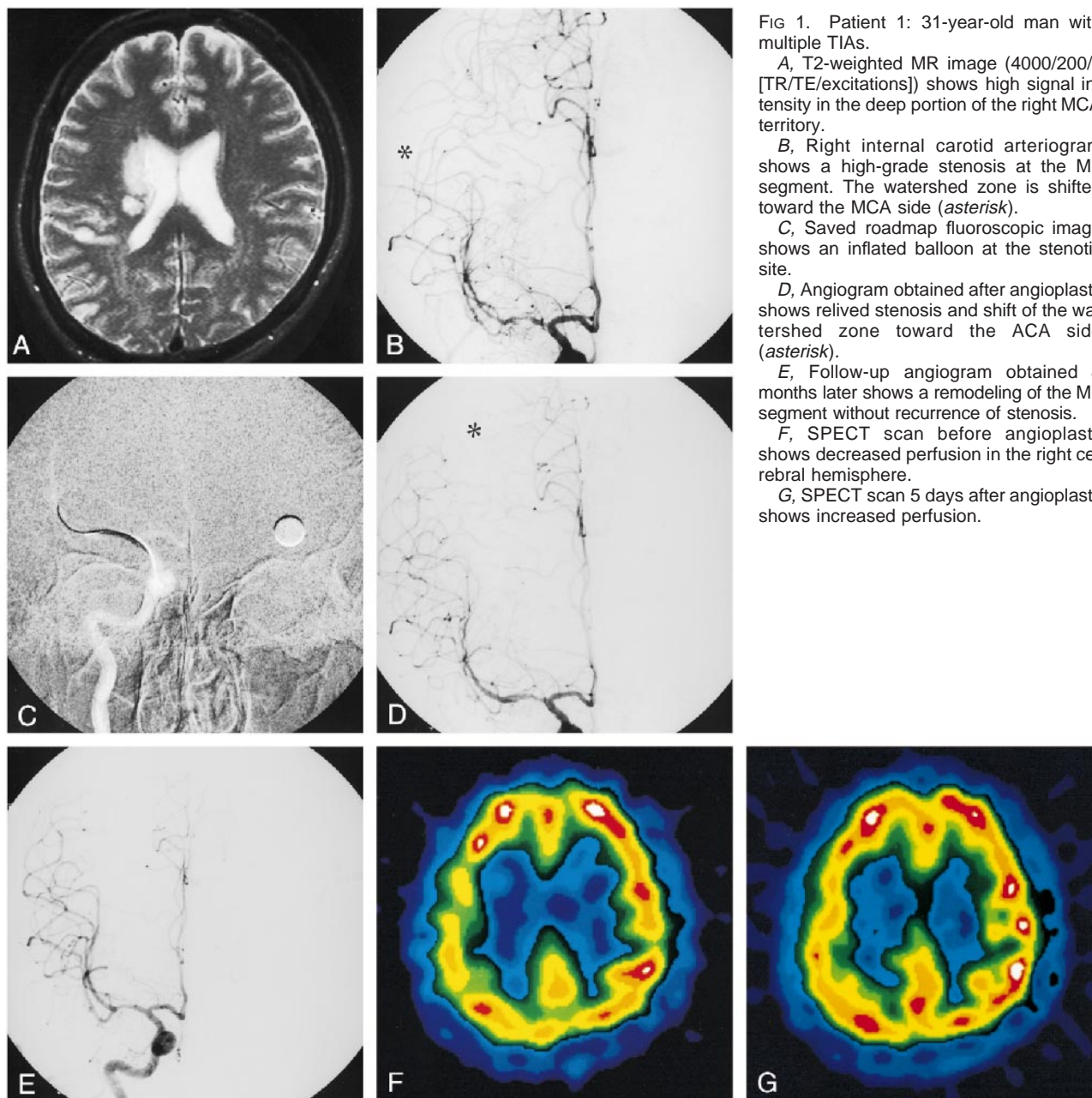


FIG 1. Patient 1: 31-year-old man with multiple TIAs.

A, T2-weighted MR image (4000/200/4 [TR/TE/excitations]) shows high signal intensity in the deep portion of the right MCA territory.

B, Right internal carotid arteriogram shows a high-grade stenosis at the M1 segment. The watershed zone is shifted toward the MCA side (*asterisk*).

C, Saved roadmap fluoroscopic image shows an inflated balloon at the stenotic site.

D, Angiogram obtained after angioplasty shows relieved stenosis and shift of the watershed zone toward the ACA side (*asterisk*).

E, Follow-up angiogram obtained 8 months later shows a remodeling of the M1 segment without recurrence of stenosis.

F, SPECT scan before angioplasty shows decreased perfusion in the right cerebral hemisphere.

G, SPECT scan 5 days after angioplasty shows increased perfusion.

heparinization was achieved by giving intravenous heparin and determining the activated clotting time (two to three times the baseline value). Heparinization was continued for at least 24 hours after PTA. After a 6F guiding catheter was introduced into the internal carotid artery, 50 to 100 μ g of nitroglycerin was injected through the guiding catheter into the stenotic vessel to prevent or treat spasm at the site of the PTA. A microballoon was coaxially inserted along the microguidewire. The balloon diameter ranged from 2 to 2.5 mm and its length was 10 to 13 mm. A Stealth balloon catheter (Boston Scientific Corp, Boston, MA) was used in five patients, a Stratus (Medtronic; Microinterventional Systems Inc, Sunnyvale, CA) in two, and a Viva primo 18 (Boston Scientific Corp) in three patients. The balloon was inflated two to three times at 6 to 8 atm for less than 20 seconds. Following PTA, selective angiography was performed to determine the degree of dilatation and whether dissection had occurred, and to evaluate the intracranial circulation for signs of distal embolization. The patient's neurologic state was carefully observed before, during,

and after the PTA procedure. The arteries subjected to PTA were slightly underdiluted to prevent potential vessel rupture. A technically successful PTA was defined as one leaving a residual stenosis of 50% or less. Seven patients have been followed up with TCD to check for restenosis. Follow-up angiography was performed in one patient after 3 and 8 months and in another patient after 7 months. Mean clinical follow-up time was 11 months (range, 2–36 months).

Results

The clinical presentation, imaging studies, angiographic findings, outcome, and follow-up findings are summarized in the Table. PTA was successfully performed in nine patients; in one patient, the balloon catheter could not be advanced owing to a tortuous internal carotid artery. The angiographic

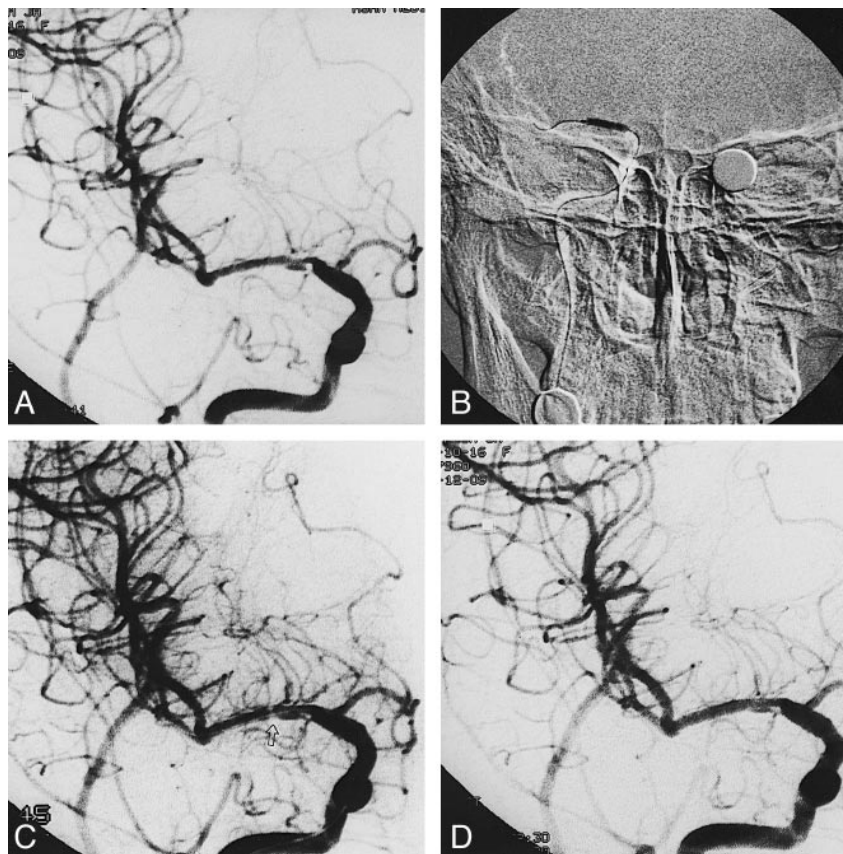
FIG 2. Patient 7: 45-year-old woman with stroke.

A, Right internal carotid arteriogram shows tight stenosis with ulceration in the M1 segment.

B, Saved roadmap fluoroscopic image shows a dilated balloon at the stenotic site.

C, Angiogram obtained after angioplasty shows a focal spasm at the distal end of the balloon position (arrow).

D, Final angiogram obtained after nitroglycerin infusion shows no further spasm and improved flow into the MCA.



signs of successful angioplasty included residual stenosis of the lesion of less than 50% ($n = 9$), increased flow of contrast agent into the MCA ($n = 9$), and shift of the watershed zone between the anterior cerebral artery (ACA) and the MCA toward the ACA side owing to increased flow into the MCA ($n = 3$). Shift of the watershed zone was not noted in two patients who had a hypoplastic A1 and in four patients who had a normal A1 segment. A small filling defect suggesting intimal dissection was noted at the angioplasty site in two patients. However, flow into the MCA was improved despite the filling defect in those patients. Follow-up perfusion SPECT was performed in four patients within 1 month after angioplasty. Perfusion had improved in two, has remained the same in one, and was aggravated in one patient in whom angioplasty failed. There was no symptomatic recurrence of stroke or TIA during the follow-up period (range, 2–36 months; mean, 11 months).

Discussion

The efficacy of angioplasty in the M1 segment has not yet been determined (1–10). Our experience in nine patients showed no symptomatic recurrence in any patient during the 10-month mean follow-up period. Although angiographic restenosis was not completely evaluated in our patients, except in two in whom there was no evidence of restenosis, TCD examination of seven patients revealed de-

creased flow velocity after angioplasty, even though the velocity did not return to the normal level. Restenosis should be evaluated by follow-up angiography because the TCD examination is somewhat operator-dependent and sometimes unreliable. In one of our patients, restenosis was suggested on the basis of increased flow velocity on TCD, but angiography showed no change of the M1 segment 7 months after angioplasty. However, because of the lack of long-term follow-up results, we are not sure that angioplasty of the MCA had a significant effect on the long-term natural history of these patients' disease.

Angiographic signs of successful angioplasty include relieved stenosis, improved flow into the MCA, and shift of the watershed zone between the MCA and the ACA onto the normal side. This shift of watershed zone was detected in three patients in whom the zone shifted toward the MCA side because of hypoperfusion of the MCA before angioplasty (Fig 1). To ensure visualization of the hemodynamic changes within the cerebral hemisphere, we included the whole brain of the patients within the field of the selected image intensifier when we obtained angiograms before and after angioplasty. The angiographic shift of the watershed zone was identified and compared when the contrast agent filled both cortical branches of the MCA and the ACA. Detection of the angiographic shift of the watershed zone seemed to be a usable sign of successful angioplasty and was

unique in our series; it has not yet been described in the literature.

Angioplasty of the MCA has been performed under high risk. Touho (3) reported the results of MCA angioplasty in nine patients. Among them, six had M1 lesions and three had M2 lesions. Two patients with stenosis in the M1 segment suffered transient aggravation of hemiparesis after PTA, which improved to better than that before the procedure within 1 month. Takis et al (4) reported an experience in a patient with a 90% stenosis of the MCA at the M1 segment. Although residual stenosis was not noted on the angiogram obtained immediately after angioplasty, symptomatic vasospasm developed 1 hour later. Angiography showed occlusion at the angioplasty site, which had not responded to local infusion of 300 mg of papaverine and 20 mg of alteplase for thrombolysis. In our experience with 10 patients, there was no significant complication either during or after angioplasty. We believe that this result is most likely attributable to the exactness of the measurement of the lumen size, to the slight underdilatation of the stenotic M1, and to the choice of the most suitable microballoon for each patient. We used a spherical metallic coin as a reference during angiography and measured the lumen size with the software program in the angiographic unit.

Overdilatation seems to be dangerous when performing angioplasty of intracranial vessels. Purdy et al (8) effected an overdilatation in a patient with a silicone balloon that was larger than the vessel size. Although the patient remained asymptomatic and the procedure resulted in improved cerebral perfusion, the angioplasty caused severe spasm of the MCA for an ensuing 45 minutes. On the other hand, Tsai et al (7) minimized the risk of complication by underdilating the stenosis, because cerebral blood flow may be restored to normal with 50% of the normal-vessel caliber. Successful PTA was performed in two patients without causing any problems. Nakano et al (6) successfully treated 10 patients using 2- to 2.5-mm microballoons. They set the initial goal of angioplasty at 50% stenosis, keeping the dilatation force within 2 to 3 atm to prevent arterial rupture or spasm.

Two of our patients had a filling defect in the wall or lumen of the MCA after angioplasty. We thought it resulted from the angioplasty, not from the actual dissection of the intima, which could compromise flow into the MCA. Flow of contrast agent into the MCA was improved in those patients and there was even a shift of the watershed zone onto the ACA side in one patient. Our patients did not experience any new neurologic deficit after angioplasty. Therefore, we thought the filling defects at the site of angioplasty in two patients seemed to be caused by a longitudinal intimal tear as a response to the angioplasty. We used a monorail microballoon catheter of the type used for coronary angioplasty in three patients because we could load a flexible stent onto the balloon catheter without an

exchange guidewire in order to insert the stent immediately in case of flow arrest caused by inadvertent dissection at the angioplasty site. Fortunately, dissection did not occur.

We postulate that angioplasty of the MCA is different from that of the extracranial vessels, in that the MCA is in the subarachnoid space and floats in the cerebrospinal fluid. There is no supporting connective tissue around the vessel. Therefore, risk of serious or even fatal rupture is very high. Underdilatation seems to be important to prevent vessel rupture or spasm (6–8). When there is resistance in the balloon catheter, forceful introduction of the balloon is dangerous. We switched to another type of microballoon catheter in case of high resistance during insertion of the microballoon. The second difference is that the MCA has cortical branches that receive leptomeningeal collaterals through anterior and posterior cerebral arteries. The collateral flow cannot be estimated and is occasionally grossly insufficient when the M1 is suddenly occluded. In such cases, we need to inflate the microballoon quickly and effectively. Inflation in 10 to 20 seconds is usually enough at 6 to 8 atm.

When stenosis of the M1 segment involves the origin of the lenticulostriate arteries, occlusion of these arteries can theoretically occur after angioplasty. However, we did not experience symptomatic complications related to occlusion of the lenticulostriate arteries. This result may suggest that those branches of the lenticulostriate arteries originating in the target vessel are not compromised after angioplasty.

One patient experienced spasm of the M1 segment after deflation of the microballoon (Fig 2). Spasm can be induced during insertion or inflation of the microballoon. We used nitroglycerin (50 to 100 μ g) to prevent or relieve spasm in the M1 segment (7, 11). Careful introduction of the microballoon into the carotid siphon seems important to avoid vessel injury or spasm. It is also necessary to evaluate the course of the internal carotid artery before angioplasty. We were unable to pass three different types of microballoon into a patient with a tortuous carotid siphon.

Conclusion

Angioplasty of the MCA seems to be an effective and safe procedure for relieving stenosis of the M1 and for preventing acute ischemic stroke while not causing any symptomatic complication or symptomatic recurrence. Further long-term angiographic follow-up will be necessary to evaluate the restenosis process.

Acknowledgment

We thank Bonnie Hami, Department of Radiology, University Hospitals of Cleveland, for editorial assistance in the preparation of the manuscript.

References

1. Higashida RT, Tsai FY, Halbach VV, et al. **Transluminal angioplasty for atherosclerotic disease of the vertebral and basilar arteries.** *Heart Dis Stroke* 1993;2:497-502
2. Higashida RT, Tsai FY, Halbach VV, et al. **Transluminal angioplasty for atherosclerotic disease of the vertebral and basilar arteries.** *J Neurosurg* 1993;78:192-198
3. Touho H. **Percutaneous transluminal angioplasty in the treatment of atherosclerotic disease of the anterior cerebral circulation and hemodynamic evaluation.** *J Neurosurg* 1995;85:953-960
4. Takis C, Kwan ES, Pessin MS, Jacobs DH, Caplan LR. **Intracranial angioplasty: experience and complications.** *AJNR Am J Neuroradiol* 1997;18:1661-1668
5. McKenzie JD, Wallace RC, Dean BL, Flom RA, Khayata MH. **Preliminary results of intracranial angioplasty for vascular stenosis caused by atherosclerosis and vasculitis.** *AJNR Am J Neuroradiol* 1996;17:263-268
6. Nakano S, Yokogami K, Ohta H, Yano T, Ohnishi T. **Direct percutaneous transluminal angioplasty for acute middle cerebral artery occlusion.** *AJNR Am J Neuroradiol* 1998;19:767-772
7. Tsai FY, Berberian B, Matovich V, Lavin M, Alfieri K. **Percutaneous transluminal angioplasty adjunct to thrombolysis for acute middle cerebral artery rethrombosis.** *AJNR Am J Neuroradiol* 1994;15:1823-1829
8. Purdy PD, Devous MD, Unwin DH, Giller CA, Batjer HH. **Angioplasty of atherosclerotic middle cerebral artery associated with improvement in regional cerebral blood flow.** *AJNR Am J Neuroradiol* 1990;11:878-880
9. Mori T, Mori K, Fukuoka M, Arisawa M, Honda S. **Percutaneous transluminal cerebral angioplasty: serial angiographic follow-up after successful dilatation.** *Neuroradiology* 1997;39:111-116
10. Gil-Peralta A, Mayol A, Marcos JR, et al. **Percutaneous transluminal angioplasty of the symptomatic atherosclerotic carotid arteries: results, complications, and follow-up.** *Stroke* 1996;27:2271-2273
11. Tegeler CH, Davidai G, Gengo FM, et al. **Middle cerebral artery velocity correlates with nitroglycerin-induced headache onset.** *J Neuroimaging* 1996;6:81-86