



Discover Generics

Cost-Effective CT & MRI Contrast Agents



WATCH VIDEO

AJNR

Localization of the First and Second Somatosensory Areas in the Human Cerebral Cortex with Functional MR Imaging

Gabriele Polonara, Mara Fabri, Tullio Manzoni and Ugo Salvolini

AJNR Am J Neuroradiol 1999, 20 (2) 199-205

<http://www.ajnr.org/content/20/2/199>

This information is current as of June 19, 2025.

Localization of the First and Second Somatosensory Areas in the Human Cerebral Cortex with Functional MR Imaging

Gabriele Polonara, Mara Fabri, Tullio Manzoni, and Ugo Salvolini

BACKGROUND AND PURPOSE: Our objective was to map by means of a conventional mid-field (1.0 T) MR imaging system the somatosensory areas activated by unilateral tactile stimulation of the hand, with particular attention to the areas of the ipsilateral hemisphere.

METHODS: Single-shot echo-planar T2*-weighted imaging sequences were performed in 12 healthy volunteers to acquire 10 contiguous 7-mm-thick sections parallel to the coronal and axial planes during tactile stimulation of the hand. The stimulation paradigm consisted of brushing the subjects' palm and fingers with a rough sponge at a frequency of about 1 Hz.

RESULTS: Stimulation provoked a signal increase (about 2% to 5%) that temporally corresponded to the stimulus in several cortical regions of both hemispheres. Contralaterally, activation foci were in the anterior parietal cortex in an area presumably corresponding to the hand representation zone of the first somatosensory cortex, in the posterior parietal cortex, and in the parietal opercular cortex forming the upper bank of the sylvian sulcus and probably corresponding to the second somatosensory cortex. Activation foci were also observed in the frontal cortex. Ipsilaterally, activated areas were in regions of the posterior parietal and opercular cortices roughly symmetrical to those activated in the contralateral hemisphere. The same activation pattern was observed in all subjects.

CONCLUSION: The activated areas of the somatosensory cortex described in the present study corresponded to those reported in other studies with magnetoencephalography, positron emission tomography, and higher-field functional MR imaging. An additional area of activation in the ipsilateral parietal operculum, unnoticed in other functional MR imaging studies, was also observed.

Over the last few years, functional MR imaging has provided a safe and noninvasive method to study human brain function in vivo (1, 2). Its superior time and space resolution, the possibility of obtaining both anatomic and functional images in the same session, and the absence of radiation exposure give it advantages over positron emission tomog-

raphy (PET), another widely used functional imaging method.

Functional MR imaging has been widely used to study auditory, motor, visual, and somatosensory systems in the human cerebral cortex (3). Investigations of the cortical somatosensory system (4–14) have been focused mainly on the hand region (6–10) or the whole body map (11–13) of the postcentral cortex corresponding to the first somatosensory area (SI). Somatosensory cortical activation outside SI has occasionally been described: tactile stimulation of the hand evoked a focus of activation in a region of the parietal opercular cortex of the contralateral hemisphere corresponding to the second somatosensory area (SII) (13), while active tactile exploration (14) and passive tactile stimulation (13) produced activation in a region of the posterior parietal cortex lying posteriorly and medially to SI, and probably corresponding to the cytoarchitectonic areas 2 through 5 (13, 14). Somatosensory activation in the ipsilateral hemisphere has been reported in the posterior parietal cortex but not in SII (6, 13, 14). Conversely, bilateral activation of the parietal oper-

Received March 26, 1998; accepted after revision October 13.

Supported by Italian Ministero della Ricerca Scientifica e Tecnologica (MURST: MA2A031171, MA2U031171), Italian Consiglio Nazionale delle Ricerche (CNR CT04 96.03396 and CNR CT04 95.02330).

Presented at the 35th annual meeting of the American Society of Neuroradiology, Toronto, Ontario, May 1997.

From the Department of Neuroradiology (G.P., U.S.) and the Institute of Human Physiology (M.F., T.M.), University of Ancona, Italy.

Address reprint requests to Prof. Ugo Salvolini, Cattedra di Neuroradiologia, Facoltà di Medicina, Università degli Studi di Ancona, Ospedale Regionale di Torrette, Via Conca 1, 60020 Torrette, Ancona, Italy.

culum during unilateral stimulation of somatosensory receptors or nerves has been described in humans with the use of several other techniques, such as somatosensory evoked potentials (SEPs) (15–19), magnetoencephalography (MEG) (19–27), and PET (28–30).

The aim of the present research was to use 1.0-T functional MR imaging to investigate the activation of cortical somatosensory areas, in particular those of the ipsilateral hemispheres, in a group of healthy volunteers whose hand and finger surfaces were stimulated with moving tactile stimuli. In nonhuman primates, our stimulation paradigm proved to be the most effective in activating neurons in the posterior parietal (31) and parietal opercular (32–34) cortices containing the bilateral representation of the body surface. The use of a 1.0-T system supports recent data on sensorimotor and visual systems (35–37) showing that even mid-field magnets, though mainly used for diagnostic purposes, are able to generate functional images of cortical activation similar to those obtained with higher-field scanners (see [1] for a review).

Methods

Twelve healthy volunteers, 21 to 59 years old, gave their informed consent to participate in the study. Four subjects participated twice and one subject three times at intervals of 2 to 3 months. All but two were strongly right-handed, as determined by the Edinburgh handedness survey (38). Subjects were placed in a 1.0-T scanner equipped with 23 mT/m gradients, their heads firmly restrained within the standard, circularly polarized, head coil. A chin-holder was used to avoid flexion and extension movements of the head. Subjects were instructed to keep their eyes closed and to find a comfortable position and relax, avoiding even minimal movement; their ears were plugged. The first step consisted of the acquisition of a 2D spoiled gradient-recalled (SPGR) anatomic sagittal localizer image to select section levels with parameters of 120/15/1 (TR/TE/excitations); flip angle, 70°; field of view, 23 × 23 cm; section thickness, 7 mm; matrix, 256 × 256; and a scan time of 31 seconds. The second step involved functional MR acquisitions in coronal planes with a single-shot echo-planar T2*-weighted sequence (3000/60/1); flip angle, 90°; field of view, 28 × 21 cm; matrix, 96 × 64; and scan time of 2:30 minutes. The coronal planes were orthogonal to the sagittal plane and parallel to the floor of the fourth ventricle, as identified on the midline sagittal plane localizer image. Coronal sections were chosen because they clearly show the sylvian sulcus and the opercular cortex containing SII. Ten contiguous 7-mm-thick coronal sections were selected, and 500 coronal functional images (50 per section, one image every 3 seconds) were acquired during the stimulation/rest cycle. Tactile stimulation consisted of the experimenter brushing the subject's right palm and fingers with a rough sponge (glued to a wooden support) at a frequency of about 1 Hz. This kind of stimulation, which activates tactile and vibration receptors and probably also deep receptors, has been proved to be highly effective for activating neurons in somatosensory areas outside SI (area 3b), in particular areas 2 through 5 and SII in the macaque monkey (31–34). The stimulation paradigm lasted 2:30 minutes and consisted of five alternating 30-second periods, three of rest and two of stimulation. Several paradigms were repeated in each subject over a period of about 30 minutes. To compensate for nonspecific signal intensity changes (39), the experimenter made similar stimulus movements 10 to 15 cm above the sub-

ject's hand during the rest periods. Consecutive images from each section were examined in cine mode to detect possible motion of the head (see [40] for a review). Stimulation trials during which head movement was detected were discarded. Functional images were obtained with the blood oxygenation level-dependent (BOLD) contrast method.

The third step involved the acquisition of anatomic 2D-SPGR images (100/12/1; flip angle, 70°; field of view, 28 × 21 cm; thickness, 7 mm; matrix, 256 × 256; scan time 3:17 minutes for 10 images) in the same coronal plane so that the functional images could be superimposed on the anatomic images. The latter also allows visualization of blood vessels, which are possible sources of BOLD signal (40). The second and third steps were repeated to acquire functional images from axial sections, since axial views allow clear identification of the central sulcus and consequently of the postcentral cortex. The axial planes were orthogonal to both the sagittal and coronal planes. Ten contiguous 7-mm-thick axial sections were selected, and 500 axial functional images (50 per section, one image every 3 seconds) were acquired during another 2:30-minute stimulation cycle. Then, high-resolution anatomic images were acquired in the same axial planes as the functional images.

At the end of the experimental session, the acquired images were transferred to a Unix workstation (Advantage Windows 1.2, General Electric, Milwaukee, WI) and analyzed by means of proprietary software (Functool, General Electric). The software calculates a correlation coefficient that relates the time-course data to a reference function, which is a periodic square wave (41). The correlation coefficient is related to the *t* parameter of Student's *t*-test by a precise relationship and thresholded by a confidence level selected by the operator (its value was usually ≤ 0.00001 ; ie, a 0.001% probability that the signal increase is unrelated to the reference function). For each image (obtained by superimposing the functional and the anatomic images from the same section level), the software builds a "correlation map" displaying, with the aid of a color scale, the degree of correlation of each pixel value with the square wave: red pixels indicating strong correlation, blue pixels poor correlation. For each of the activated cortical zones, a region of interest (ROI) was selected, and for each ROI the software allowed visualization of the signal variation that occurred during the stimulation cycle. The area of the ROI was kept as uniform as possible (43 mm²) among subjects and among the different cortical areas. The signal change was then displayed as a graph, in which the x-axis is in fact a temporal scale reporting the progressive number of functional images acquired (one image every 3 seconds), and the y-axis represents the signal expressed as a percentage of the signal obtained from the brain during the rest periods (baseline). The signal increase ranged from approximately 2% to 5% above baseline, depending on the cortical area studied. This estimation was obtained, for each graph, by calculating the mean percentage value of the signal during the first and second rest periods, the mean percentage value of the signal increase during the two stimulation periods, and by calculating the difference between these two mean values. Since the area of the ROIs was kept uniform (43 mm²), in some cases small portions of inactivated cortex could have been included. In these instances, the signal increase might be underestimated, because the mean value resulted from all the pixels included in the ROI.

The somatosensory areas were identified by analyzing their anatomic location as defined both by standard anatomic landmarks (eg, the ω -shaped central sulcus in the axial views) and by a reference atlas (42).

Results

In all subjects, unilateral tactile stimulation of the hand provoked local blood-flow increases in several cortical areas of the contralateral and ipsi-

lateral hemispheres, which were temporally correlated with the stimulation pattern.

Contralaterally, the activated regions were in the anterior and posterior parietal cortex, in the parietal operculum, and in the frontal cortex. Figure 1, from a representative case (subject GP), shows an activation focus in the anterior parietal cortex just posterior to the central sulcus, along its upper genu (Fig 1A, box 1). In this region, the signal increase observed during stimulation was about 5% above baseline (Fig 1B). Another activation focus was in the posterior parietal cortex (Fig 1C, box 2); it was smaller in extent than the one in the anterior parietal cortex, and the signal increased slightly less than 2% above baseline (Fig 1D, graph 2, purple). However, since an activation focus in this region was present in all subjects, and since the signal increase, though small, closely corresponded to the temporal pattern of stimulation, the activation in the posterior parietal cortex was considered a significant response to the stimulation rather than to noise. Moreover, the second ROI appears to include a small portion of inactivated cortex and, consequently, in this case the signal increase may be underestimated (see Methods). Figure 2 shows the activation focus in the parietal opercular cortex in another representative case (subject MF); the activated region lay on the upper bank of the sylvian sulcus (Fig 2A and B) and was evident on both coronal (Fig 2A, box 4) and axial (Fig 2D, box 6) images. The signal was about 3% above baseline (Fig 2C, graph 4, green, and Fig 2E, graph 6, green). The blood flow increased also in a region of the medial frontal cortex (Figs 1A and C and 2A), where the signal exceeded baseline by about 2%. Often, activation was also observed in the prerolandic cortex (Figs 1A and C and 2A).

In the ipsilateral hemisphere, activation foci were present in the posterior parietal cortex and in the parietal opercular cortex of all subjects. In the former location, the activation focus was in a region symmetrical to that observed in the homotopic contralateral area (Fig 1C, box 3). In the parietal opercular cortex, the activation focus was in the upper bank of the sylvian sulcus (Fig 2A, box 5, and Fig 2D, box 7), in a region roughly symmetrical to the activated homotopic area in the contralateral hemisphere (Fig 2A, box 4, and Fig 2D, box 6); the signal increase was about the same as that recorded in the contralateral symmetrical focus (2% to 3% above baseline).

Finally, activation was observed in two distinct regions of the ipsilateral cerebellar cortex (Fig 3; taken from a third case, subject AP). One focus was in the superior aspect (box 8) and the other in the inferior aspect (box 9) of the intermediate part of the cerebellar hemisphere.

Repetition of the same stimulation paradigm in the same subjects (MM, TM, MP, MF, GP, see Table) at an interval of 2 to 3 months resulted in activation of the same contralateral and ipsilateral cortical areas.

Discussion

The present functional MR imaging study provides a description of the activation pattern of contralateral and ipsilateral cortical somatosensory areas during unilateral tactile stimulation of the hand and fingers, reproducing results obtained in previous studies with different techniques. Moreover, we observed activation of the ipsilateral SII, undetected in other functional MR imaging studies.

Somatosensory activation of a region of the anterior parietal cortex has been reported in previous high-field functional MR imaging studies (4–14). This region lies along the upper genu of the central sulcus, which can be readily identified in axial projections by its ω shape. In a previous PET study, vibratory stimulation of the hand provoked a marked blood-flow increase in the cortex posterior to the central sulcus, in correspondence to its upper genu (9). This anatomic landmark identifies the hand representation zone of SI (9, 10). Moreover, by recording the same subject's SEPs and functional MR imaging data, a strict topographic correspondence was shown between the hand region of SI identified by SEPs and the region activated during sensory tasks involving the hand (12). MEG (22–27) and PET (29, 43) studies have shown that this region is activated by tactile and electric stimulation of the hand, and by electric stimulation of the median nerve. The homologous region in the anterior parietal cortex of monkeys contains four separate representations of the hand, one for each of the four cytoarchitectonic areas (areas 3a, 3b, 1, and 2), forming the postcentral strip (see [44] for a review), but the existence of multiple representations in the human postcentral cortex is at present not clear (see, however, [45]). Bilateral somatosensory activation of a region in the posterior parietal cortex lying posterior and medial to the focus in the anterior parietal cortex has been reported in higher-field functional MR imaging (13, 14), PET (29), and MEG (24, 46) studies in humans. The human posterior parietal cortex may correspond to cytoarchitectonic area 2 (13, 29) or to area 2 and adjacent parts of areas 5 and 7 (25); that is, to regions homologous to those of nonhuman primates containing bilateral-field neurons (47).

Somatosensory activation of the contralateral parietal operculum has been reported in humans with high-field functional MR imaging (13), MEG (20–23, 27), and PET (28–30) studies in the upper bank of the sylvian sulcus in a region corresponding to SII of nonhuman primates (for a review, see [44]). While in nonhuman primates this region contains several somatosensory maps in addition to SII (48, 49; for a review, see [44]), in humans the entire region is still called SII. The present functional MR imaging data show that unilateral hand stimulation activated SII bilaterally. Ipsilateral activation of SII has been reported in previous MEG (20–27, 50) and PET (28, 30) studies, but not in recent PET (29) and functional MR imaging (13) investiga-

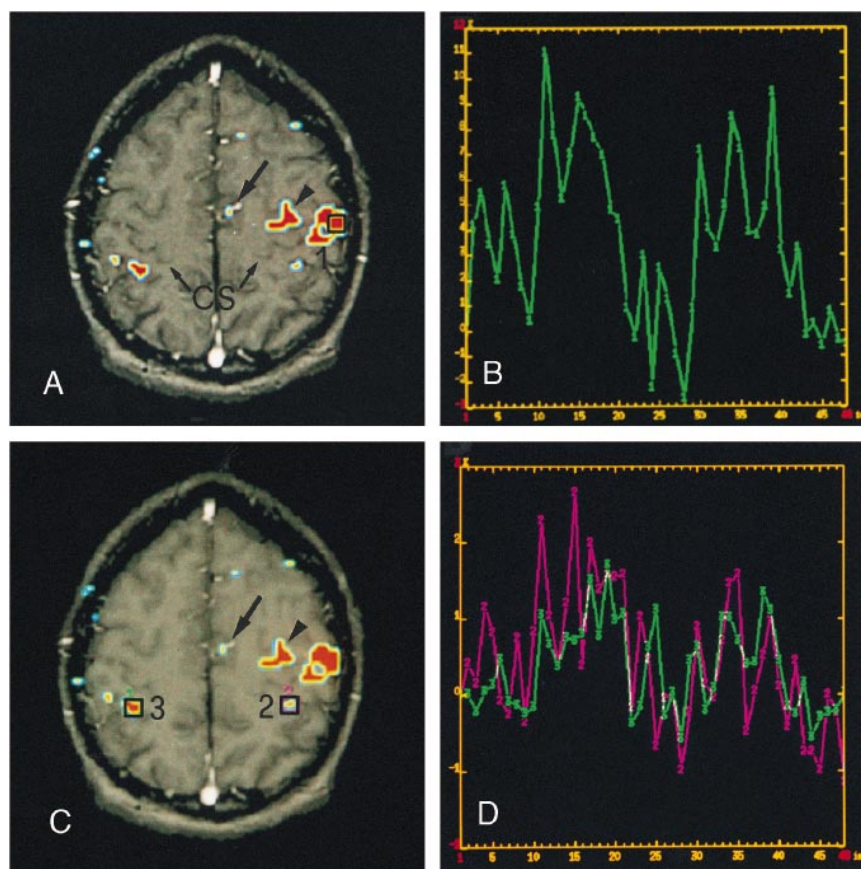


FIG 1. Cortical activation obtained during tactile stimulation of the right hand. Left hemisphere is on the right.

A, Axial image obtained from an SPGR T1-weighted sequence (100/12/1) in which regions activated during tactile stimulation (obtained from a single-shot echo-planar sequence [3000/60/1]) have been superimposed. An ROI was placed on an activated region in the anterior parietal cortex, presumably corresponding to the hand representation of SI (box 1).

B, Graph shows the signal increase in the ROI depicted in A. The x-axis reports the progressive number of images acquired (one image every 3 seconds) and therefore represents a time scale in seconds; the y-axis is a scale on which signal changes are expressed as a percentage of the signal obtained from the brain during the rest periods. Usually, the first value recorded was taken as 0%. In the two 30-second stimulation periods (images 8–18 and 28–38 on the x-axis), the signal increased by about 5% above baseline.

C, Same image as in A. Two ROIs were placed on two activated cortical regions of the posterior parietal cortex, one in the contralateral (box 2) and one in the ipsilateral (box 3) hemisphere.

D, Graphs illustrate the signal increase in the two ROIs shown in C. The signal was lower than in SI (B) and slightly higher in the contralateral (graph 2, purple) than in the ipsilateral (graph 3, green) hemisphere.

Two additional activation foci were apparent in the contralateral hemisphere, one in the medial (A and C, arrows) and the other in the prerolandic (A and C, arrowheads) frontal cortices. CS, central sulcus.

tions. This difference might be due to the stimulus used to activate the skin mechanoreceptors. Rough stimuli moving over the entire hand surface (palm and fingers), as those used in the present study, activate tactile, vibratory, and probably deep receptors. In macaques, this paradigm was shown to be the most effective in firing SII neurons (32–34) and neurons in areas 2 through 5 (31), most of which were endowed with bilateral receptive fields. Brushing the skin has been found to be effective in inducing blood-flow increases in somatosensory areas (12). In previous studies, activation of ipsilateral SII was obtained by strong peripheral stimulation, such as electric shocks to skin or nerves (20–27), strong vibrotactile stimulation of the entire hand (28), or during the active exploration of rough surfaces with the hand (30). Conversely, activation of ipsilateral SII was not observed when a

textured surface was rubbed on a very restricted skin area (one to three fingertips) (13, 29).

In the present study, an activation focus was observed in the medial frontal cortex forming the upper bank of the cingulate sulcus. Activation in a similar location has been reported in previous studies with high-field functional MR imaging (13, 14) and PET (29); this region has been identified as the supplementary motor area (13, 14, 29). The activated region in the prerolandic cortex, just in front of the central sulcus, probably corresponds to the hand (and/or wrist and/or forearm) zone of the motor cortex. Although tactile stimulation was applied passively in the present experiments, the act of holding the hand so as to offer the palm to the experimenter's brushing involves the contraction of the forearm and wrist muscles. Also, the tactile information afferent to the somatosensory cortex is

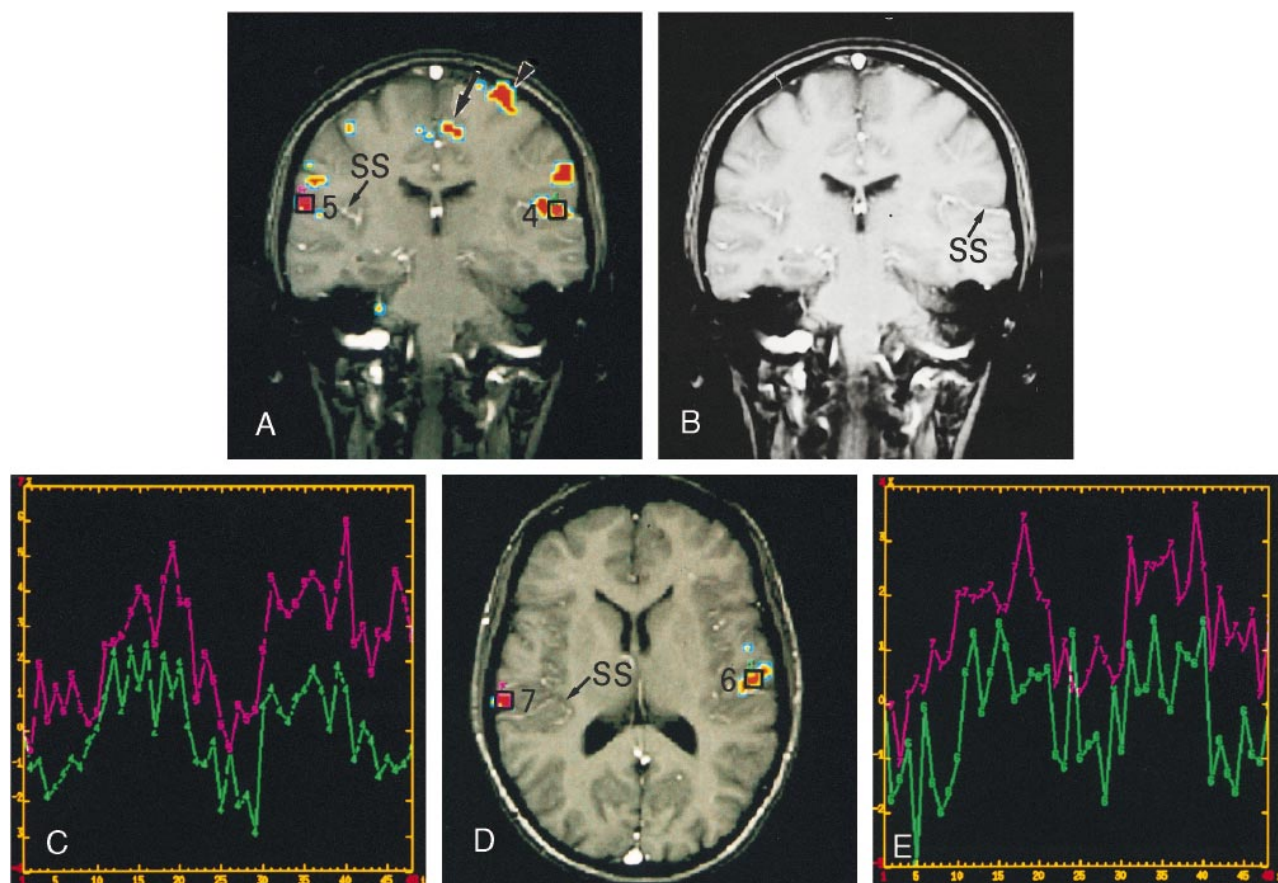


FIG 2. Cortical activation obtained during tactile stimulation of the right hand. Left hemisphere on the right.

A, Coronal image obtained from an SPGR T1-weighted sequence (100/12/1) on which regions activated during tactile stimulation (obtained from a single-shot echo-planar sequence [3000/60/1]) have been superimposed. This image shows activation foci in the parietal operculum of the contralateral (box 4) and ipsilateral (box 5) hemispheres. In each hemisphere the activated region lay in the upper bank of the sylvian sulcus, presumably corresponding to SII.

B, Coronal image (the same shown in A) obtained from an SPGR T1-weighted sequence (100/12/1), without activation foci or ROIs, to show the sylvian sulcus (SS).

C, Graphs show the signal increase in the contralateral (graph 4, green) and ipsilateral (graph 5, purple) activated cortical regions. The x and y axes represent the same scales as described for Figure 1. In the two 30-second stimulation periods, the signal exceeded baseline by 2% to 3%.

D, Axial image, obtained from a subsequent acquisition during the same experimental session, shows the activation foci in the parietal operculum, in a region most likely corresponding to SII. ROIs indicated by boxes 6 and 7 are from contralateral and ipsilateral hemispheres, respectively.

E, Graphs 6 (green) and 7 (purple) show the signal changes in corresponding ROIs 6 and 7 selected in D.

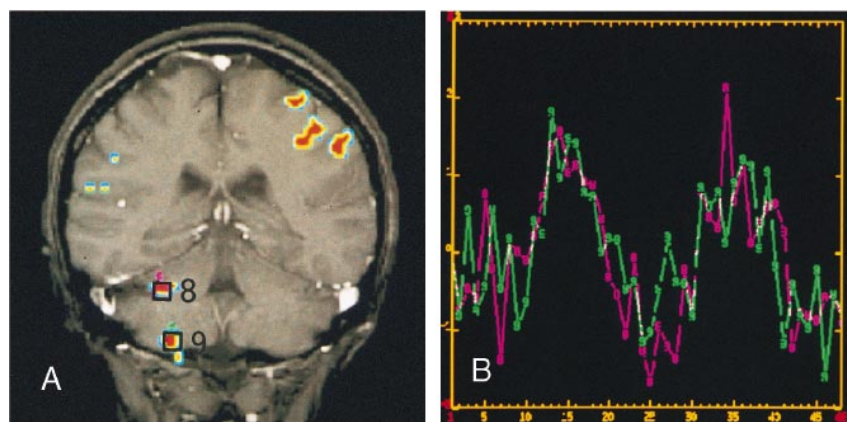


FIG 3. Activation of ipsilateral cerebellar cortex obtained during tactile stimulation of the right hand.

A, Coronal image (SPGR T1-weighted sequence [100/12/1]) shows two activation foci (obtained from a single-shot echo-planar sequence [3000/60/1]) in the ipsilateral cerebellar cortex, on the superior (box 8) and inferior (box 9) surfaces.

B, Graphs 8 (purple) and 9 (green) show the signal changes in the corresponding activated regions of the cerebellar cortex (boxes 8 and 9, respectively). The x and y axes represent the same scales as described for Figure 1.

Subjects studied and activated somatosensory areas

Subject	Sex/Age (y)	Contralateral Hemisphere			Ipsilateral Hemisphere			
		SI	PPC	SII	SI	PPC	SII	CbC
MM*	M/26	Yes	Yes	Yes	No	Yes	Yes	Yes
TM*	M/59	Yes	Yes	Yes	No	Yes	Yes	Yes
MP*	F/21	Yes	Yes	Yes	No	Yes	Yes	Yes
RG	F/21	Yes	Yes	Yes	No	Yes	Yes	Yes
LP	F/22	Yes	Yes	Yes	No	Yes	Yes	Yes
MF*	F/39	Yes	Yes	Yes	No	Yes	Yes	Yes
GP†	M/33	Yes	Yes	Yes	No	Yes	Yes	Yes
AP	F/43	Yes	Yes	Yes	No	Yes	Yes	Yes
AG	M/40	Yes	Yes	Yes	No	Yes	Yes	Yes
MG	F/31	Yes	Yes	Yes	No	Yes	Yes	Yes
AM	M/33	Yes	Yes	Yes	No	Yes	Yes	Yes
ZRL	F/55	Yes	Yes	Yes	No	Yes	Yes	Yes

Note.—SI indicates first somatosensory area; SII, second somatosensory area; PPC, posterior parietal cortex; CbC, cerebellar cortex.

* Underwent the stimulation session twice.

† Underwent the stimulation session three times.

most likely integrated and judged by the subject in view of the possible production of a motor response. These factors may account for the activation observed in the contralateral motor and supplementary motor cortices. An additional hypothesis explaining the activation of these cortices is that they may be reached, more or less directly, by the sensory input from the hand (see [51] for a review). Activation of these areas has previously been reported in functional MR imaging (13) and PET (29) studies in which the subject's skin was stimulated passively.

Finally, two activation foci were observed in the superior and inferior aspects of the intermediate part of the ipsilateral cerebellar hemisphere. These foci appeared to be located in the anterior and posterior lobes, respectively. This finding is consistent with a recent MEG study (52) in which tactile stimulation evoked activity in the cerebellar cortex with the same latency as in the thalamus, suggesting that the afferent somatosensory information carried to the cerebellum directly by spinocerebellar connections is responsible for the activation (53). The source of this evoked activity was in the anterior lobe. Previous results from animal recordings have shown that the ipsilateral cerebellar cortex contains two somatotopic representations of the cutaneous mechanoreceptors of the hand, one in the anterior and one in the posterior lobe, in the intermediate part of the cerebellar hemisphere (for a review, see [53]).

Conclusion

By reproducing the data obtained in previous studies with MEG, PET, and high-field functional MR imaging, the present results support other recent studies on visual and motor systems showing that conventional mid-field functional MR imaging is suitable for mapping cortical areas activated by tactile stimulation. This method allowed us to describe the activation pattern of cortical somatosen-

sory areas during tactile stimulation of the hand and fingers in a group of healthy volunteers. In addition, by adopting a suitable paradigm to activate somatosensory receptors, we report the activation of ipsilateral SII, which was unreported in previous functional MR imaging studies. The possibility that this area may have access to sensory information from the ipsilateral hemibody is in agreement with its functional role, which has been indicated in higher primates, including humans, to be a crucial station in the cortical processing of somatosensory information (54–56) and in the interhemispheric transfer of tactile learning and retention (57, 58).

Acknowledgments

We are grateful to Hubert Léjay, Paola Scifo, and Guillermo Zannoli (GE Medical Systems) for invaluable technical advice, and to Silvia Modena for editorial assistance.

References

1. Le Bihan D, Karni A. **Application of magnetic resonance imaging to the study of human brain function.** *Curr Opin Neurobiol* 1995; 5:231–237
2. Kollias SS, Valavanis A, Golay XG, Bösigler P, McKinnon G. **Functional magnetic resonance imaging of cortical activation.** *Int J Neuro-radiol* 1996;2:450–472
3. Stippich C, Freitag P, Kassubek J, et al. **Motor, somatosensory and auditory cortex localization by fMRI and MEG.** *Neuroreport* 1998; 9:1953–1957
4. Puce A. **Comparative assessment of sensorimotor function using functional magnetic resonance imaging and electrophysiological methods.** *J Clin Neurophysiol* 1995;12:450–459
5. Roberts TPL, Rowley HA. **Mapping of the sensorimotor cortex: functional MR and magnetic source imaging.** *AJNR Am J Neuro-radiol* 1997;18:871–880
6. Disbrow E, Buonocore M, Antognini J, Carstens E, Rowley HA. **Somatosensory cortex: a comparison of the response to noxious thermal, mechanical, and electrical stimuli using functional magnetic resonance imaging.** *Hum Brain Mapping* 1998;6:150–159
7. Grimm C, Schreiber M, Kristeva-Feige R, Mergner T, Hennig J, Lucking CH. **A comparison between electric source localisation and fMRI during somatosensory stimulation.** *Electroencephalogr Clin Neurophysiol* 1998;106:22–29
8. Hammeke TA, Yetkin FZ, Mueller WM, et al. **Functional magnetic resonance imaging of somatosensory stimulation.** *Neurosurgery* 1994;35:677–681

9. Rumeau C, Tzourio N, Murayama N, et al. **Location of hand function in the sensorimotor cortex: MR and functional correlation.** *AJNR Am J Neuroradiol* 1994;15:567-572
10. Shimizu H, Nakasato N, Mizoi K, Yoshimoto T. **Localization of the central sulcus by functional magnetic resonance imaging and magnetoencephalography.** *Clin Neurol Neurosurg* 1997;99:235-238
11. Sakai K, Watanabe E, Onodera Y, et al. **Functional mapping of the human somatosensory cortex with echo-planar MRI.** *Magn Reson Med* 1995;33:736-743
12. Puce A, Constable RT, Luby ML, et al. **Functional magnetic resonance imaging of sensory and motor cortex: comparison with electrophysiological localization.** *J Neurosurg* 1995;83:262-270
13. Lin W, Kuppusamy K, Haacke EM, Burton H. **Functional MRI in human somatosensory cortex activated by touching textured surfaces.** *J Magn Reson Imaging* 1996;6:565-572
14. Boecker H, Khorram-Sefat D, Kleinschmidt A, et al. **High-resolution functional magnetic resonance imaging of cortical activation during tactile exploration.** *Hum Brain Mapping* 1995;3:236-244
15. Lüders H, Lesser R, Dinner DS, Hahn JF, Salanga V, Morris HH. **The second sensory area in humans: evoked potentials and electrical stimulation studies.** *Ann Neurol* 1985;17:177-184
16. Allison T, McCarthy G, Wood CC, Williamson PD, Spencer DD. **Human cortical potentials evoked by stimulation of median nerve, II: cytoarchitectonic areas generating long-latency activity.** *J Neurophysiol* 1989;62:711-722
17. Hämäläinen H, Kekoni J, Samn M, Reinikainen K, Näätänen R. **Human somatosensory evoked potentials to mechanical pulses and vibration: contribution of SI and SII somatosensory cortices P50 and P100 components.** *Electroencephalogr Clin Neurophysiol* 1990;75:13-21
18. Kany C, Treede RD. **Median and tibial nerve somatosensory evoked potentials: middle-latency components from the vicinity of the secondary somatosensory cortex in humans.** *Electroencephalogr Clin Neurophysiol* 1997;104:402-410
19. Mima T, Ikeda A, Nagamine T, et al. **Human second somatosensory area: subdural and magnetoencephalography recording of somatosensory evoked responses.** *J Neurol Neurosurg Psychiatry* 1997;63:501-505
20. Hari R, Hämäläinen M, Kaukoranta E, Reinikainen K, Teszner D. **Neuromagnetic responses from the second somatosensory cortex in man.** *Acta Neurol Scand* 1983;68:207-212
21. Hari R, Hämäläinen H, Hämäläinen M, Kekoni J, Sams M, Tiihonen J. **Separate finger representations at the human second somatosensory cortex.** *Neuroscience* 1990;37:245-249
22. Hari R, Karhu J, Hämäläinen M, Salonen O, Sams M, Vilkmann V. **Functional organization of the first and second somatosensory cortices: a neuromagnetic study.** *Eur J Neurosci* 1993;5:724-734
23. Kaukoranta E, Hari R, Hämäläinen M, Huttunen J. **Cerebral magnetic fields evoked by peroneal nerve stimulation.** *Somatosens Res* 1986;3:309-321
24. Forss N, Hari R, Salmelin R, et al. **Activation of the human posterior parietal cortex by median nerve stimulation.** *Exp Brain Res* 1994a;99:309-315
25. Forss N, Salmelin R, Hari R. **Comparison of somatosensory evoked fields to airpuff and electric stimuli.** *Electroencephalogr Clin Neurophysiol* 1994b;92:510-517
26. Hoshiyama M, Kakigi R, Koyama S, Watanabe S, Shimojo M. **Activity in the posterior parietal cortex following somatosensory stimulation in man: magnetoencephalographic study using spatio-temporal source analysis.** *Brain Topogr* 1997;10:23-30
27. Forss N, Jousmäki V. **Sensorimotor integration in human primary and secondary somatosensory cortices.** *Brain Res* 1998;781:259-267
28. Burton H, Videen TO, Raichle ME. **Tactile-vibration-activated foci in insular and parietal-opercular cortex studied with positron emission tomography: mapping the second somatosensory areas in humans.** *Somatosens Mot Res* 1993;10:297-308
29. Burton H, MacLeod AMK, Videen TO, Raichle ME. **Multiple foci in parietal and frontal cortex by rubbing embossed grating pattern across fingerpads: a positron emission tomography study in humans.** *Cerebral Cortex* 1997;7:3-17
30. Ledberg A, Brennan T, O'Sullivan T, Kinomura S, Roland PE. **Somatosensory activations of the parietal operculum of man: a PET study.** *Eur J Neurosci* 1995;7:1934-1941
31. Iwamura Y, Tanaka M, Sakamoto M, Hikosaka O. **Functional surface integration, submodality convergence, and tactile feature detection in area 2 of the monkey somatosensory cortex.** *Exp Brain Res Suppl* 1985;10:44-58
32. Whitsel BL, Petrucci LM, Werner G. **Symmetry and connectivity in the map of the body surface in somatosensory area II of primates.** *J Neurophysiol* 1969;32:170-183
33. Robinson CJ, Burton H. **Somatic submodality distribution within the second somatosensory (SII), 7b, retroinsular, postauditory, and granular insular cortical areas of M. fascicularis.** *J Comp Neurol* 1980;192:93-108
34. Manzoni T, Barbaresi P, Conti F. **Callosal mechanism for the inter-hemispheric transfer of hand somatosensory information in the monkey.** *Behav Brain Res* 1984;11:155-170
35. Wirestam R, Bolling M, Rudling O, et al. **Functional magnetic resonance imaging using photic and motor stimulation: comparison of results obtained at 1.0 T and 1.5 T.** In: Pavone P, Rossi P, eds. *Syllabus fMRI*. Milan: Springer-Italia; 1996:45-48
36. Lundervold A, Ersland L, Gjesdal K-I, et al. **Functional magnetic resonance imaging of primary visual processing using a 1.0 tesla scanner.** *Int J Neurosci* 1995;81:151-168
37. Van der Kallen BF, Erning LJ, Van Zuijlen MW, Merx H, Thijssen HO. **Activation of the sensorimotor cortex at 1.0 T: comparison of echo-planar and gradient-echo imaging.** *AJNR Am J Neuroradiol* 1998;19:1099-1104
38. Oldfield RC. **The assessment and analysis of handedness: the Edinburgh inventory.** *Neuropsychologia* 1971;9:97-113
39. Yeztkin FZ, Haughton VM, Coc RW, et al. **Effect of motion outside the field of view on functional MR.** *AJNR Am J Neuroradiol* 1996;17:1005-1009
40. Kim S-G, Urgubil K. **Functional magnetic resonance imaging of the human brain.** *J Neurosci Methods* 1997;74:229-243
41. Xiong J, Gao J-H, Lancaster JL, Fox P. **Assessment and optimization of functional MRI analyses.** *Hum Brain Mapping* 1996;4:153-167
42. Duvernoy HM. *The Human Brain*. Wien: Springer; 1991:1-354
43. Fox PT, Burton H, Raichle ME. **Mapping human somatosensory cortex with positron emission tomography.** *J Neurosurg* 1987;67:34-43
44. Manzoni T. **The callosal connections of the hierarchically organized somatosensory areas of primates.** *J Neurosurg Sci* 1997;41:1-22
45. Gelnar PA, Krauss BR, Szeverenyi NM, Apkarian AV. **Fingertip representation in the human somatosensory cortex: an fMRI study.** *Neuroimage* 1998;7:261-283
46. Schnitzler A, Salmelin R, Salenius S, Jousmäki V, Hari R. **Tactile information from the human hand reaches the ipsilateral primary somatosensory cortex.** *Neurosci Lett* 1995;200:25-28
47. Iwamura Y, Iriki A, Tanaka M. **Bilateral hand representation in the postcentral somato-sensory cortex.** *Nature* 1994;369:554-556
48. Burton H, Fabri M, Alloway K. **Cortical areas within the lateral sulcus connected to cutaneous representations in areas 3b and 1: a revised interpretation of the second somatosensory area in macaque monkeys.** *J Comp Neurol* 1995;355:539-562
49. Krubitzer L, Clarey J, Tweedale R, Elston G, Calford M. **A redefinition of somatosensory areas in the lateral sulcus of macaque monkeys.** *J Neurosci* 1995;15:3821-3839
50. Huttunen J, Wikström H, Korvenoja A, Seppäläinen A-M, Aronen H, Ilmoniemi R. **Significance of the second somatosensory cortex in sensorimotor integration: enhancement of sensory responses during finger movements.** *Neuroreport* 1996;7:1009-1012
51. Uematsu S, Lesser RP, Gordon B. **Localization of sensorimotor cortex: the influence of Sherrington and Cushing on the modern concept.** *Neurosurgery* 1992;30:904-913
52. Tesche CD, Karhu J. **Somatosensory evoked magnetic fields arising from sources in the human cerebellum.** *Brain Res* 1997;744:23-31
53. Bloedel JR, Courville J. **A review of cerebellar afferent system.** In: Brooks VB, ed. *Handbook of Physiology: Motor Control*. Baltimore: William & Wilkins; 1981:735-830
54. Mishkin M. **Analogous neural models for tactual and visual learning.** *Neuropsychologia* 1979;17:139-151
55. Murray E, Mishkin M. **Relative contributions of SII and area 5 to tactile discrimination in monkeys.** *Behav Brain Res* 1984;11:67-83
56. Greenspan JD, Winfield JA. **Reversible pain and tactile deficits associated with a cerebral tumor compressing the posterior insula and parietal operculum.** *Pain* 1992;50:29-39
57. Garcha HS, Ettlinger G. **Tactile discrimination learning in the monkey: the effects of unilateral or bilateral removals of the second somatosensory cortex (area SII).** *Cortex* 1980;16:397-412
58. Garcha HS, Ettlinger G, Maccabe JJ. **Unilateral removal of the second somatosensory projection cortex in the monkey: evidence for cerebral predominance?** *Brain* 1982;105:787-810