



## Discover Generics

Cost-Effective CT & MRI Contrast Agents

 FRESENIUS  
KABI

[WATCH VIDEO](#)

# AJNR

## Reversible enlargement of cerebral spinal fluid spaces in chronic alcoholics.

H Artmann, M V Gall, H Hacker and J Herrlich

*AJNR Am J Neuroradiol* 1981, 2 (1) 23-27

<http://www.ajnr.org/content/2/1/23>

This information is current as  
of June 18, 2025.

# Reversible Enlargement of Cerebral Spinal Fluid Spaces in Chronic Alcoholics

H. Artmann<sup>1</sup>  
M. V. Gall<sup>2</sup>  
H. Hacker<sup>1</sup>  
J. Herrlich<sup>2</sup>

Repeat computed tomography (CT) and clinical examinations, including psychologic tests, were performed in 15 chronic alcoholics. In nine controlled abstinent patients, marked decrease of cerebrospinal fluid space enlargement was visible on CT, corresponding with clinical improvement. A second CT examination after 1 year showed continued improvement in three successfully treated patients. The recovery of cortical and ventricular enlargements was encountered with equal frequency, although the more striking change was in the cortex. Possible underlying pathogenetic processes were considered.

The pathologic and neuroradiologic literature contain numerous reports of chronic alcoholism leading to extensive brain atrophy [1-3]. However, data interpretation is incomplete since age group differences, validity of atrophy categorization, and other clinical factors must be considered.

Recent computed tomography (CT) studies have shown pronounced cortical and subcortical atrophy in 33%-96% of alcoholics [4-9]. In our study of 15 chronic alcoholics, we initially assumed that brain atrophy would be progressive. We were surprised to find a decreasing amount of brain "atrophy" on repeated CT examinations in most of our patients.

## Subjects and Methods

Of a nonselected group of 60 chronic alcoholics originally examined, 15 participated in the study. The study comprised 13 men and two women, 29-64 years old (mean 41.6 years). There was a known history of alcoholism in 14 cases of 5-23 years. All patients were admitted either because of neurologic or psychiatric complications of the disease: delirium tremens (eight cases); Korsakoff-Wernicke syndrome (one case); seizures, not always epileptic (three cases); polyneuropathy and ataxia together with other psychiatric syndromes (three cases).

All patients were scanned with the same CT unit (Siretom 1; 128 × 128 matrix). Clinical examination and CT scan were repeated after more than 1 year (13-22 months). In four patients, a third scan was obtained 9-14 months later. Cortical and ventricular atrophy were classified after visual evaluation using the following criteria (described in a previous report [7]): *cortical atrophy*—slight (some sulci are significantly enlarged), moderate (more than one lobe exhibits enlarged sulci), pronounced to severe (diffuse and extended enlarged sulci over the entire cortex); *ventricular atrophy*—slight (mild enlargement of ventricles), moderate (distinct ventricular widening), pronounced to severe (ventricular system, all compartments, considerably enlarged).

Additional measurements of ventricular size were obtained in the following manner. According to Huckman et al. [10], the distances between the most lateral part of each of the frontal horns and the width of the lateral ventricles in the region of the caudate nuclei were measured and the two distances were added together. Measurements were made in millimeters directly from Polaroid photographs without correcting for magnification as described by Huckman et al. Since we used only hard copies for evaluation we could not exclude possible changes in the magnification factor. In 14 patients, the Wechsler Adult

Received July 3, 1980; accepted after revision September 19, 1980.

<sup>1</sup>Department of Radiology, Section of Neuro-radiology, University Clinics, J. W. Goethe University, Schleusenweg 2-16, D 6000 Frankfurt/Main 71, Federal Republic of Germany. Address reprint requests to H. Artmann.

<sup>2</sup>Department of Psychiatry, University Clinics, J. W. Goethe University, Frankfurt/Main, Federal Republic of Germany.

**AJNR 2:23-27, January/February 1981**  
0195-6108/81/0021-0023 \$00.00  
© American Roentgen Ray Society

TABLE 1: CT, Clinical, and Psychological Reexamination Findings

Case No.	Gender, Age (yrs)	Duration of Alcoholism (yrs)	Admission Findings	Abstinence (mo)	IQ/Benton* test	CT Improvement†	
						Cortex	Ventricles
1	M, 29	5	Korsakoff-Wernicke Syndrome	20	101/-2	+	++
2	M, 46	7	Delirium	16	106/-1	+	++
3	F, 38	15	Delirium	18	95/-3	++	+
4	M, 40	23	Delirium	12	111/0	0	+
5	F, 40	16	Delirium	18	82/-3	++	++
6	M, 53	11	Delirium	14	121/-3	++	++
7	M, 40	25	Seizures	9	100/0	++	0
8	M, 38	17	Acute intoxication	9	89/0	0	+
9	M, 30	15	Seizures	6	97/-3	+	0
10	M, 36	10	Delirium	14	103/-1	0	0
11	M, 29	6	Acute intoxication	3	94/-2	0	0
12	M, 64	18	Delirium	0	91/-1	0	0
13	M, 47	11	Delirium	0	82/0	0	0
14	M, 44	18	Ataxia	0	106/-4	0	0
15	M, 42	?	Seizures	0	Not performed	0	0

\* Benton values correspond to expectation values relative to IQ test. 0 coincides with given IQ; -1--3 coincide with degrees below expectation value.

† 0 = no change; + = slight change; ++ = pronounced change.

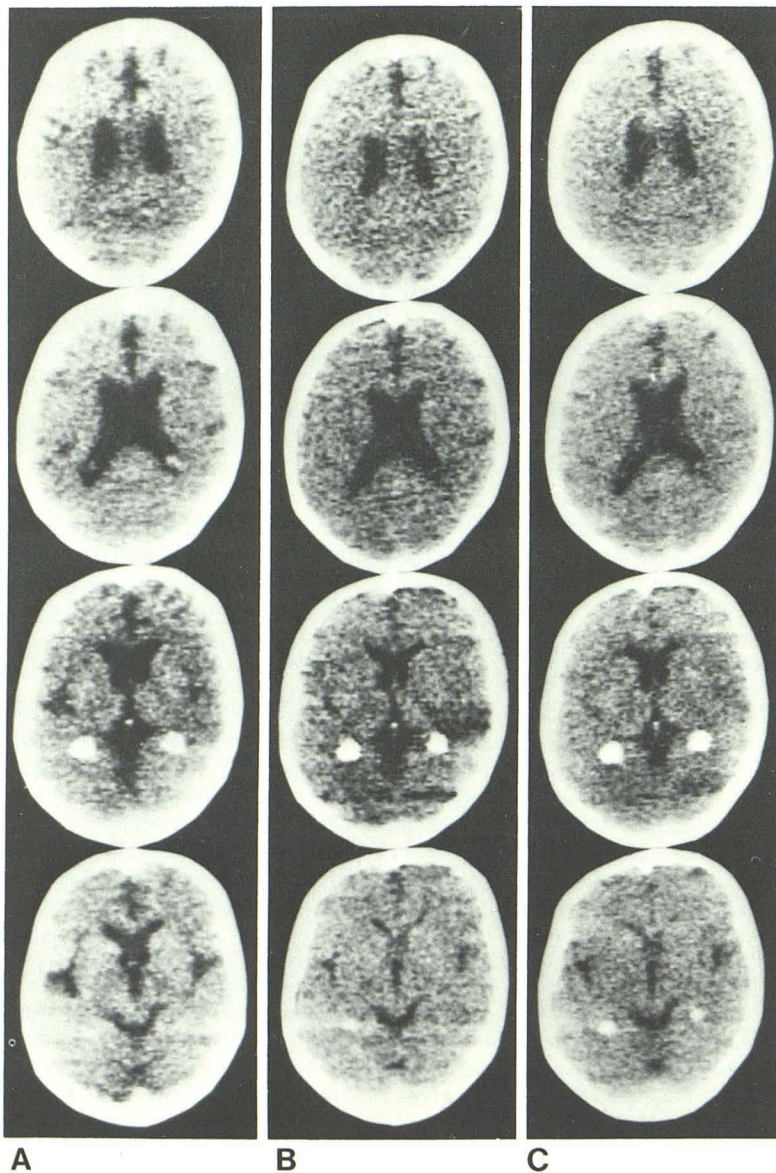


Fig. 1.—Case 2, 46-year-old man. Slightly diminished ventricle and cortical sulci width after 15 (B) and 28 (C) months of abstinence.



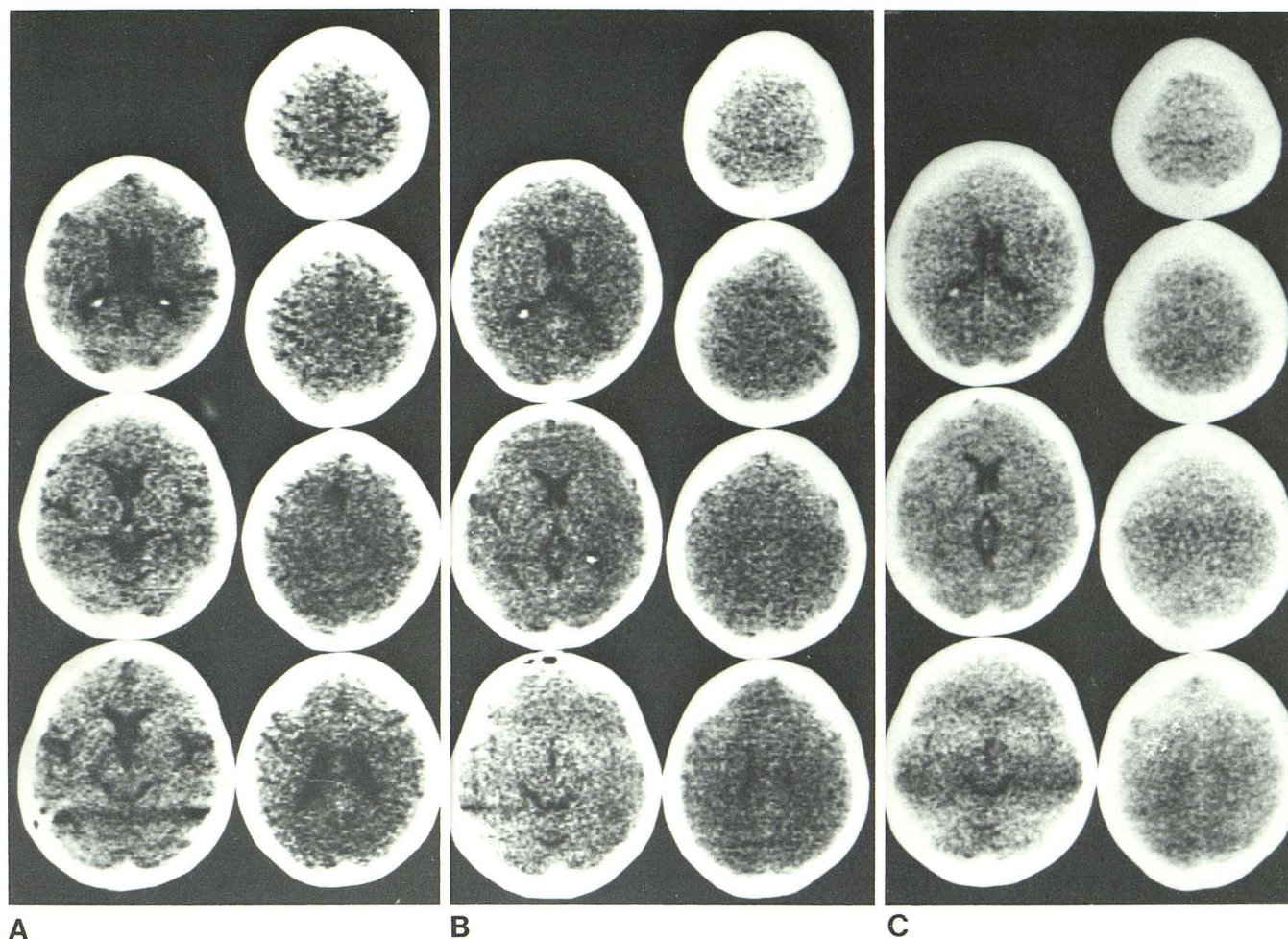


Fig. 2.—Case 5, 40-year-old woman. Reversal of moderate widening of cortical sulci and ventricle width after 16 (B) and 27 (C) months of controlled abstinence.

Intelligence Scale, using a reduced IQ scale for clinical purposes [11], and the Benton test [12] were also used.

## Results

On the first CT examination, 14 patients revealed signs of cortical atrophy and 10 showed ventricular widening. After the first CT examination, nine of 15 patients had inpatient treatment with alcohol abstinence of 9–20 months. Of the six who were not treated, two were abstinent and four were not. On CT reexamination, nine patients evidenced slight or pronounced decrease of sulcal and/or ventricular width.

In two of the four patients who had three examinations, there were no further changes in CT findings between the second and third scans. In a third patient, the third scan showed a slight increase of sulci width without corresponding alcohol intake. However, the diminished cisternal and ventricular width was unchanged.

The psychological results after reexamination were assessed. There was no direct correlation between higher intelligence rates and the most pronounced CT improvement, although lower IQs prevailed in the nonabstinent group. The Benton test indicated a reduced visuomotor

coordination in 11 cases (73%), including most of the abstinent group. We agree with other authors [3, 6, 13] that the correlation of neuroradiologic and psychologic data provides the best estimate of brain pathology.

Seemingly, reexamination of cortical sulci and cisterns is inherently imprecise, since it is impossible to duplicate slice projections in follow-up scans. Nevertheless enlargement of cortical sulci was evaluated with one set of criteria by a single researcher who remained unaware of clinical results. Further, visual evaluation has the advantage over direct measurement in that, together with a regional accentuation of changes, a complete assessment of changes of all cerebrospinal fluid spaces is possible.

By contrast, ventricular measurement can be proved statistically. We used the Wilcoxon test. With a mean value difference of 0.9 mm for the sums of the two distances, maximal width of frontal horns and intercaudate span, the Wilcoxon test showed a significant decrease between the first and second scan ( $p < 0.01$ ).

Table 1 lists the changes in cerebrospinal fluid spaces relative to clinical data. Cortical and ventricular changes occurred with similar frequency; the most dramatic improvement was seen in cortical "atrophy." Reversible brain "atro-



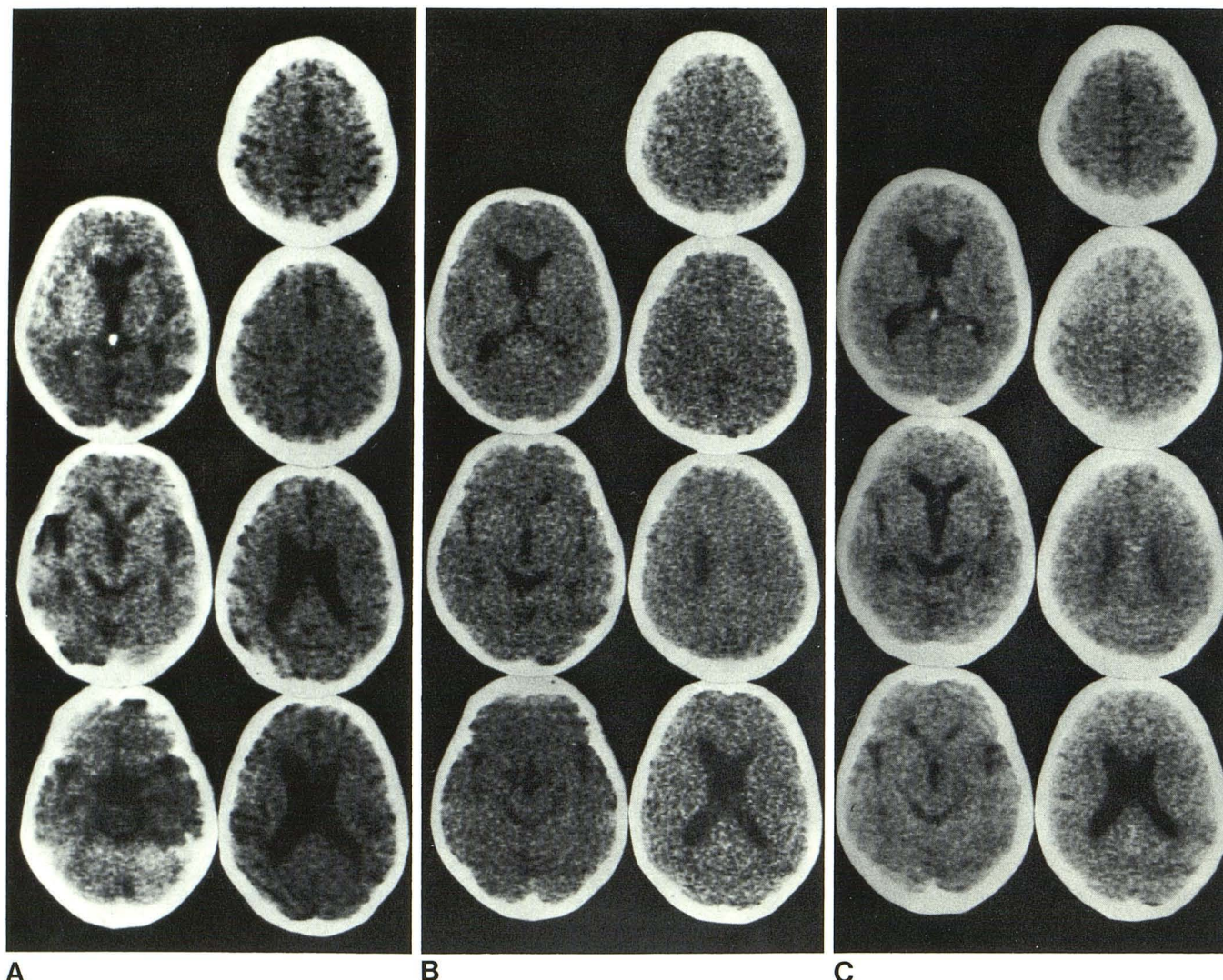


Fig. 3.—Case 6, 53-year-old man. Reversal of generalized and pronounced enlargement of cortical sulci and ventricles. There was abstinence of at least 14 months during the 15 months between the first (A) and second (B) scans. Although abstinence continued, a third scan 9 months later (C) showed a slight increase in sulcal width.

phy'' in our material seemed to correspond clearly to the duration of abstinence. There was a notable lack of significant increase in atrophy, especially in the four patients who continued to drink. This finding is probably atypical; often, heavy drinkers are unavailable for follow-up because of insufficient motivation and transient lifestyle. Of 60 former patients, 45 did not respond to our call for reexamination and could not be included in our results.

### Representative Case Reports

#### Case 1

A 29-year-old man had Korsakoff-Wernicke syndrome after 5 years of heavy drinking. Initial CT showed slight widening of frontoparietal cortical sulci and sylvian fissures. After 20 consecutive months of inpatient treatment, he showed recovery of psychopathologic symptoms and reversed CT findings.

#### Case 2

A 46-year-old man had a history of 10 years addiction and increasing social decline and isolation. At his first admission, he showed signs of delirium, psychopathologic deprivation, emotional lability, and liver damage on laboratory tests. After 16 months of withdrawal treatment, he had no physical or psychological symptoms. He reached an IQ level of 106 points and was emotionally stabilized. He was still abstinent after 1 year and was reinstated in his former profession.

Reexamination 15 and 28 months after first CT scan showed a slight decrease in ventricle width and of widened sulci, interhemispheric fissure, and sylvian fissures (fig. 1).

#### Case 5

A 40-year-old woman had a 16 year history of drinking with five occasions of delirium tremens. When first examined by us, she had polyneuropathy, liver cirrhosis, and signs of psychopathologic de-



privation. After 18 months of controlled abstinence with withdrawal treatment, she was physically and psychologically improved although her IQ measured only 82 points and 3 degrees below the Benton test expectation value. CT reexaminations 16 and 27 months after initial study showed a decrease of initially moderate widening of cortical sulci and ventricle width (fig. 2).

#### Case 6

A 53-year-old man had a history of excessive drinking of more than 10 years, during which he reached a reduced mental state and beginning dementia. Neurologically he showed a marked tremor and a slight polyneuropathy. Because his thinking was incoherent, no detailed test could be performed. There was also marked emotional lability. Laboratory examinations showed signs of liver damage. After a short withdrawal treatment for delirium, he stopped drinking by self-motivation. At 15 months after first examination, he had no tremor and almost normalized body habit. His IQ scale reached 121 points and he was cooperative and attentive. When he was evaluated again 9 months later he had no recurrence of drinking and showed no neurologic or psychiatric symptoms.

This case shows that self-motivation can be effective to control abstinence even after several treatment failures. CT showed a considerable decrease in both cortical and subcortical atrophic signs during a 30 month period (fig. 3). A third scan 9 months later showed a slightly diminished sulcal width and unchanged cisternal and ventricular size.

#### Discussion

When we prepared this paper, there was only one report of reversible cerebral "atrophy" in alcoholics. Carlen et al. [14] found improvement in four of eight cases also related to controlled abstinence. Meanwhile the concept of *reversible atrophy* has often been criticized, since little is known about the underlying mechanism in those cases. Similar existence of reversible cerebrospinal fluid space enlargement was found in some cases of anorexia nervosa as well as in Cushing syndrome [15, 16]. It is still uncertain whether dehydration together with decreasing serum albumin due to malnutrition or true neuronal regenerative processes are responsible. Alcoholism must be regarded as a complex disease, in which chronically undernourished patients are typical. Carlen et al. [14] saw reversible cerebrospinal fluid space changes starting not earlier than 4–7 weeks after hospital admission. They used this as an argument for the regeneration theory, because if normal nutrition were the

decisive factor, the changes probably would be manifest within 2–3 weeks of hospital-controlled normal nourishment.

#### REFERENCES

1. Dreyfus PM. Diseases of the nervous system in chronic alcoholics. In: Kissin B, Begleiter H, eds. *The biology of alcoholism*, vol. 3: *Clinical pathology*. New York: Plenum, 1974:265–290
2. Haug JO. Pneumoencephalographic evidence of brain damage in chronic alcoholics. *Acta Psychiatr Scand [Suppl]* 1968;203:135–143
3. Brewer C, Perrett L. Brain damage due to alcohol consumption: an air-encephalographic, psychometric and electroencephalographic study. *Br J Addict* 1971;66:170–182
4. Fox JH, Ramsey RG, Huckman MS, Proske AE. Cerebral ventricular enlargement. Chronic alcoholics examined by computerized tomography. *JAMA* 1976;16:365–368
5. Epstein PS, Pisani VD, Fawcett JA. Alcoholism and cerebral atrophy. *Alcoholism* 1977;1:61–65
6. Cala LA, Jones B, Mastaglia FL, Wiley B. Brain atrophy and intellectual impairment in heavy drinkers: a clinical, psychometric and computerized tomography study. *Aust NZ J Med* 1978;8:147–153
7. Gall Mv, Becker H, Artmann H, Lerch G, Nemeth N. Results of computer tomography on chronic alcoholics. *Neuroradiology* 1978;16:329–331
8. Newman SE. The EEG manifestations of chronic ethanol abuse: relation to cortical atrophy. *Ann Neurol* 1978;3:299–304
9. Götze P, Kühne D, Hansen J, Knipp HP. Hirnatrophische Veränderungen bei chronischem Alkoholismus. *Arch Psychiatr Nervenkr* 1978;226:137–156
10. Huckman MS, Fox JH, Topel J. The validity of criteria for the evaluation of cerebral atrophy by computed tomography. *Radiology* 1975;116:85–92
11. Dahl G. *WIP. Reduzierter Wechsler-Intelligenztest*. Meisenheim am Glan: Anton Hain, 1972
12. Benton AL. *Der Benton-Test*. Handbuch. Bern: Hans Huber, 1961
13. Hill SY, Mikhael M. Computed tomography scans of alcoholics: cerebral atrophy? *Science* 1979;204:1237–1238
14. Carlen PL, Wortzman G, Holgate RC, Wilkinson DA, Rankin JG. Reversible cerebral atrophy in recently abstinent chronic alcoholics measured by computed tomography scans. *Science* 1978;200:1076–1078
15. Enzmann DR, Lane B. Cranial computed tomography findings in anorexia nervosa. *J Comput Assist Tomogr* 1977;1:410–414
16. Heinz ER, Martinez J, Haenggeli A. Reversibility of cerebral atrophy in anorexia nervosa and Cushing's syndrome. *J Comput Assist Tomogr* 1977;1:415–418