



Discover Generics

Cost-Effective CT & MRI Contrast Agents



WATCH VIDEO

AJNR

Isolated unilateral hypoglossal neuropathy caused by dural arteriovenous fistula.

M H Blomquist, J D Barr and R W Hurst

AJNR Am J Neuroradiol 1998, 19 (5) 951-953

<http://www.ajnr.org/content/19/5/951>

This information is current as
of June 10, 2025.

Isolated Unilateral Hypoglossal Neuropathy Caused by Dural Arteriovenous Fistula

M. H. Blomquist, J. D. Barr, and R. W. Hurst

Summary: We report a case of isolated hypoglossal nerve paralysis caused by a dural arteriovenous fistula. Diagnosis is discussed with emphasis on conventional and MR angiography. The anatomy of the hypoglossal nerve is reviewed along with more common causes of pathologic conditions.

Isolated hypoglossal nerve paralysis is an uncommon cranial nerve palsy. More commonly, the hypoglossal nerve is involved along with the glossopharyngeal, vagus, and spinal accessory nerves within the nearby jugular foramen. We describe a patient with an isolated hypoglossal nerve palsy caused by an arteriovenous fistula located at the right paramedian skull base.

Case Report

A 43-year-old woman had rhinitis, odynophagia, and constant deep pressure-type cephalgia of the right frontal, temporal, and posterior auricular areas. She also reported right-sided pulsatile tinnitus. She was treated by her primary care physician for a presumed upper respiratory infection. After three courses of antibiotics without improvement, she was referred to an otolaryngologist, who noted right-sided tongue deviation. The patient was then referred for admission to the neurology service. Physical and neurologic examinations were remarkable only for an isolated right 12th cranial nerve palsy. The headaches and right-sided pulsatile tinnitus were still present. The patient's medical history was significant only for hypertension and preeclampsia with a prior pregnancy. Her only medication at the time of admission was lisinopril, an angiotensin-converting enzyme inhibitor. Routine laboratory evaluation was unremarkable.

Sonographic examination of the cervical carotid arteries and cranial MR studies were unremarkable. MR angiography (Fig 1A) revealed a poorly defined hypervascularity superior and lateral to the right side of the foramen magnum, which was suggestive of a dural arteriovenous fistula (DAVF). Conventional angiography (Fig 1B and C) confirmed a DAVF supplied by both the ascending pharyngeal and the right posterior auricular arteries. Venous drainage passed predominantly into the epidural venous plexus.

Endovascular therapy was discussed with the patient, who elected to seek a second opinion before undergoing treatment. Then, approximately 24 hours after the diagnostic arteriography, she experienced a sudden decrease in the headache and

pulsatile tinnitus. Three days after the first arteriography, a second angiogram was obtained, which revealed complete interval thrombosis of the DAVF. The patient's cranial nerve palsy has slowly improved, and her headache and pulsatile tinnitus have not recurred.

Discussion

The hypoglossal nerve is a pure motor nerve that supplies primarily the intrinsic and extrinsic muscles of the tongue. The nucleus of the nerve has a bulbar and spinal extension. The bulbar nuclei lie in a paramedian location in the floor of the fourth ventricle. The fibers exit between the inferior olivary nucleus and the corticospinal tract of the pyramid. In the medullary cistern, these fibers fuse to form the hypoglossal nerve. The nerve has a short cisternal segment directed anterolaterally and inferiorly; it then enters the hypoglossal canal (anterior condylar foramen) of the occipital bone. The canal lies posteromedial and inferior to the jugular foramen (1). The nerve then courses anteriorly and inferiorly between the internal carotid artery and the internal jugular vein, and finally extends anteriorly and cephalad into the tongue. The nerve is joined by filaments from spinal nerve C-1, which then exit to form the superior root of the ansa cervicalis (2).

Unilateral hypoglossal neuropathy is an uncommon entity and its dysfunction can be attributed to specific abnormalities at the supranuclear, nuclear, and infranuclear levels (3). Thompson and Smoker (4) have reported an anatomic scheme for imaging assessment of hypoglossal neuropathy based on the medullary, cisternal, skull base, nasopharyngeal/oropharyngeal carotid space, and sublingual segments of the 12th cranial nerve. Specifically, the following pathologic conditions have been described within each of the aforementioned segments:

Medullary segment: glioma, demyelination, infarction, hemorrhage, or less common entities, such as syringobulbia (5), poliomyelitis, botulism, amyotrophic lateral sclerosis (6), and infectious mononucleosis (7).

Cisternal segment: aneurysm and basilar artery ec-

Received May 13, 1997; accepted after revision August 19.

From the Department of Radiology, Penn State University, Milton S. Hershey Medical Center, Hershey (M.H.B., J.D.B.); and the Department of Radiology, Hospital of the University of Pennsylvania, Philadelphia (R.W.H.).

Address reprint requests to John D. Barr, MD, Department of Radiology, P.O. Box 850, Penn State University, Milton S. Hershey Medical Center, Hershey, PA 17033.

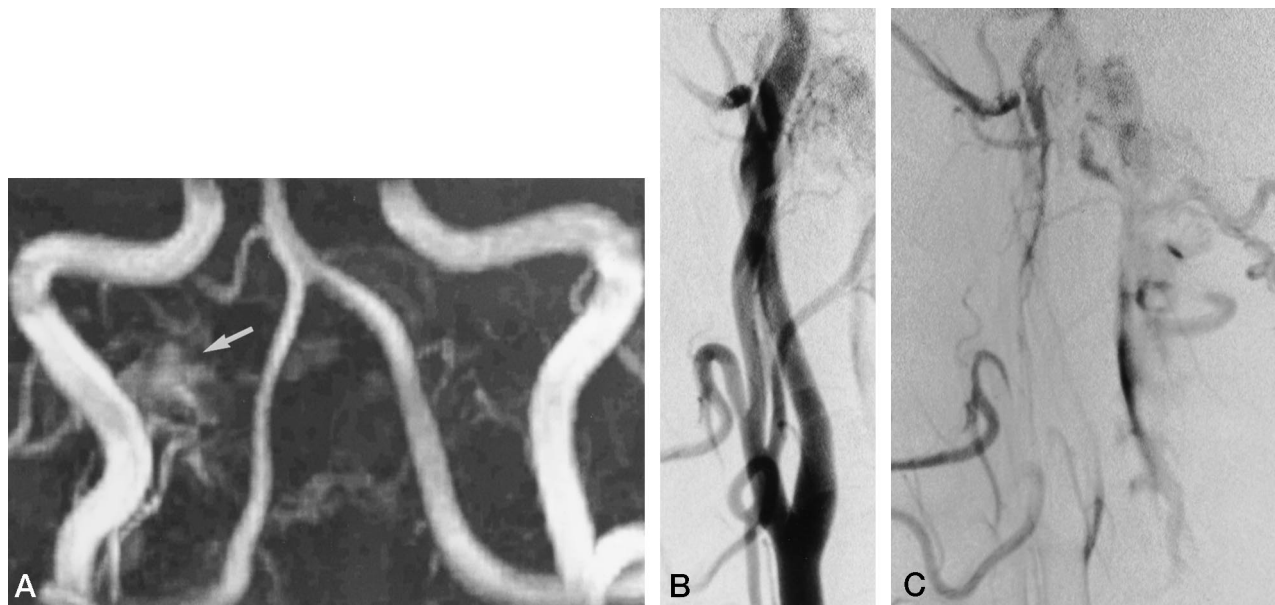


FIG 1. 43-year-old woman with headache and right-sided pulsatile tinnitus.

A–C, Three-dimensional time-of-flight MR angiography revealed abnormal vascularity (arrow, A) lateral and superior to the right side of the foramen magnum, suggestive of a DAVF. A right common carotid artery arteriogram, lateral view, arterial (B) and venous (C) phases, confirmed a DAVF supplied by the ascending pharyngeal and posterior auricular arteries with drainage into the epidural venous plexus. The left ascending pharyngeal artery (not shown) also supplied the fistula.

tasia (8), neoplasms, such as chordoma or meningioma, rheumatoid arthritis (9), basal meningitis, subarachnoid hemorrhage, trauma, displacement stemming from a Chiari II malformation, or primary neoplasm of the hypoglossal nerve (10).

Skull base segment: metastatic or primary neoplasms, including nasopharyngeal carcinoma, glomus tumor, nerve sheath tumor, or meningioma, trauma (11), infection, such as mucormycosis, pseudomonas, or tuberculosis (12), and primary bone disorders, including Paget disease, fibrous dysplasia, and primary bone neoplasms.

Carotid space segment: primary or metastatic neoplasm, jugular vein thrombosis (13), arterial dissection (14–16), iatrogenic causes, including jugular vein puncture and carotid endarterectomy (17), traumatic delivery (18), infection, and radiation therapy (19).

Sublingual segment: carcinoma and postoperative infection (20).

Although relatively uncommon, thrombosis of an arteriovenous fistula after angiography has been reported (21–25). In our patient, this event led to a fortuitous cure. DAVFs may present with atypical signs and symptoms, which complicate diagnosis (26, 27). Our patient did have one common symptom of DAVF, pulsatile tinnitus, but this finding was initially overlooked because the other signs and symptoms were more apparent. Among the many reported causes of hypoglossal neuropathy, we were unable to locate any previous report of an isolated hypoglossal nerve palsy caused by a DAVF.

Conclusion

In this case of DAVF, and in others we have seen, sonographic evaluation was unremarkable and MR

imaging/MR angiography showed only subtle abnormalities. Angiography remains the gold standard for diagnosis of DAVF and should be performed if a DAVF is suspected, even if all other tests have been negative.

References

1. Rao KCVG. **Normal anatomy.** In: Lee SHW, Rao KCVG, Zimmerman RA, eds. *Cranial MRI and CT*. 3rd ed. New York: McGraw-Hill; 1992;4:97–98
2. Netter FH. *The CIBA Collection of Medical Illustrations, 1: Nervous System. Part I: Anatomy and Physiology*. Summit, NJ: Ciba-Geigy; 1991:95
3. Smoker WRK. **The hypoglossal nerve.** In: Kelly WM, ed. *Neuroimaging Clinics of North America: Cranial Neuropathy*. Philadelphia: Saunders; 1993;3:193–207
4. Thompson EO, Smoker WRK. **Hypoglossal nerve palsy: a segmental approach.** *Radiographics* 1994;14:939–958
5. Menezes AH, Smoker WRK, Cyste G. **Syringomyelia, Chiari malformations and hydromyelia.** In: Youmans JR, ed. *Neurological Surgery*. 3rd ed. Philadelphia: Saunders; 1990:1421–1429
6. DePaul R, Abbs JH, Caliguri M, et al. **Hypoglossal, trigeminal, facial motor neuron involvement in amyotrophic lateral sclerosis.** *Neurology* 1988;38:281–283
7. DeSimone PA, Snyder D. **Hypoglossal nerve palsy in infectious mononucleosis.** *Neurology* 1978;28:844–847
8. Smoker WRK, Corbett JJ, Gentry LR, et al. **High resolution computed tomography of the basilar artery, I: vertebrobasilar dolichoectasia: clinical-pathologic correlation and review.** *AJNR Am J Neuroradiol* 1986;7:61–72
9. Macedo TF, Gow PJ, Heap SW, et al. **Bilateral hypoglossal nerve palsy due to vertical subluxation of the odontoid process in rheumatoid arthritis.** *Br J Rheumatol* 1988;27:317–320
10. Odake G. **Intracranial hypoglossal neurinoma with extracranial extension: review and case report.** *Neurosurgery* 1989;24:583–587
11. Orbay T, Aykol S, Seckin Z, et al. **Late hypoglossal nerve palsy following fracture of the occipital condyle.** *Surg Neurol* 1989;31:402–404
12. Chandler JR, Grobman L, Quencer R, et al. **Osteomyelitis of the base of the skull.** *Laryngoscope* 1986;96:245–251
13. Olivier A, Scotti G, Melancon D. **Vascular entrapment of the hypoglossal nerve in the neck.** *J Neurosurg* 1977;47:472–475
14. Pozzo GD, Mascali M, Fonda C, et al. **Lower cranial nerve palsy**

- due to dissection of the internal carotid artery: CT and MR imaging. *J Comput Assist Tomogr* 1989;13:989-995
15. Lieschke GJ, Davis S, Tress BM, et al. Spontaneous internal carotid artery dissection presenting as hypoglossal nerve palsy. *Stroke* 1988;19:1151
 16. Pica RA, Rockwell BH, Raji MR, Dastur KJ, Berkey KE. Traumatic internal carotid artery dissection presenting as delayed hemilingual paresis. *AJNR Am J Neuroradiol* 1996;17:86-88
 17. Dehn TCB, Taylor GW. Cranial and cervical nerve damage associated with carotid endarterectomy. *Br J Surg* 1983;70:365-368
 18. Greenberg SJ, Kandt RS, D'Sonza BJ. Birth injury-induced glossaryngeal paresis. *Neurology* 1987;37:533-535
 19. Cheng VST, Schultz MD. Unilateral hypoglossal nerve atrophy as a late complication of radiation therapy of head and neck carcinoma: a report of four cases and a review of the literature on peripheral and cranial nerve damage after radiation therapy. *Cancer* 1975;35:1537-1544
 20. Stankiewicz JA, Pazevic JP. Hypoglossal nerve palsy after tooth extraction. *J Oral Maxillofac Surg* 1988;46:148-149
 21. Hanigan WC, Brady T, Medlock M, Smith EB. Spontaneous regression of giant arteriovenous fistulae during the perinatal period. *J Neurosurg* 1990;73:954-957
 22. Stocks LO, Halpern M, Turner AF. Spontaneous closure of an arteriovenous fistula: report of a case in hereditary hemorrhagic telangiectasia. *Radiology* 1969;92:1499-1500
 23. Mabe H, Furuse M. Spontaneous disappearance of cerebral arteriovenous malformation in infancy: case report. *J Neurosurg* 1977;46:811-815
 24. Osmojola MF, Fox AJ, Vinuela FV, et al. Spontaneous regression of intracranial arteriovenous malformations: report of three cases. *J Neurosurg* 1982;57:818-822
 25. Pasqualin A, Vivenza C, Rossta L, et al. Spontaneous disappearance of intracranial arterio-venous malformations. *Acta Neurochir* 1985;76:50-57
 26. Vinuela F, Fox AJ, Pelz DM, Drake CG. Unusual clinical manifestations of dural arteriovenous malformations. *J Neurosurg* 1986;64:554-558
 27. Kurata A, Takano M, Tokiwa K, Miyasaka Y, Yada K, Kan S. Spontaneous carotid cavernous fistula presenting only with cranial nerve palsies. *AJNR Am J Neuroradiol* 1993;14:1097-1101