



Discover Generics

Cost-Effective CT & MRI Contrast Agents



WATCH VIDEO

AJNR

Gangliogliomas: ubiquitous or not?

M Castillo

AJNR Am J Neuroradiol 1998, 19 (5) 807-809
<http://www.ajnr.org/content/19/5/807.citation>

This information is current as
of June 24, 2025.

Gangliogliomas: Ubiquitous or Not?

Mauricio Castillo, *University of North Carolina, Chapel Hill*

In many publications, gangliogliomas are often referred to as “ubiquitous.” This term, meaning both “existing everywhere” or “constantly encountered,” is both correct and incorrect when referring to these tumors. Gangliogliomas may exist anywhere in the central nervous system, but are not commonly encountered. In this issue of the *American Journal of Neuroradiology*, two articles address the topic of gangliogliomas arising in the brain and spinal cord (1,2). The following are common issues raised regarding gangliogliomas.

How common are gangliogliomas?

These tumors comprise 0.4%–6.25% of all primary brain tumors in adults and approximately 10% of all primary brain tumors in children (3). I believe that their incidence is extremely dependent on the pathologist interpreting the histology. At my institution, we see only one or two gangliogliomas every year. In other hospitals, I have witnessed their incidence to be much higher. In my opinion, cerebral and cerebellar gangliogliomas probably comprise fewer than 1% of all brain tumors in adults and are slightly more common in children. Gangliogliomas arising in the spinal cord are extremely rare and probably represent fewer than 1% of all tumors originating in it. Before the article that appears in this issue of the *AJNR*, only 66 cases had been described in the literature (mostly case reports) (3). Personally, I have not seen a *de novo* case of a spinal cord ganglioglioma. Because gangliogliomas are rare, the term “ubiquitous” is not entirely correct when describing them.

Where are gangliogliomas found?

Nearly all of these tumors are found in the brain. Most of them occur in the temporal lobes and in the cerebellar hemispheres (4). They may, however, be seen in any region of the brain and therefore they are indeed “ubiquitous.” Gangliogliomas have been reported in unusual locations such as the pineal gland, basal ganglia, hypothalamus, and the optic chiasm (5–8). Indeed, in the article by Kincaid et al, gangliogliomas were found in the optic chiasm and hypothalamus/suprasellar region (2). In children with neurofibromatosis type 1, the optic chiasm may be involved by ganglioglioma. Since biopsy is rarely performed in children with neurofibromatosis and lesions of the optic apparatus, the incidence of gangliogliomas in

this location and in this disease is not known. It seems tempting to speculate that ganglioglioma, a tumor which generally grows very slowly, may be a cause of many of the optic chiasm lesions found in children with neurofibromatosis type 1. Indeed, neurofibromatosis type 1 is considered by many to be a disorder of glial cells and neurons, which are also the main histologic components found in gangliogliomas. Even in the face of neurofibromatosis, however, optic chiasm gangliogliomas may demonstrate rapid growth (9). Although these tumors do not metastasize, in one reported case, a ganglioglioma extended into the leptomeninges and the subarachnoid space (10). I have seen one intraventricular ganglioglioma (Fig 1).

How do gangliogliomas present?

Like most brain tumors, patients harboring gangliogliomas often have non specific symptoms. Most of these tumors are found either in infants or young individuals aged 8–31 years (3). Both genders are affected equally. When they arise in the temporal lobes, patients usually present with seizures that are often partial complex and generally intractable to medical therapies. When they arise in the cerebellum, ataxia and headaches secondary to compression of the fourth ventricle and hydrocephalus are common. Most patients have a prolonged period of symptoms before the diagnosis is made (2). According to the paper by Kincaid et al, symptoms persisted about five years. Patients presenting with seizures have a better prognosis than those presenting with other symptoms. I believe that this reflects the fact that patients with seizures receive a more prompt and detailed evaluation than those with other non specific symptoms. When gangliogliomas arise within the spinal cord, most patients present only with progressive and longstanding weakness (1,3). With the exception of the patient's age, the clinical manifestations of these tumors are non specific and often unrevealing when formulating a preoperative differential diagnosis.

What are the imaging findings in gangliogliomas?

Unfortunately, the old adage that “anything may look like anything” applies to gangliogliomas. I have seen only a few gangliogliomas in which either their MR imaging or CT features lead me to place this

Address reprint requests to Mauricio Castillo, MD, Department of Radiology, University of North Carolina School of Medicine, Chapel Hill, NC 27599-7510.

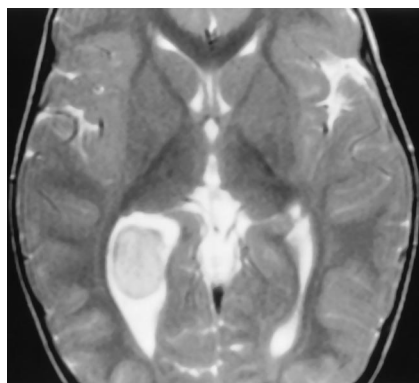


FIG 1. Axial MR T2 weighted image shows a mass in the trigone of the right lateral ventricle. The tumor did not enhance. The appearance of this mass is non specific and ganglioglioma was not considered in the differential diagnosis.

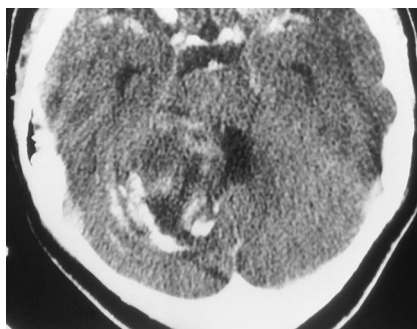


FIG 2. Post contrast axial CT shows a ganglioglioma in the right cerebellum. The tumor has mass effect on the fourth ventricle and is inhomogenous in density. The calcifications have a bizarre pattern and follow the folia. In this case, ganglioglioma was considered the main differential diagnosis.

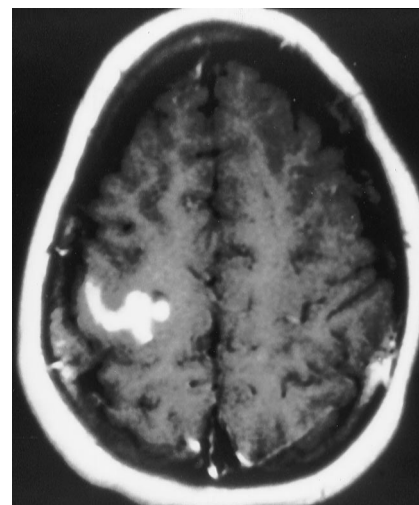


FIG 3. Post contrast axial MR T1 weighted image shows a serpiginous configuration of an enhancing ganglioglioma in the right precentral gyrus. This appearance may be confused with that of a vascular malformation. The T2 weighted sequences showed no flow voids, which suggested that the lesion was solid. Ganglioglioma was not considered in the differential diagnosis.

tumor at the top of the my list of differential diagnoses. My personal experience with these tumors reflects what is described in the article by Kincaid et al (2), i.e., grossly half have cysts, calcifications, and enhancement (4). None of these patterns are specific, although in my opinion, the calcifications found in gangliogliomas may have a bizarre pattern (Fig 2). I have seen one patient in whom the enhancement pattern of the lesion was initially confused for vessels and the tumor was mistaken for a vascular malformation (Fig 3); a similar case has been described in the literature (11). Catheter angiography usually helps in these rare instances by eliminating the possibility of a vascular malformation. Catheter angiography, however, is not indicated in the primary evaluation of these tumors. When angiography is done, it is usually part of a Wada test for tumors located in the temporal lobe. Curiously, Kincaid et al mentioned increased angiographic vascularity in high-grade gangliogliomas (2), but from their paper it is not clear if these were also the tumors showing increased radiotracer uptake on SPECT studies. Surrounding edema is a very unusual feature in gangliogliomas. This finding is also well addressed in the paper by Kincaid et al (2). It is interesting to note that these authors found a correlation between surrounding edema and anaplasia. I believe that the practical implication of this important observation is twofold. First, when only small biopsies are obtained and initially interpreted as gangliogliomas, a gross total resection must be attempted in patients known to have edema. Surgery continues to be the only therapy that can offer a "cure" in these patients. Second, the presence of edema changes the differential diagnosis and obligates us as physicians to pursue a prompt diagnosis and offer a more detailed

and frequent follow up. Kincaid et al conclude that "there is no single pathognomonic radiologic appearance of ganglioglioma" and I agree with this statement (2).

Despite the conclusion offered in the paper by Patel et al, I feel, after reviewing the images of all cases published, that spinal cord gangliogliomas also have a non specific appearance (1). Based on detailed descriptions available in 32 of the 66 cases reported in the literature, only four patients underwent MR imaging; eight were segmental (one to four levels in length), 11 were localized to one region of the cord (usually cervical, thoracic, or conus medullaris), 10 involved two of the above-mentioned regions, and three involved the entire (holocord) spinal cord (3). These previously reported data are not entirely in agreement with the paper by Patel et al in which most spinal cord gangliogliomas had an average length of eight vertebral segments (1). Like many intraspinal tumors, gangliogliomas are slow growing and may result in bone remodeling. Gangliogliomas appear to have more cysts than other spinal cord tumors. If a radiologist considers the possibility of a spinal cord ganglioglioma and communicates this thought to the pathologist, the surgeon can be asked for larger blocs of tissue and can perform the appropriate immunohistochemical tests on them.

What are the histologic features of ganglioglioma?

The pathology of these tumors is addressed in an accompanying commentary by Dr. Norenberg, so I will be brief. The main elements found in gangliogliomas are atypical neurons, astrocytes, and a fibrovas-

cular stroma (12). The neurons are typically moderately pleomorphic and occasionally binucleated. Microcalcifications may be present. In order to confirm the diagnosis, most neuropathologists now resort to immunohistochemistry. The tumor neurons are positive for synaptophysin, neurofilament protein, neuron-specific enolase, and chromogranin A (13). The astrocytes may be malignant, and in rare anaplastic gangliogliomas, it is the astrocytic component that is responsible for their malignancy. The significance of anaplastic astrocytes is uncertain as many anaplastic gangliogliomas lack a clear clinical aggressive behavior (3); therefore, the biological behavior of most of these tumors is not predicted by their histology. Recently, by using proliferation markers such as bromodeoxyuridine, flow cytometry, and antibodies against Ki-76 and proliferating cell nuclear antibody, the growth kinetics of these tumors have been predicted (14,15). Gangliogliomas with a low number of positive cells (<1%–6%) grow slowly. For the neuroradiologist, this implies that in patients with tumors showing that feature, follow up studies may be obtained less often than is usually obtained in other CNS tumors.

How are gangliogliomas treated?

As with most brain tumors, surgery remains the treatment of choice (16). Complete resection leads to a good long-term prognosis. This observation, however, applies mostly to brain and not to spinal cord gangliogliomas. In the spinal cord preservation of neighboring tissues it is mandatory to avoid significant postsurgical deficits. Therefore, tumor is often left behind at the surgical margins and recurrences occur in close to one third of these patients. Recurrences of spinal cord gangliogliomas are 3.5 times more likely to occur than recurrence of brain gangliogliomas (3). The difficulty in resecting these spinal cord tumors is intensified because of the length of involvement. Patel et al state that contrary to low grade gangliogliomas, patients with high-grade spinal cord gliomas not do not benefit from aggressive surgical resection (1). Therefore, considering the diagnosis of spinal cord ganglioglioma may point the pathologist in the right direction and result in less postoperative morbidity. Radiation after gross total resection is not indicated (3). The clinical postresection behavior of non radiated tumors does not differ from those receiving radiation. Furthermore, anaplastic transformation and development of secondary tumors has been reported after radiation of gangliogliomas (3). The issue of post surgical radiation after subtotal resection is controversial; some series report benefit while others show no advantage (17). Adjuvant radiation may, however, be useful in presence of anaplastic gangliogliomas. Chemotherapy has not been shown to be beneficial (17).

What is the role of the neuroradiologist in the evaluation of gangliogliomas?

Unfortunately, I believe that our initial role in these patients is very limited. As in all other patients with brain tumors, our initial job is to define the tumor and its relation to adjacent structures. I believe that because of its relative rarity and variety of appearances, ganglioglioma is seldom considered in the presurgical differential diagnosis. The histology of the tumor should help determine the frequency of follow up studies. Careful analysis of the follow up images should be done to determine recurrences and residual tumor so that a therapeutic decision can be made.

References

1. Patel U, Pinto RS, Miller DC, et al. **MRI of spinal cord ganglioglioma.** *AJNR Am J Neuroradiol.*
2. Kincaid PK, El-Saden SM, Park SH, Goy BW. **Ganglioglioma: clinical, radiological and pathological correlation in 34 patients.** *AJNR Am J Neuroradiol.*
3. Hamburger C, Buttner A, Weis S. **Ganglioglioma of the spinal cord: report of two rare cases and review of the literature.** *Neurosurgery* 1997;41:1410–1416
4. Castillo M, Davis PC, Takei, Hoffman JC. **Intracranial ganglioglioma: MR, CT, and clinical findings in 18 patients.** *AJNR Am J Neuroradiol* 1990;11:109–114
5. Fujimura M, Kayama T, Kumabe T, Yoshimoto T. **Ganglioglioma in the basal ganglia totally resected by a trans-distal Sylvian approach.** *Tohoku J Exp Med* 1995;175:211–218
6. Creasy JL, Jennings MT, Johnson MD, Lavin P, Maciunas RJ. **Ganglioglioma of the pineal gland: clinical and radiographic response to stereotactic radiosurgical ablation.** *J Child Neurol* 1995;10:247–249
7. Bilaniuk LT, Duhaime AC, Galetta SI, et al. **Ganglioglioma involving the optic chiasm.** *Neurology* 1996;46:1669–1673
8. Abe H, Chiba Y, Ohtani T, Tokoro K, Yagishita S. **Pineal ganglioglioma in a patient with familial basal ganglia calcification and elevated serum alpha-fetoprotein: case report.** *Neurosurgery* 1993;33:506–511
9. Hinton DR, Sadun AA, Sadun F. **Rapid growth of an optic nerve ganglioglioma in patient with neurofibromatosis 1.** *Ophthalmology* 1996;103:794–799
10. Tien RD, Tuori SL, Pulkingham N, Burger PC. **Ganglioglioma with leptomeningeal and subarachnoid spread: results of CT, MR, and PET imaging.** *AJR* 1992;159:391–393
11. Baltuch GH, Farmer JP, Meagher-Villemure K, Montes JL, O'Gorman AM. **Ganglioglioma presenting as a vascular lesion in a 10-year old boy. Case report.** *J Neurosurg* 1993;79:920–923
12. Miller DC, Lang FF, Epstein FJ. **Central nervous system gangliogliomas: Part I-Pathology.** *J Neurosurg* 1993;79:859–866
13. Wolf HK, Muller MB, Spanle M, Zentner J, Schramm J, Wiestler OD. **Ganglioglioma: a detailed histopathological and immunohistochemical analysis of 61 cases.** *Acta Neuropathol (Berl)* 1994;88:166–173
14. Allegranza A, Girlando S, Arrigoni GL, et al. **Proliferating cell nuclear antigen expression in central nervous system neoplasms.** *Virchows Arch A* 1991;419:417–423
15. Bowles AP, Pantazis GG, Allen MJB, Martinez J, Allbrook WCJ. **Ganglioglioma, a malignant tumor? Correlation with flow deoxyribonucleic acid cytometric analysis.** *Neurosurgery* 1988;23:376–381
16. Lang FF, Epstein FJ, Ransohoff J, et al. **Central nervous system gangliogliomas: Part 2-Clinical outcome.** *J Neurosurg* 1993;79:867–873
17. Krouwer HGJ, Davis RL, McDermott MW, Hoshino T, Prados MD. **Gangliogliomas: a clinicopathologic study of 25 cases and review of the literature.** *J Neurooncol* 1993;17:139–154