



Discover Generics

Cost-Effective CT & MRI Contrast Agents



WATCH VIDEO

AJNR

The size of lymph nodes in the neck on sonograms as a radiologic criterion for metastasis: how reliable is it?

M W van den Brekel, J A Castelijns and G B Snow

AJNR Am J Neuroradiol 1998, 19 (4) 695-700

<http://www.ajnr.org/content/19/4/695>

This information is current as of June 18, 2025.

The Size of Lymph Nodes in the Neck on Sonograms as a Radiologic Criterion for Metastasis: How Reliable Is It?

Michiel W. M. van den Brekel, Jonas A. Castelijns, and Gordon B. Snow

PURPOSE: A definition of cut-off points for nodal size is essential to determine whether cervical lymph nodes are metastatic or not. Because the currently used size criteria are defined for random populations of patients with head and neck cancer, we set out to study whether these criteria are optimal for patients without palpable metastases in different levels of the neck. We defined optimal size criteria for sonography by calculating the sensitivity and specificity of different size cut-off points.

METHODS: We compared the sensitivity and specificity of different size cut-off points as measured on sonograms for various levels in the neck in a series of 117 patients with and 131 patients without palpable neck metastases.

RESULTS: A minimum axial diameter of 7 mm for level II and 6 mm for the rest of the neck revealed the optimal compromise between sensitivity and specificity in necks without palpable metastases. For all necks together (with and without palpable metastases), the criteria were 1 to 2 mm larger.

CONCLUSION: Our findings indicate that the current sonographic size criteria used for random patient populations are not optimal for necks without palpable metastases, nor can the same cut-off points be used for all levels in the neck.

The management of lymph node metastases in the neck in patients with squamous cell carcinoma of the upper air and food passages is a continuing source of controversy among involved physicians. If suspicious lymph nodes are palpated (N+), most clinicians will treat that side of the neck, even when imaging reveals borderline lymph nodes. The management of the palpably (and radiologically) negative neck (N0) remains controversial (1, 2). Elective treatment of N0 sides by either radiotherapy or surgery is the standard if there is a considerable risk of occult metastases. The main argument used by advocates of elective treatment is that postponement of treatment might be unfavorable for the prognosis. Although such a negative influence can indeed be anticipated, it is likely dependent on the duration of the delay of treatment. Thus far, this unfavorable prognostic influence could not be proved unequivocally in three small prospective studies (3–5).

Imaging of the palpably N0 neck can indeed influence treatment. In this respect, depiction of suspi-

cious lymph nodes may convert both selective neck treatment and a wait-and-see policy to more secure comprehensive treatment of all levels of the neck (6). In contrast, negative imaging findings can be used as an argument to refrain from elective treatment of the neck if the risk of radiologically occult metastases is considered low enough (2, 7–9).

The accuracy of imaging techniques, such as sonography, magnetic resonance (MR) imaging, and computed tomography (CT), for the neck is dependent on the accuracy of the radiologic criteria used for lymph node metastases (10–12). Although very high resolution imaging, immunoimaging, and the development of more specific contrast agents might reveal new criteria (13–16), nodal size and depiction of necrosis are still the most important radiologic criteria. However, as depicted in Table 1, the size criteria currently in use vary from 8 to 30 mm (7, 11, 16–23). Some authors take lymph node level into account, whereas others use nodal shape as well. The shape is measured either in the vertical plane (longitudinal maximum or minimum axial diameter) or in the axial plane (minimum or maximum axial diameter) (Fig 1).

We conducted this study because we believed that lymph nodes in levels III, IV, and V are often smaller than those in levels I and II, and that most nodes are smaller than 1 cm in patients without palpable metastases. We compared the sensitivity and specificity

Received July 22, 1997; accepted after revision October 10.

This study was supported by the Dutch Cancer Society.

From the Departments of Otorhinolaryngology (M.W.M.v.d.B., G.B.S.) and Radiology (J.A.C.), Free University Hospital, Amsterdam, the Netherlands.

Address reprint requests to Michiel W. M. van den Brekel, Department of Otorhinolaryngology, Free University Hospital, De Boelelaan 1117, 1081 HV Amsterdam, the Netherlands.

TABLE 1: Size and shape criteria for lymph node metastases as reported by different authors

Author	Size Criteria
Stern et al (17)	15 mm all levels
Som (11)	15 mm levels I and II or 10 mm elsewhere
Mancuso et al (18) and Hillsamer et al (19)	8 mm retropharyngeal or 15 mm all other levels or grouping of three or more of 8 to 15 mm
Friedman et al (20)	10 mm all levels
Close et al (21)	30 mm ovoid shape or 10 mm round shape or grouping of two or more of 10 to 30 mm
Bruneton et al (16)	8 mm ax-max and long/ax-max <1.5
Steinkamp et al (22)	8 mm ax-min or 8 mm ax-max and long/ax-min <2
Vassallo et al (23)	No size criterion, long/ax-min <2 or absence of a hilus or focal cortical widening
van den Brekel et al (25)	Ax-min 11 mm level II or 10 mm elsewhere or grouping of three or more 8 to 10 mm

Note.—Long indicates longitudinal diameter; ax-max, maximum axial diameter; and ax-min, minimum axial diameter.

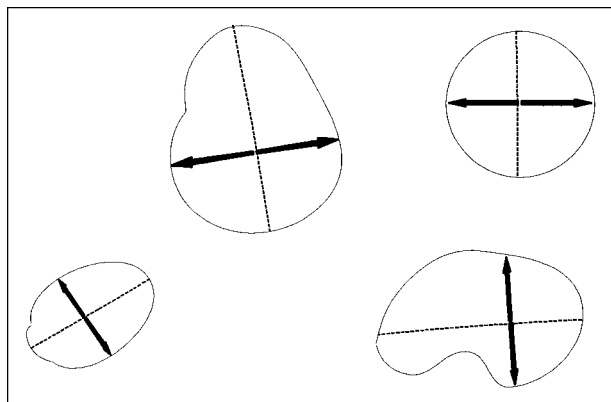


FIG 1. Axial sections through lymph nodes of different shapes. Dotted line represents the maximum axial diameter; solid line with arrowheads is the minimum axial diameter.

of different size criteria, as measured on sonograms, for levels I, II, and III–V in patients with and without palpable metastases (Fig 2).

Methods

The study population consisted of a consecutive series of 184 surgically treated patients with squamous cell carcinoma of the head and neck. These patients underwent a total of 248 neck dissections, of which 131 were performed in patients without palpable metastases (N0, elective). Of the 131 elective neck dissections, 50 were selective and 81 were comprehensive (all levels of the neck). Of the whole series of 248 neck dissections, 53 were selective and 195 comprehensive.

Because a previous study has shown the size of reactively enlarged and metastatic nodes in levels III, IV, and V to be comparable (24), and because in this study the number of positive tumoral nodes in levels III, IV, and V was too small to be studied separately, we categorized these levels as one nodal group. Levels I and II were the other two categorized nodal groups. The sensitivity and specificity of different size criteria were calculated using different size cut-off points.

Lymph node size measurements were made preoperatively with use of either a 7.5-MHz linear array transducer on an Aloka SSD 650 system (Aloka, Tokyo) or a 7-MHz linear array transducer on an Acuson 128 system (Acuson Corp, Mountain View, Calif) by one of the authors. All visualized lymph nodes at sonography were categorized by level and measured on screen. Level I corresponds to the submandibular and submental areas. Lymph nodes in this area are situated mainly medial to the mandible around the submandibular gland. Levels II, III, and IV are medial to the sternocleidomastoid muscle around the internal jugular vein. Level II nodes correspond to the high jugular and subdiaphragmatic lymph nodes. The superior border is

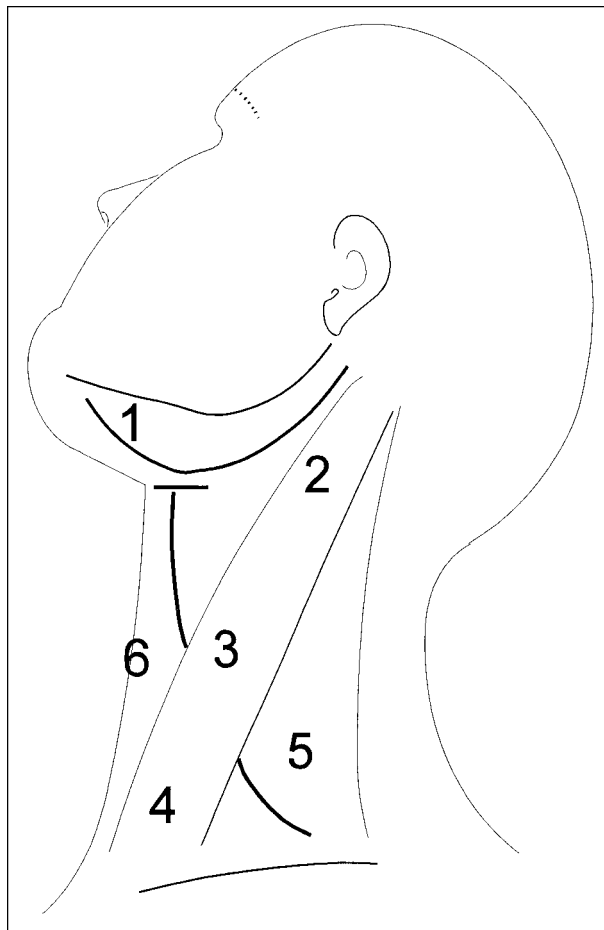


FIG 2. Lymph node levels in the neck. Level 1 corresponds to the submental and submandibular area; level 2 to the subdiaphragmatic area; level 3 to the midjugular area; level 4 to the low jugular area; and level 5 to the posterior triangle and the supraclavicular area. Level 6, which was not studied, encompasses the paratracheal and parapharyngeal nodes.

the base of the skull, the inferior border is less well defined at the level of the hyoid bone. Caudal to these nodes are the level III or midjugular nodes, which are bordered inferiorly by the crossing of the omohyoid muscle with the internal jugular vein at the level of the inferior rim of the thyroid cartilage. Level IV nodes are inferior to this landmark and level V nodes are posterior to the sternocleidomastoid muscle in the posterior triangle.

Internal echogenicity was not recorded routinely. The minimum axial diameter of the largest node in each categorized area was used for statistical correlation. The findings of these

TABLE 2: Sensitivity and specificity of different size criteria (minimum nodal diameter as measured on sonograms) for all 248 neck dissections (145 positive, 103 negative)

Minimum Axial Diameter, mm*	Sensitivity, %	Specificity, %
4	95	31
5	94	40
6	91	52
7	83	70
8	74	78
9	69	88
10	63	92
11	57	97

* Level II was 1 mm larger.

TABLE 3: Sensitivity and specificity of different size criteria (minimum nodal diameter as measured on sonograms) for 131 clinically impalpable of the neck (51 positive, 80 negative)

Minimum Axial Diameter, mm*	Sensitivity, %	Specificity, %
4	90	33
5	86	44
6	80	59
7	61	76
8	41	84
9	27	95
10	16	98
11	10	99

* Level II was 1 mm larger.

nodal measurements were compared with the outcome of the histopathologic examination of the neck dissection specimen.

A meticulous histopathologic protocol enabling topographic correlation by level was used. After obtaining a photograph and a plain radiograph of the specimen (while immersed in 97% alcohol [25]), the specimen was fixed for 36 to 48 hours in 4% formaldehyde. All nodes visible on the radiograph and/or palpable in the specimen were measured and excised for microscopic examination. It has been shown that nodal size is hardly changed by this fixation (25). The location of all nodes was recorded and indicated on the photograph and the radiograph of the specimen. By recording the location and size of all lymph nodes, it was possible to perform a topographic correlation per level. Level I nodes are easily categorized, as they are situated around the submandibular gland, which is routinely dissected. As most of the anatomic landmarks, except for the omohyoid and sternocleidomastoid muscle, are absent in the specimen, levels II, III, and IV were defined as three equal parts beneath the sternocleidomastoid muscle. In cases of doubt, the specimen radiograph and the size of the nodes proved to be helpful for categorizing the nodes. Correlation by node was not performed, as this proved to be impossible for the majority of dissected lymph nodes.

Results

Of the 248 neck dissection specimens obtained, 145 (58%) contained one or more metastases. Level I was positive in 39 cases, level II in 114 cases, and levels III through V in 74 cases. Of the 131 N0 sides, metastases were found in 51 (39% false-negative rate of palpation). Level I was positive in 14 cases, level II contained metastases in 31 sides, and levels III through V were positive in 19 cases.

Of course, the number of lymph nodes found at histopathology by far outreached the number mea-

TABLE 4: Sensitivity of different size criteria (minimum nodal diameter as measured on sonograms) for different levels in all 248 neck dissections

Minimum Axial Diameter, mm	Sensitivity, %		
	Level I	Level II	Levels III-V
4	82	92	81
5	77	91	80
6	67	89	76
7	56	87	72
8	46	81	61
9	44	73	49
10	33	69	47
11	23	63	41

TABLE 5: Specificity of different size criteria (minimum nodal diameter as measured on sonograms) for different levels in all 248 neck dissections

Minimum Axial Diameter, mm	Specificity, %		
	Level I	Level II	Levels III-V
4	68	38	64
5	72	46	73
6	80	58	89
7	89	72	94
8	92	80	97
9	96	89	100
10	98	93	100
11	99	95	100

sured on sonograms. Unfortunately, a comparison of the sonographic findings of each single node with its histopathology is impossible because of the unclear topographic descriptions in each technique. Because of this, and because it is clinically relevant and reproducible, we compared the size of the largest lymph node in each level with the histopathologic findings of all nodes in that level.

The results of the study are summarized in Tables 2 through 7. If the best compromise of size criteria is to be selected for the whole patient group (Table 2), a criterion of 9 mm for level II and 8 mm for the rest of the neck reveals a sensitivity of 74% and a specificity of 78%. However, as shown in Table 3, these criteria do not seem appropriate for the N0 population, as the sensitivity falls from 74% to 41%. For this population, the criteria of 7 mm for level II and 6 mm elsewhere would be better, although the specificity is then quite low (59%).

If level I is studied separately, a criterion of 5 mm would yield a reasonable sensitivity (77%) and specificity (72%) for the whole population (Tables 4 and 5). For patients who had elective surgery (Tables 6 and 7) this cut-off point yields a sensitivity and specificity of 71%. The high specificity at 10 and 11 mm indicates that lymph nodes of this size are almost always metastatic in this level.

A study of level II lymph nodes shows that for the whole population a minimum diameter of 8 mm gives a relatively high sensitivity and specificity of 81% and 80%, respectively. As shown in Tables 6 and 7, for

TABLE 6: Sensitivity of different size criteria (minimum nodal diameter as measured on sonograms) for different levels in 131 clinically impalpable sides of the neck

Minimum Axial Diameter, mm	Sensitivity, %		
	Level I	Level II	Levels III-V
4	79	87	68
5	71	87	63
6	57	81	53
7	43	77	43
8	21	58	32
9	14	39	11
10	7	29	11

patients with clinically negative findings, a criterion of 7 mm seems more useful, since with 8 mm, the sensitivity drops to 58%.

For the rest of the neck, the optimal cut-off point seems to be between 4 and 6 mm. With use of 6 mm, the specificity and sensitivity are 89% and 76%, respectively. However, for electively operated sides, the sensitivity drops to 53% (Table 6).

Discussion

Size criteria for lymph node metastases differ among studies. Most authors have defined their criteria by measuring nodes on CT scans and comparing the results with histopathologic data (7, 11, 16–23). So far, only two studies have explored criteria by evaluating the nodal size in neck dissection specimens (12, 25). Don and coworkers (12) evaluated the longitudinal diameter as a criterion and concluded that it is very inaccurate. By comparing three lymph node diameters, van den Brekel and coworkers (25) previously concluded that the minimum axial diameter is a better criterion than both the maximum axial diameter and the longitudinal diameter. This minimum diameter is also accepted to be a better criterion for mediastinal lymph nodes (26). Don et al (12) found that 68 (67%) of 102 metastatic nodes had a longitudinal diameter smaller than 1 cm, whereas van den Brekel (25) found this in 48 (33%) of 144 nodes. This difference could have been caused by different patient populations or by the fact that the longitudinal diameter as defined by Don et al was not the largest lymph node diameter, since they measured lymph nodes on microscopic slides. For the minimum axial diameter, we even found that 102 (71%) of 144 were smaller than 1 cm (25). Therefore, a size criterion of 1 cm or larger will misrepresent the majority of all nodal metastases.

Because both reactive and metastatic lymph nodes in level II tend to be larger in patients with head and neck cancer (24), many authors agree that the size criterion for lymph nodes in level II is larger (Table 1). In places where reactively enlarged nodes are seldom encountered, such as the retropharyngeal spaces, it has previously been stated that 8-mm nodes (maximum axial diameter) should be categorized as metastases (18). It might thus be warranted to dif-

TABLE 7: Specificity of different size criteria (minimum nodal diameter as measured on sonograms) for different levels in 131 clinically impalpable sides of the neck

Minimum Axial Diameter, mm	Specificity, %		
	Level I	level II	Levels III-V
4	68	41	68
5	71	50	76
6	80	63	91
7	91	77	96
8	96	84	97
9	99	91	100
10	100	95	100

ferentiate among size criteria for different levels in the neck.

Although the most important consideration from the clinician's point of view concerns the clinically negative neck, radiologists currently base their criteria on findings in a random population of patients with head and neck cancer. As necrosis is a rare finding in small nodes (12), the size criterion is especially important in these N0 necks. Our results clearly show that the currently used size criterion of around 10 mm (minimum axial diameter) yields a very low sensitivity and is not useful in the N0 neck. It is clear from this study that size criteria should be smaller for clinically negative neck sides, as the sensitivity for each criterion drops dramatically because metastases in these difficult neck sides are smaller. From this study, it also seems justified to distinguish among different levels of the neck.

Optimal size criteria should be both very sensitive and specific. As shown in the results, all cut-off points are a compromise between sensitivity and specificity. In clinical practice, elective treatment of the neck is widely accepted. If clinicians are influenced by imaging results to maintain a wait-and-see policy, they need a very sensitive test (or criterion), because undertreatment is not as acceptable as overtreatment. Since high sensitivity is accompanied by low specificity, the question is, how low a specificity is acceptable. With a size criterion of 5 mm (6 mm for level II) and a sensitivity and specificity of 86% and 44%, respectively (Table 3), we found 45 false-positive, 35 true-negative, 44 true-positive, and seven false-negative sides. This means metastasis would recur in seven (17%) of 42 sides after a wait-and-see policy, whereas 45 (51%) of the 89 treated sides would not contain metastases. On the other hand, when 6 mm (7 mm for level II) is used, 10 (18%) of 57 observed sides would have recurrent metastases, whereas 33 (45%) of the 74 operated sides would not contain metastases. For 7 mm (8 mm for level II), 20 (25%) of 81 observed sides would have recurrent metastases, whereas 19 (38%) of 50 operated sides would not contain metastases.

On the basis of these calculations, we propose the following criteria for the N0 neck as a compromise: for level II lymph nodes, a minimum axial diameter of 7 mm should be considered suggestive of metastasis, whereas in the rest of the neck, lymph nodes of 6 mm

or larger should be considered suspicious. Although the calculations by level do point toward even smaller criteria (4 to 5 mm for level I, 6 to 7 mm for level II, and 4 mm for levels III through V), clinicians are more interested in neck sides; hence, these calculations seem more relevant.

Because lymph node sizes in this study were obtained from measurements made on sonograms, and small nodes might have been overlooked, a limitation of this study is the accuracy of the sonographic assessment. The fact that for level I and levels III to V the maximum obtainable sensitivity at 4 mm remains below 80% can be explained by the observation that metastases in these levels are in general smaller than those in level II and/or that sonography of these levels is more difficult. It is striking that the size criteria found in this study are smaller than previous criteria obtained from histopathologic size measurements (25). For example, in the current study, with a size criterion of 7 mm (8 mm for level II), sensitivity and specificity are 83% and 70%, respectively (Table 2). In the previous histopathologic study (25), in which a criterion of 9 mm (10 mm for level II) was used, the sensitivity and specificity were comparable at 89% and 70%, respectively. Thus far, we cannot explain this difference, although it might be caused by differences in patient populations or errors in sonographic measurements. However, the relatively small size criteria that we found in the current study are in agreement with those reported by Steinkamp et al (22), who used CT measurements, and Bruneton et al (16), who used sonographic measurements.

It is further clear from this study that size criteria in general are not very accurate. Although lymph nodes with a minimum axial diameter of 9 mm in levels III through V, 10 mm in level I, and 12 mm in level II are almost always metastatic, such large lymph nodes are exceptional in necks without clinical evidence of metastasis. Since size criteria thus remain unreliable, it is our opinion that lymph nodes should be aspirated to obtain cytologic specimens. In a previous report, it was found that with the use of sonographically guided aspiration cytology a sensitivity of 73% with a specificity of 100% could be obtained in N0 necks. Recently, however, a multicenter study using sonographically-guided aspiration (27, 28) reported a sensitivity of only 42% for this population. Because the prevalence of micrometastases exclusively in these N0 necks is 25%, it should be understood that any currently available imaging technique can never reach a sensitivity of over 75% without losing high specificity (29). Morphologic criteria, such as focal cortical widening (23) or depiction of small tumor areas inside a lymph node, might become more important as the contrast and spatial resolution of imaging techniques increase.

Conclusion

Our study shows that the current size criterion of around 1 cm for declaring a cervical lymph node metastatic is not optimal and should be smaller, cer-

tainly for patients without palpable metastases in the neck. Furthermore, the size criteria for lymph nodes in level I and levels III through V should be smaller than that for level II. We found that a minimum axial diameter of 7 mm for level II and 6 mm for the rest of the N0 neck represented the best compromise between sensitivity and specificity. However, the size of lymph nodes was not an accurate predictor of metastasis in the N0 neck.

References

1. Khafif RA, Gelbfish GA, Tepper P, Attie JN. **Elective radical neck dissection in epidermoid cancer of the head and neck. a retrospective analysis of 853 cases of mouth, pharynx, and larynx cancer.** *Cancer* 1991;67:67-71
2. Weiss MH, Harrison LB, Isaacs RS. **Use of decision analysis in planning a management strategy for the stage N0 neck.** *Arch Otolaryngol Head Neck Surg* 1994;120:699-702
3. VandenBrouck C, Sancho-Garnier H, Chassagne D, Saravane D, Cachin Y, Micheau C. **Elective versus therapeutic radical neck dissection in epidermoid carcinoma of the oral cavity.** *Cancer* 1980;46:386-390
4. Fakih AR, Rao RS, Borges AM, Patel AR. **Elective versus therapeutic neck dissection in early carcinoma of the oral tongue.** *Am J Surg* 1989;4:309-313
5. Kligerman J, Lima RA, Soares JR, et al. **Supraomohyoid neck dissection in the treatment of T1/T2 squamous cell carcinoma of oral cavity.** *Am J Surg* 1994;168:391-394
6. van den Brekel MWM, Leemans CR, Snow GB. **Assessment and management of lymph node metastases in the neck in head and neck cancer patients.** *Crit Rev Oncol Hematol* 1996;22:175-182
7. van den Brekel MW, Castelijns JA, Stel HV, Golding RP, Meyer CJ, Snow GB. **Modern imaging techniques and ultrasound-guided aspiration cytology for the assessment of neck node metastases: a prospective comparative study.** *Eur Arch Otorhinolaryngol* 1993;250:11-17
8. Baatenburg de Jong RJ, Rongen RJ, Verwoerd CDA, Overhagen van H, Laméris JS, Knekt P. **Ultrasound-guided fine needle aspiration biopsy of neck nodes.** *Arch Otolaryngol Head Neck Surg* 1991;117:402-404
9. van den Brekel MW, Castelijns JA, Stel HV, et al. **Occult metastatic neck disease: detection with us and us-guided fine-needle aspiration cytology.** *Radiology* 1991;180:457-461
10. van den Brekel MW, Castelijns JA, Snow GB. **Detection of lymph node metastases in the neck: radiologic criteria.** *Radiology* 1994;192:617-618
11. Som PM. **Detection of metastasis in cervical lymph nodes: CT and MR criteria and differential diagnosis.** *AJR Am J Roentgenol* 1992;158:961-969
12. Don DM, Anzai Y, Lufkin RB, Fu Y, Calcaterra TC. **Evaluation of cervical lymph node metastases in squamous cell carcinoma of the head and neck.** *Laryngoscope* 1995;105:669-674
13. Yousem DM, Hurst RW. **MR of cervical lymph nodes: comparison of fast spin-echo and conventional spin-echo T2W scans.** *Clin Radiol* 1994;49:670-675
14. Anzai Y, Blackwell KE, Hirschowitz SL, et al. **Initial clinical experience with dextran-coated superparamagnetic iron oxide for detection of lymph node metastases in patients with head and neck cancer.** *Radiology* 1994;192:709-715
15. Quak J, Gerretsen M, De Bree R, Brakenhof R, van Dongen G, Snow G. **Perspectives of monoclonal antibodies for detection and treatment of head and neck tumours.** *Anticancer Res* 1993;13:2533-2539
16. Bruneton JN, Balu-Maestro C, Marcy PY, Melia P, Mourou MY. **Very high frequency (13 MHz) ultrasonographic examination of the normal neck: detection of normal lymph nodes and thyroid nodules.** *J Ultrasound Med* 1994;13:87-90
17. Stern WBR, Silver CE, Zeifer BA, Persky MS, Heller KS. **Computed tomography of the clinically negative neck.** *Head Neck* 1990;12:109-113
18. Mancuso AA, Harnsberger HR, Muraki AS, Stevens MH. **Computed tomography of cervical and retropharyngeal lymph nodes: normal anatomy, variants of normal, and applications in staging head and neck cancer, II: pathology.** *Radiology* 1983;148:715-723
19. Hillsamer PJ, Schuller DE, McGhee RB, Chakeres D, Young DC.

- Improving diagnostic accuracy of cervical metastases with computed tomography and magnetic resonance imaging.** *Arch Otolaryngol Head Neck Surg* 1990;116:1297-1301
20. Friedman M, Mafee MF, Pacella BL Jr, Strorigl TL, Dew LL, Toriumi DM. **Rationale for elective neck dissection in 1990.** *Laryngoscope* 1990;100:54-59
21. Close LG, Merkel M, Vuitch MF, Reisch J, Schaefer SD. **Computed tomographic evaluation of regional lymph node involvement in cancer of the oral cavity and oropharynx.** *Head Neck* 1989;11:309-317
22. Steinkamp HJ, Hosten N, Richter C, Schedel H, Felix R. **Enlarged cervical lymph nodes at helical CT.** *Radiology* 1994;191:795-798
23. Vassallo P, Wernecke K, Roos N, Peters PE. **Differentiation of benign from malignant superficial lymphadenopathy: the role of high-resolution US.** *Radiology* 1992;183:215-220
24. van den Brekel MWM. *Assessment of Lymph Node Metastases in the Neck: A Radiological and Histopathological Study.* Amsterdam, the Netherlands: Free University; 1992: chap 3. Thesis
25. van den Brekel MWM, Stel HV, Castelijns JA, et al. **Cervical lymph node metastasis: assessment of radiologic criteria.** *Radiology* 1990;177:379-384
26. Glazer GM, Gross BH, Quint LE, Francis IR, Bookstein FL, Orringer MB. **Normal mediastinal lymph nodes: number and size according to american thoracic society mapping.** *AJR Am J Roentgenol* 1985;144:261-265
27. Takes RP, Knecht P, Manni JJ, et al. **Regional metastases in head and neck squamous cell carcinoma: revised value of US with US-guided FNAB.** *Radiology* 1996;198:819-823
28. van den Brekel MWM. **US-guided fine-needle aspiration cytology of neck nodes in patients with N0 disease.** *Radiology* 1996;201:580-581
29. van den Brekel MWM, van der Waal I, Meyer CJLM, Freeman JL, Castelijns JA, Snow GB. **The incidence of micrometastases in neck dissection specimens obtained from elective neck dissections.** *Laryngoscope* 1996;106:987-991