



Providing Choice & Value

Generic CT and MRI Contrast Agents



**FRESENIUS
KABI**

CONTACT REP

AJNR

**Multifocal varicella-zoster virus
leukoencephalitis in a patient with AIDS: MR
findings.**

N Aygun, D A Finelli, M S Rodgers and R H Rhodes

AJNR Am J Neuroradiol 1998, 19 (10) 1897-1899

<http://www.ajnr.org/content/19/10/1897>

This information is current as
of July 13, 2025.

Multifocal Varicella-Zoster Virus Leukoencephalitis in a Patient with AIDS: MR Findings

Nafi Aygun, Daniel A. Finelli, Mark S. Rodgers, and Roy H. Rhodes

Summary: We describe a patient with AIDS who presented with an acute encephalitis caused by infection with varicella-zoster virus. The hemorrhagic, necrotizing encephalitis had an unusual MR appearance, with innumerable discrete, small, targetlike lesions in the right cerebral hemisphere, which were coalescent in the posterior temporal, parietal, and occipital regions. Of the several known disease patterns of varicella-zoster viral infection in the CNS, this histopathologic pattern of multifocal leukoencephalitis is rare. It is important to recognize, as effective antiviral drug treatments are available.

CNS disease resulting from varicella-zoster virus (VZV) is rare in healthy populations, and it constitutes only 2% of the opportunistic CNS infections seen in patients with AIDS (1). Clinical recognition of the disease is difficult, because only a third of the patients present with typical skin eruptions. Although the different patterns of CNS involvement are pathologically well defined (1), the corresponding imaging findings of these patterns are not. We report the MR findings of a case of an acute, multifocal, necrotizing encephalitis due to VZV in a patient with AIDS.

Case Report

A 41-year-old man in whom AIDS had been diagnosed 2½ years previously presented with a 2-week history of progressive left-sided weakness and blurred vision. He had had no previous skin eruptions. His medical history included a prior episode of *Pneumocystis carinii* pneumonia and a systemic parvovirus infection with bone marrow suppression 4 months earlier. At the time of presentation, the patient's CD4 count was 20. Neurologic examination revealed moderately decreased muscle strength (3/5) and decreased pinprick and light touch sensation on the left side. Deep tendon reflexes were hyperactive in the left upper and lower extremities. Ophthalmologic evaluation showed bilateral retinitis. A CT scan showed a vague, ill-defined hypodensity in the right posterior temporoparietal region, with slight mass effect and no contrast enhancement. CSF examination revealed a mildly elevated total protein of 59 mg/dL, with 1463 RBCs/mL and 13 WBCs/mL, with lymphocytic predominance, including atypical lymphocytes. The pa-

tient was started on dexamethasone, pyrimethamine, and clindamycin for possible toxoplasmosis. Serologic studies, stains, and cultures of the CSF were negative for toxoplasmosis, cryptococcus, yeast, acid-fast bacillus, fungi, and syphilis. An MR examination performed on the second day of hospitalization showed multifocal abnormalities in the right posterior temporal, parietal, and occipital regions (Fig 1A). The patient was maintained on antitoxoplasmosis drug therapy, but did not respond clinically. On the seventh day of hospitalization, a ²⁰¹Tl-SPECT scan of the brain was performed, which showed no locally increased activity in the involved region, making lymphoma unlikely.

A follow-up contrast-enhanced MR study of the brain 4 days later showed progression of disease (Fig 1B–E), and an open brain biopsy was performed 3 days after that. The brain biopsy specimen showed viral encephalitis (Fig 1F), and the patient was begun on ganciclovir the same day. When encephalitis of a herpes-group virus was suggested, the patient was switched to acyclovir therapy. A final diagnosis of VZV encephalitis was established by immunohistochemical staining (Fig 1G), and the patient was placed on ganciclovir and foscarnet for long-term therapy.

The patient recovered with minimal residual left-sided weakness. His necrotizing retinitis was also attributed to VZV, and he had sustained a marked loss of vision. A follow-up CT scan of the brain 4 months later showed encephalomalacia in the right posterior temporal, parietal, and occipital regions. Interestingly, 5 months after the episode of VZV encephalitis, the patient presented with cutaneous varicella-zoster eruptions (shingles) in the right parietal region of the scalp. He is alive at this writing, 18 months after presentation.

Discussion

VZV infection in AIDS patients, although estimated to be responsible for less than 2% of all neurologic complications, is likely to become more prevalent owing to increased life expectancy in this patient group (1, 2). VZV infection is usually seen in the late stages of AIDS, when the CD4 count is below 50. One third of the patients have typical skin lesions; in the remainder, skin findings are either totally absent or temporally remote from the neurologic syndrome (3, 4). Awareness and early recognition of this disease are of crucial importance, since effective antiviral

Received November 5, 1997; accepted after revision February 11, 1998.

From the Departments of Radiology (N.A., D.A.F.) and Pathology (M.S.R., R.H.R.), MetroHealth Medical Center/Case Western Reserve University School of Medicine, Cleveland, OH.

Address reprint requests to Daniel A. Finelli, MD, Department of Radiology, MetroHealth Medical Center, 2500 MetroHealth Dr, Cleveland, OH 44109.

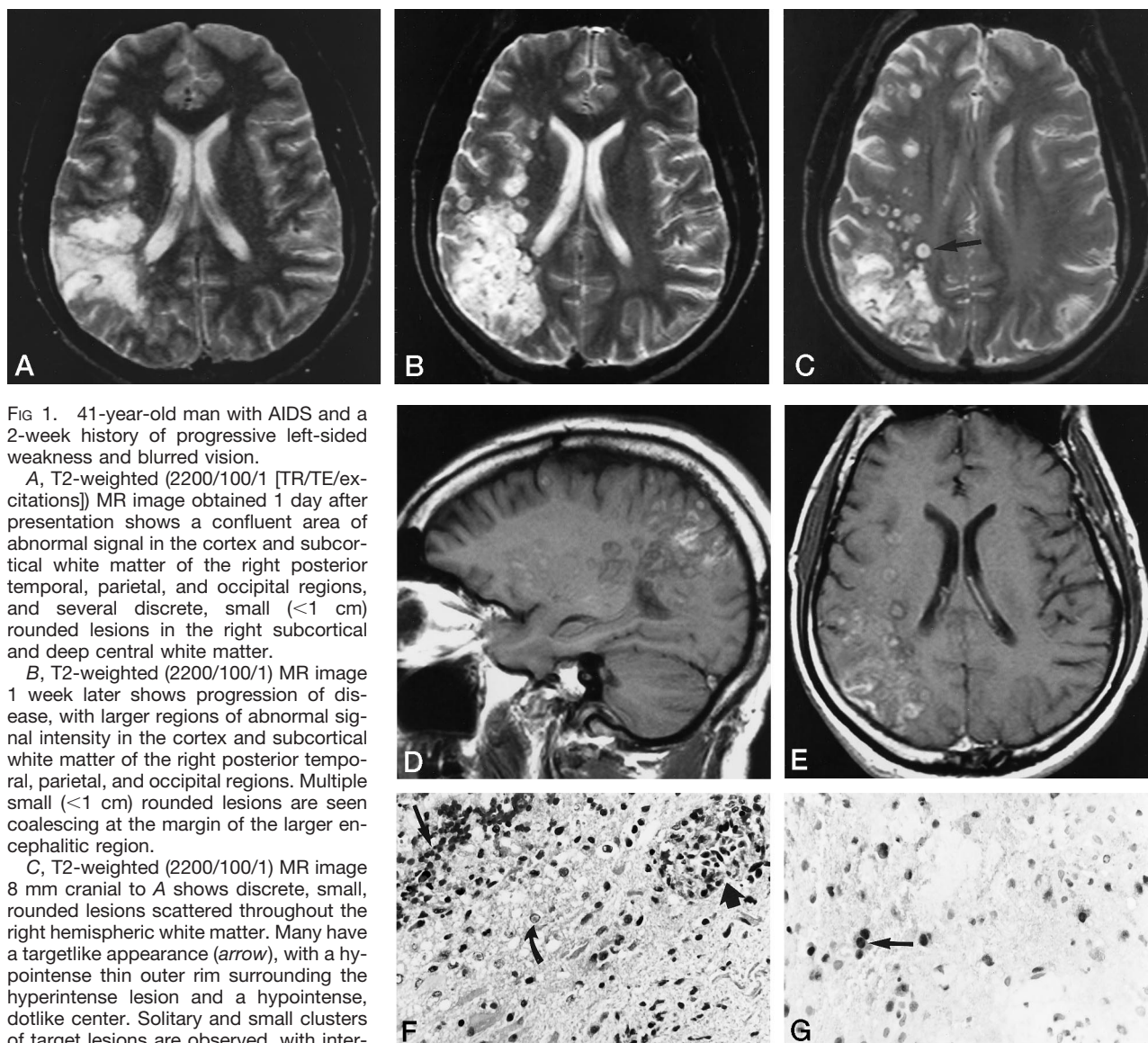


FIG 1. 41-year-old man with AIDS and a 2-week history of progressive left-sided weakness and blurred vision.

A, T2-weighted (2200/100/1 [TR/TE/excitations]) MR image obtained 1 day after presentation shows a confluent area of abnormal signal in the cortex and subcortical white matter of the right posterior temporal, parietal, and occipital regions, and several discrete, small (<1 cm) rounded lesions in the right subcortical and deep central white matter.

B, T2-weighted (2200/100/1) MR image 1 week later shows progression of disease, with larger regions of abnormal signal intensity in the cortex and subcortical white matter of the right posterior temporal, parietal, and occipital regions. Multiple small (<1 cm) rounded lesions are seen coalescing at the margin of the larger encephalitic region.

C, T2-weighted (2200/100/1) MR image 8 mm cranial to A shows discrete, small, rounded lesions scattered throughout the right hemispheric white matter. Many have a targetlike appearance (arrow), with a hypointense thin outer rim surrounding the hyperintense lesion and a hypointense, dotlike center. Solitary and small clusters of target lesions are observed, with intervening normal-appearing white matter and no significant associated surrounding vasogenic edema.

D, Unenhanced T1-weighted image (600/16/1) shows increased signal intensity due to petechial hemorrhage in some of the target lesions as well as in the cortex of the extensively involved right temporoparietal region.

E, Contrast-enhanced T1-weighted image (600/16/1) shows mild enhancement in both the target and confluent lesions.

F, Photomicrograph of brain biopsy specimen shows typical viral encephalitic changes, including hemorrhagic infarction, diffuse demyelination, and fibrinoid necrosis of small vessel walls. Exuberant astrocytosis is seen at the edge of a region of hemorrhagic infarction (long straight arrow), and there is infiltration and cuffing of small vessels by lymphocytes (short wide arrow). Astrocytes and neurons show eosinophilic, glassy, intranuclear inclusions, surrounded by a clear space, typical of the Cowdry A type inclusion bodies frequently seen in encephalitis due to Herpes-group viruses (curved arrow) (hematoxylin-eosin, $\times 250$).

G, Immunohistochemical staining shows VZV in the Cowdry type A inclusion bodies (arrow) (the positive cells are very dark in this black and white print), and stains for herpes simplex virus (HSV I and II) and cytomegalovirus were negative (hematoxylin-eosin, $\times 250$).

drug treatments are available. In our patient, nearly 3 weeks elapsed, several working diagnoses were pursued, and four different drug treatment regimens were initiated before the final diagnosis of VZV encephalitis was made from brain biopsy specimens.

A variety of neurologic syndromes have been ascribed to VZV infection. A recent neuropathologic study by Gray et al (1) proposed five different patterns of CNS involvement in AIDS patients: multifocal leukoencephalitis, ventriculitis, acute meningo-myelorradiculitis, focal necrotizing myelitis, and necrotizing angiitis involving leptomeningeal arteries

with cerebral infarction. The different patterns suggest that spread of VZV to the CNS can occur by direct transneuronal spread, by hematogenous spread, and by CSF seeding, as opposed to the classically described "reactivation" of dormant virus in the dorsal root ganglia that produces cutaneous shingles. Although our patient had unilateral disease, bilateral involvement has been shown frequently in clinical and pathologic studies (1, 3-5). The distribution of lesions in this case suggests a middle cerebral artery vascular territory, which may indicate a combination of necrotizing angiitis and leukoencephalitis;

this combination of ischemic and demyelinative lesions in an immunocompromised patient is suggestive of VZV encephalitis (6). The description of histopathologic findings and the photographs of gross specimens with the acute multifocal leukoencephalitis pattern in the articles by Gray et al (1), Ryder et al (4), and Morgello et al (5) show 0.5- to 1.0-cm ovoid, targetlike lesions resulting from central necrosis surrounded by a well-defined zone of demyelination and an outer zone of reactive astrocytes and microglia, macrophages, and slight peripheral edema. The eosinophilic, Cowdry type A intranuclear inclusion bodies are seen in all CNS cell populations, and the VZV genome can be identified in these inclusion bodies by polymerase chain reaction (PCR) (7). More than one pattern of VZV infection may occur simultaneously (1, 5), and coexistent necrotizing retinitis with VZV cerebral vasculitis has been reported in association with AIDS (8).

Conclusion

The multifocal leukoencephalopathy pattern of VZV infection is not well described in the neuroimaging literature. The unique MR appearance and distribution of this necrotizing encephalitis, with multiple discrete target lesions coalescing into larger regions of extensive parenchymal involvement, differentiate VZV encephalopathy from typical lesions of toxoplasmosis or progressive multifocal leukoenceph-

alopathy. Appropriate suggestion of the entity on radiologic studies may lead to less invasive diagnostic tools, such as PCR analysis of CSF cells for VZV (7), potentially precluding brain biopsy and leading to more rapid diagnosis and institution of antiviral drug therapies.

References

1. Gray F, Belec L, Lescs MC, et al. **Varicella-zoster virus infection of the central nervous system in the acquired immune deficiency syndrome.** *Brain* 1994;117:987-999
2. Weller TH. **Varicella and herpes zoster: changing concepts of the natural history, control and importance of a not so benign virus (part two).** *N Engl J Med* 1983;309:1434-1440
3. Horten B, Price RW, Jimenez D. **Multifocal varicella-zoster virus leukoencephalitis temporally remote from herpes zoster.** *Ann Neurol* 1981;9:251-266
4. Ryder JW, Croen K, Kleinschmidt-Demasters BK, et al. **Progressive encephalitis three months after resolution of cutaneous zoster in a patient with AIDS.** *Ann Neurol* 1986;19:182-188
5. Morgello S, Block GA, Price RW, Petit CK. **Varicella-zoster virus leuko-encephalopathy and cerebral vasculopathy.** *Arch Pathol Lab Med* 1988;112:173-177
6. Amlie-Lefond C, Kleinschmidt-DeMasters BK, Mahalingam R, Davis LE, Gilden DH. **The vasculopathy of varicella-zoster virus encephalitis.** *Ann Neurol* 1995;37:784-790
7. Rosenberg F, Lebon P. **Amplification and characterization of Herpesvirus DNA in cerebrospinal fluid from patients with acute encephalitis.** *J Clin Microbiol* 1991;29:2412-2417
8. Rousseau F, Perronne C, Raguin G, et al. **Necrotizing retinitis and cerebral vasculitis due to varicella-zoster virus in patients infected with the human immunodeficiency virus (letter).** *Clin Infect Dis* 1993;17:943-944