

Generic Contrast Agents

Our portfolio is growing to serve you better. Now you have a *choice*.



[VIEW CATALOG](#)

AJNR

This information is current as of May 27, 2025.

Ophthalmoplegic migraine: reversible enhancement and thickening of the cisternal segment of the oculomotor nerve on contrast-enhanced MR images.

A S Mark, J Casselman, D Brown, J Sanchez, M Kolsky, T C Larsen, 3rd, P Lavin and B Ferraraccio

AJNR Am J Neuroradiol 1998, 19 (10) 1887-1891
<http://www.ajnr.org/content/19/10/1887>

Ophthalmoplegic Migraine: Reversible Enhancement and Thickening of the Cisternal Segment of the Oculomotor Nerve on Contrast-Enhanced MR Images

Alexander S. Mark, Jan Casselman, Douglas Brown, Joao Sanchez, Martin Kolsky, Theodore C. Larsen III, Patrick Lavin, and Blaise Ferraraccio

BACKGROUND AND PURPOSE: Ophthalmoplegic migraine is a rare condition characterized by the association of headaches and an oculomotor nerve palsy. We report six patients with typical clinical features of this disorder in whom enhancement of the cisternal segment of the oculomotor nerve developed during the acute phase, followed by resolution of enhancement over several weeks as the symptoms resolved.

METHODS: Six patients, ages 3 to 27 years, underwent MR imaging during the acute phase of ophthalmoplegic migraine and at the time of recovery several weeks later. The MR studies, performed on a 1.5-T MR unit, included noncontrast and contrast-enhanced axial and coronal T1-weighted sequences. Sagittal images were obtained in two patients, with and without contrast enhancement.

RESULTS: Enhancement of the cisternal segment of the oculomotor nerve was seen in all patients at initial presentation. Contrast-enhanced studies also showed focal thickening at the exit of the nerve in the interpeduncular cistern in five of six patients. No patient had enhancement of the cavernous sinus or adjacent dura. Enhancement was almost completely resolved on follow-up studies 7 to 9 weeks later.

CONCLUSION: Our findings confirm an intrinsic transient abnormality in the cisternal segment of the third nerve in patients with a typical clinical presentation of ophthalmoplegic migraine.

Ophthalmoplegic migraine is a rare condition characterized by the association of headaches and an oculomotor nerve palsy (1, 2). The disease is most common in children and young adults and usually resolves spontaneously (3). Ophthalmoplegic migraine is a diagnosis of exclusion and, in the past, arteriography was required to exclude an aneurysm, whose clinical presentation initially may be indistinguishable from ophthalmoplegic migraine. In 1992 we reported a patient with ophthalmoplegic migraine in whom enhancement of the cisternal segment of the oculomotor nerve was seen during the acute phase on

contrast-enhanced MR images (4). The enhancement resolved several weeks later as the patient's symptoms resolved. A similar case was reported in 1994 (5).

In this article, we report a series of six patients with typical clinical features of ophthalmoplegic migraine who had enhancement of the cisternal segment of the oculomotor nerve during the acute phase, followed by resolution of the enhancement over several weeks as the symptoms resolved. These consistent imaging findings allowed us to formulate hypotheses concerning the pathophysiology of this condition.

Methods

Six patients (four females and two males, ages 3 to 27 years) with typical clinical features of ophthalmoplegic migraine underwent contrast-enhanced MR imaging during the acute presentation and at the time of recovery several weeks later. One of the patients was included in a previous report (4). The patients' clinical findings are summarized in the Table. All patients had at least one prior episode of headache and oculomotor nerve palsy, which resolved spontaneously. Cerebral angiography was performed in one patient to exclude an aneurysm.

Received April 1, 1998; accepted August 3.

From Washington Hospital Center, Washington, DC (A.S.M., M.K.); Bruges General Hospital, Belgium (J.C.); Walter Reed Medical Center, Washington, DC (D.B.); La Source Clinic, Lausanne, Switzerland (J.S.); and Vanderbilt University Medical Center, Nashville, TN (T.C.L., P.L., B.F.).

Address reprint requests to Alexander S. Mark, MD, Department of Radiology, Washington Hospital Center, 110 Irving St NW, Washington, DC 20010.

Clinical Findings in Six Patients with Ophthalmoplegic Migraine

Case	Age (y)/Sex	No. of Prior Episodes	MR Findings in Cranial Nerve III
1	27/F	2	Focal thickening and enhancement
2	8/F	1	Focal thickening and enhancement
3	12/M	2	Focal thickening and enhancement
4	5/F	2	Focal thickening and enhancement
5	3/M	2	Whole nerve thickening and enhancement*
6	23/F	1	Focal thickening and enhancement; normal angiographic findings

* Symptoms resolved after 3 weeks of steroids.

The MR studies were performed on different high-field-strength (1.5-T) systems and included noncontrast and contrast-enhanced axial and coronal T1-weighted images. Noncontrast and contrast-enhanced sagittal images were available in two patients.

Results

Enhancement of the cisternal segment of the oculomotor nerve was seen in all patients at the time of the initial presentation. Focal thickening of the nerve itself was seen on the noncontrast studies, and further thickening was present on the contrast-enhanced images in the area of the exit zone of the nerve in the interpeduncular cistern (Figs 1–5). None of the patients had enhancement of the cavernous sinus or adjacent dura. The follow-up study was performed 7 to 9 weeks after the first study, when the symptoms had resolved in all patients, and demonstrated almost complete resolution of the enhancement. Minimal faint residual enhancement was seen in all patients at the exit of the oculomotor nerve from the cerebral peduncle.

Discussion

Ophthalmoplegic migraine is a rare syndrome consisting of the association of headache and an oculomotor nerve paralysis in the absence of an identifiable cause, typically occurring in children (6) and

young adults. A painless variant of this syndrome has been described in children (7). Because of the self-limiting nature of this disease, there are no pathologic correlates and the pathogenesis of this syndrome remains obscure. Thus, we can only speculate about its cause based on the clinical and radiologic information available.

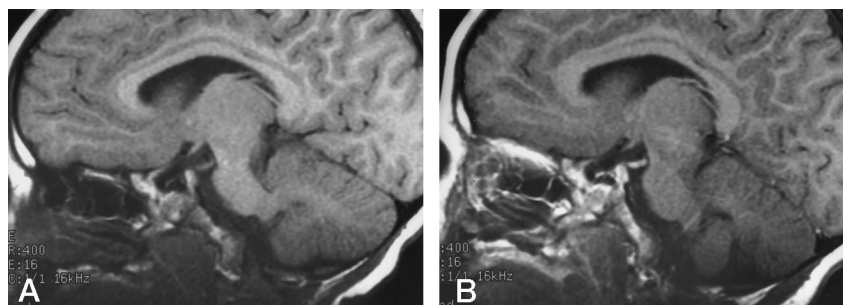
The earliest report of imaging findings in ophthalmoplegic migraine described angiographic abnormalities in a patient in whom angiography was performed to exclude an aneurysm, and this might be a diagnostic consideration, at least at the time of the first episode (8). Reports of narrowing of the carotid artery (9) in the cavernous sinus and of segmental narrowing of the basilar artery (10) had appeared prior to the development of CT. The CT findings in ophthalmoplegic migraine were generally unremarkable. In one report (11), CT studies revealed an enhancing mass at the level of the exit zone of the third nerve, which was shown by angiography to represent a vascular malformation. This patient had a long history of ophthalmoplegic migraine (60 to 70 episodes) and, since age 7, was left with a residual oculomotor paresis, an unusual finding in typical ophthalmoplegic migraine, which recurs much less frequently and resolves without sequelae.

Our study is one of the largest series to date, and confirms an intrinsic transient abnormality in the cisternal segment of the third nerve in patients with a typical clinical presentation of ophthalmoplegic migraine. Unlike the facial nerve, which may enhance in a majority of patients owing to its richly vascular perineurium (12), the oculomotor nerve never enhances normally (4). The fact that enhancement disappears within several weeks as the patient's symptoms resolve is a strong indication that the clinical symptoms and the radiologic abnormality are related. The following review of additional causes of enhancement of the oculomotor and other cranial nerves may suggest a possible pathogenesis for this syndrome.

Enhancement of the cisternal portion of the oculomotor nerve can occur in a variety of neoplastic and inflammatory and infiltrative conditions. Such neoplastic conditions may be benign (schwannomas, hemangiomas) or malignant (lymphoma, leukemia, and carcinomatous meningitis) (13). None of these conditions, however, would resolve spontaneously, and none of our patients had evidence of an underlying malignancy.

Fig 1. Case 5: 3-year-old boy with two prior episodes of spontaneously resolving oculomotor nerve palsy.

A and B, Sagittal T1-weighted MR images before (A) and after (B) contrast administration show diffuse thickening and enhancement of the oculomotor nerve. The symptoms resolved spontaneously in 6 weeks.



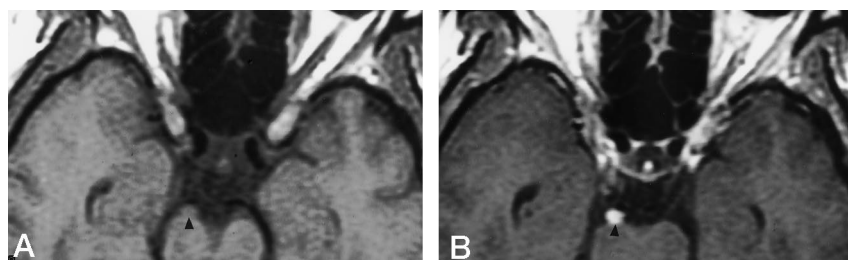


FIG 2. Case 1: 27-year-old woman with two prior episodes of headache and oculomotor nerve palsy.

A and B, Axial noncontrast (A) and contrast-enhanced (B) T1-weighted images show focal nodular enhancement of the exit zone of the oculomotor nerve (arrow-head). Follow-up study showed virtually complete resolution of the enhancement.

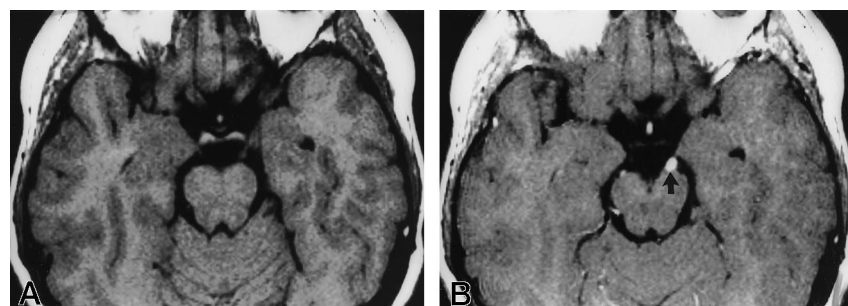


FIG 3. Case 3: 12-year-old boy with two prior episodes of ophthalmoplegic migraine.

A and B, Axial T1-weighted MR images before (A) and after (B) contrast administration show enhancement of the oculomotor nerve (arrow, B) and thickening of its root entry zone. Follow-up studies showed virtually complete resolution of the enhancement.

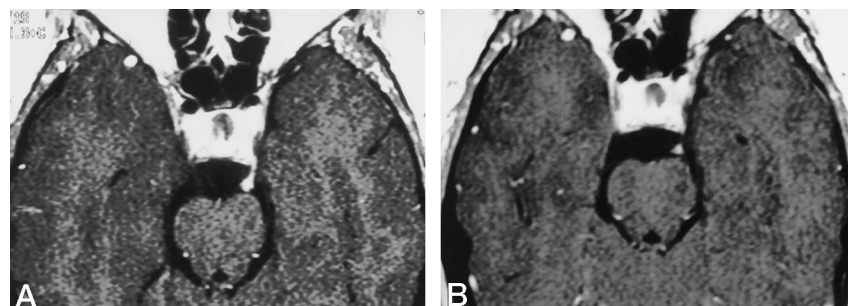


FIG 4. Case 6: 23-year-old woman with one prior episode of ophthalmoplegic migraine.

A, Axial T1-weighted contrast-enhanced MR image shows enhancement of the oculomotor nerve and thickening of its root entry zone.

B, Follow-up study shows virtually complete resolution of the enhancement.

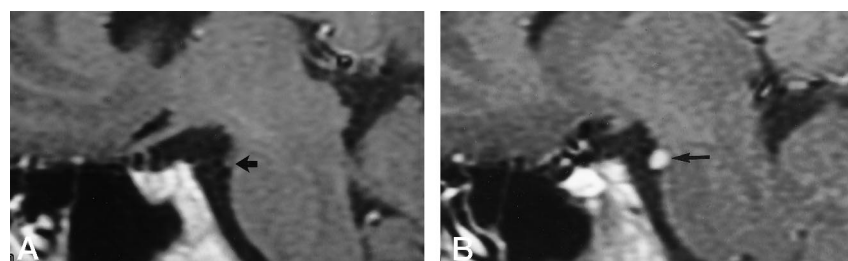


FIG 5. Case 2: 8-year-old girl with one prior episode of spontaneously resolving oculomotor nerve palsy.

A and B, Sagittal T1-weighted MR image before (A) and after (B) contrast administration show focal thickening and enhancement of the root exit zone (arrow). The symptoms resolved spontaneously within 6 weeks.

Enhancement of the oculomotor nerve can also occur in a variety of both infectious and noninfectious inflammatory conditions. It has been described in neuroborreliosis (14, 15) syphilis (16, 17), coccidioidomycosis, and HIV infection (HIV-related neuritis). All our patients underwent extensive infectious work-up (four of them had CSF analysis) and no evidence of an obvious infection was noted. HIV testing was not performed, but none of the patients had any risk factors, and it would be highly unlikely that any infection (other than a benign viral infection) would resolve spontaneously without treatment. In the one reported case of HIV neuritis involving the oculomotor nerve, resolution of the enhancement was noted after AZT therapy (4).

Finally, we have seen enhancement of the oculo-

motor nerve in noninfectious inflammatory disorders, such as sarcoidosis and Tolosa-Hunt syndrome, and in demyelinating conditions, such as Fisher syndrome (16). In these patients, resolution of the enhancement was noted after treatment with steroids. While not impossible, it is highly unlikely that sarcoid lesions would resolve spontaneously in the CNS. Even though a case of sarcoidosis presenting with frequent recurrence of ophthalmoplegia has recently been reported (18), none of our patients had other manifestations of CNS or peripheral sarcoidosis. Similarly, none of our patients had MR findings suggestive of cavernous sinus involvement (Tolosa-Hunt syndrome) or clinical evidence of Fisher syndrome.

Vascular lesions, while not reported to cause enhancement of the cisternal segment of the oculo-

tor nerve, deserve particular consideration because of the possibility of an aneurysm masquerading as ophthalmoplegic migraine in young patients. Aneurysms are extremely unusual in children but have occasionally been reported. In fact, in one of the reports, the initial diagnostic consideration in an 11-year-old boy was ophthalmoplegic migraine. MR imaging can be helpful in the diagnosis of intracranial aneurysms, especially with the use of MR angiography. However, the study would show compression of the third nerve by the aneurysm rather than enhancement of the oculomotor segment. While an aneurysm may be a consideration at the time of the first episode, the recurrent nature of this syndrome would make an aneurysm much less likely. An arteriovenous malformation, as reported by Imes et al (11), can certainly produce a clinical picture of recurrent headaches and oculomotor nerve palsy mimicking ophthalmoplegic migraine. A true arteriovenous malformation would be highly unlikely to regress spontaneously and, furthermore, there was no evidence of flow at the root entry zone in any of our patients. A cavernous hemangioma could theoretically present as a small enhancing mass at the base of the third nerve, and we have encountered a patient with a surgically proved cavernous hemangioma in the anterior aspect of the third nerve at the level of its entrance in the cavernous sinus. However, in this patient, the clinical presentation was that of a permanent oculomotor nerve palsy. Ischemia of the oculomotor nerve has been proposed as a cause of ophthalmoplegic migraine. Our experience with MR imaging in diabetic oculomotor nerve palsy (16), which is thought to be due to a microvascular infarct of the nerve itself, revealed no enhancement in the oculomotor nerve, and for this reason, we believe ischemia is an unlikely cause of ophthalmoplegic migraine.

A benign viral infection affecting the oculomotor nerve seems an attractive hypothesis because it can explain both the imaging and clinical findings as well as the spontaneous resolution over a couple of weeks. Indeed, the similarity with enhancement of the seventh cranial nerve (19, 20) seen in patients with Bell's palsy (21), which is considered a form of viral neuritis (that may recur) is striking. Based on the available clinical and radiologic information, we believe that a benign viral or idiopathic inflammatory neuropathy is the most likely underlying cause in the majority of patients with the clinical syndrome of ophthalmoplegic migraine. This theory could also explain the narrowing of the carotid and basilar arteries described in earlier reports. We believe the vasospasm was the consequence of the adjacent inflammatory process responsible for the ophthalmoplegic migraine rather than the cause of the migraine.

It is possible that other diseases, such as a vascular malformation (22), sarcoidosis, pituitary apoplexy (23), and chronic inflammatory demyelinating polyneuropathy (24), may have a similar clinical presentation; however, it should be possible to exclude them on the basis of a combination of MR imaging

and laboratory findings. In the future, correlation with viral studies may shed additional light on this condition.

Conclusion

Our study strongly suggests that contrast-enhanced MR imaging (and MR angiography) (25) rather than conventional angiography should be the initial imaging study in patients with oculomotor nerve palsy involving the pupil; this is especially true in children and young adults, in whom the prevalence of aneurysms is lower. If MR images show enhancement of the cisternal segment of the oculomotor nerve, further imaging may not be necessary. Careful clinical evaluation and spinal tap are necessary to exclude such diseases as lymphoma, leukemia, or infectious disorders. If such studies are negative, a tentative diagnosis of ophthalmoplegic migraine can be made, and follow-up clinical and MR studies may be adequate. If no obvious lesion of the third nerve is seen and MR angiography is negative, a conventional arteriogram may still be necessary to completely exclude an aneurysm, especially in elderly patients.

References

1. Friedman A, Harter D, Merritt H. **Ophthalmoplegic migraine.** *Arch Neurol* 1962;7:320-327
2. Bailey TD, O'Connor PS, Tredici TJ, Shacklett DE. **Ophthalmoplegic migraine.** *J Clin Neuroophthalmol* 1984;4:225-228
3. Miller NR. *Walsh and Hoyt's Clinical Neuro-ophthalmology.* 4th ed. Baltimore: Williams & Wilkins; 1988;3:1546-1547
4. Mark AS, Blake P, Atlas SW. **Enhancement of the third nerve on GAD-MRI Clinical and pathological correlation.** *AJNR Am J Neuroradiol* 1992;13:1463-1470
5. Stommel EW, Ward TN, Harris RD. **MRI findings in a case of ophthalmoplegic migraine.** *Headache* 1993;33:234-237
6. Miller NR. **Solitary oculomotor nerve palsy in childhood.** *Am J Ophthalmol* 1977;83:106-110
7. Durkan GP, Troost BT, Slamovits TL, Spoor TC, Kennerdell JS. **Recurrent painless oculomotor palsy in children: a variant of ophthalmoplegic migraine?** *Headache* 1981;21:58-62
8. Trobe JD. **Isolated third nerve palsies.** *Semin Neurol* 1986;6:135-141
9. Walsh JP, O'Doherty DS. **A possible explanation of the mechanism of ophthalmoplegic migraine.** *Neurology* 1960;10:1079-1084
10. Vijayan N. **Ophthalmoplegic migraine: ischemic or compressive neuropathy?** *Headache* 1980;20:300-304
11. Imes RK, Monteiro ML, Hoyt WF. **Ophthalmoplegic migraine with proximal posterior cerebral artery vascular anomaly.** *J Clin Neuroophthalmol* 1984;4:221-223
12. Gebarski SS, Telian SA, Niparko K. **Enhancement along the normal facial nerve in the facial canal: MR imaging and anatomic correlation.** *Radiology* 1992;183:391
13. Davis PC, Friedman NC, Fry SM, et al. **Leptomeningeal metastases: MR imaging.** *Radiology* 1987;163:449-454
14. Nelson JA, Wolfe MD, Yuh WT, Peeples ME. **Cranial nerve involvement with Lyme borreliosis demonstrated by magnetic resonance imaging.** *Neurology* 1992;42:671-673
15. Pachner AR, Duray P, Steere AC. **Central nervous system manifestations of Lyme disease.** *Arch Neurol* 1989;46:790-795
16. Blake PY, Mark AS, Kattah J, Kolsky M. **MR of oculomotor nerve palsy.** *AJNR Am J Neuroradiol* 1995;16:241-251
17. Schmitt T, Erbguth F, Taghavi A. **Oculomotor paralysis as the leading symptom of meningovascular syphilis: report of two patients and review of the literature.** *Nervenarzt* 1993;64:668-672
18. Joko M, Yasuda H, Terada M, Kikkawa R, Shigeta Y. **A case of sarcoidosis with frequent recurrence of ophthalmoplegia.** *Rinsho Shinkeigaku* 1994;34:882-885

19. Sartoretti-Schefer S, Wichmann W, Valavanis A. **Idiopathic, herpetic, and HIV-associated facial nerve palsies: abnormal MR enhancement patterns.** *AJNR Am J Neuroradiol* 1994;15:479
20. Daniels DL, Czervone LP, Pojunas KW, et al. **Facial nerve enhancement in MR imaging.** *AJNR Am J Neuroradiol* 1987;8:605–607
21. May M. **Idiopathic (Bell's) palsy, herpes zoster and other facial nerve disorders of viral origin.** In: *The Facial Nerve*. New York: Thieme Medical; 1986:365–399
22. Brazis PW, Copobianco DJ, Chang FL, McLeish WM, Earnest F IV. **Low flow dural arteriovenous shunt: another cause of "sinister" Tolosa-Hunt syndrome.** *Headache* 1994;34:523–525
23. Silvestrini M, Matteis M, Cupini LM, Troisi E, Bernardini G, Floris R. **Ophthalmoplegic migraine-like syndrome due to pituitary apoplexy.** *Headache* 1994;34:484–486
24. Ryo M, Saito T, Kunii N, Hasegawa H, Kowa H. **A case of chronic inflammatory demyelinating polyneuropathy with recurrent ophthalmoplegia, persistent conduction block, antibody activity against gangliosides GM1.** *Rinsho Shinkeigaku* 1994;34:702–706
25. Masaryk TJ, Modic MT, Ross JS, et al. **Intracranial circulation: preliminary clinical results with three dimensional (volume) MR angiography.** *Radiology* 1989;171:793–799