



**Providing Choice & Value**

Generic CT and MRI Contrast Agents



**FRESENIUS  
KABI**

**CONTACT REP**

**AJNR**

**Isolated vagal nerve palsy associated with a dissection of the extracranial internal carotid artery.**

A O Nusbaum, P M Som, P Dubois and A R Silvers

*AJNR Am J Neuroradiol* 1998, 19 (10) 1845-1847

<http://www.ajnr.org/content/19/10/1845>

This information is current as  
of July 15, 2025.

# Isolated Vagal Nerve Palsy Associated with a Dissection of the Extracranial Internal Carotid Artery

Annette O. Nusbaum, Peter M. Som, Philip Dubois, and Adam R. Silvers

**Summary:** A 40-year-old man had paralysis of the right vocal cord. Imaging showed a dissection of the extracranial internal carotid artery, and physical examination disclosed paresis of the right side of the soft palate. To our knowledge, this is only the second report of carotid dissection presenting as an isolated vagal neuropathy. Most often, multiple lower cranial nerves are involved. The CT, MR imaging, and MR angiographic findings are presented and the topic is reviewed.

In most patients who have a vocal cord paralysis, the imaging workup is unrevealing and the paralysis is considered idiopathic in nature (1). Among the various causes of isolated recurrent nerve and vagal paralysis that have been described, dissection of the extracranial internal carotid artery (ICA) is rare; to our knowledge, only one previous case has been reported (2). This reflects the fact that in most patients with a carotid dissection, multiple lower cranial nerves (IX, X, XI, XII) are involved, in a variety of combinations (3). If the dissection extends intracranially, ocular motor palsies are common (4). In this article, we describe the CT, MR imaging, and MR angiographic findings in a 40-year-old man with a dissection of the extracranial right ICA who had an isolated right vagal paresis that initially presented as a right vocal cord paralysis. The various causes of vagal neuropathy and of dissections of the extracranial ICA are discussed.

## Case Report

A 40-year-old man was admitted to the emergency department with acute onset of a right-sided temporal headache, a pounding sensation in the right side of the neck, and right-sided pulsatile tinnitus. His blood pressure was elevated (150/100) and he reported being noncompliant with his medications for hypertension, which had been diagnosed 2 years earlier. He had no recent history of neck trauma, but he had had surgical repair of a left iliac aneurysm. His blood pressure was controlled in the emergency department, and he was discharged home. His headache and other symptoms improved; however,

several days later he noted a hoarse voice. He went to an otolaryngologist, who discovered a right vocal cord paralysis and sent the patient for a CT scan of the neck to identify the cause of this paralysis. On physical examination, some weakness of the right side of the soft palate was noted; however, the other cranial nerves were intact. In particular, the remaining lower cranial nerve functions, including gag reflex, shoulder shrug, and tongue protrusion, were intact. The carotid pulses were symmetric and without bruits. The remainder of the physical examination was unremarkable. A CT scan of the neck showed an ovoid collection of low-attenuation material surrounding the right ICA (Fig 1A). The lesion was largest at the skull base and tapered down to the level of the carotid bifurcation. The patent, but narrowed, artery was seen within this area. MR imaging and 2D time-of-flight MR angiography showed a long segment of irregular luminal narrowing involving the right ICA from just above the bifurcation to the level of the skull base (Fig 1B–D). Axial T1- and T2-weighted images showed eccentric high signal intensity, inseparable from the vessel wall, at the level of narrowing, consistent with intramural hematoma secondary to the dissection. No intracranial disease was present. An echocardiogram was normal, and a Doppler sonogram of the carotid arteries showed no evidence of atherosclerotic plaque, vascular obstruction, or carotid dissection.

The patient was admitted to the intensive care unit for monitoring and was placed on intravenous heparin and subsequently on warfarin for anticoagulation. While in the hospital, the patient's blood pressure was adequately controlled by medication; he had no dysphagia, his gag reflex was intact bilaterally, and his hoarseness improved moderately. He was discharged after 6 days on blood pressure medication and warfarin.

## Discussion

Isolated vagal nerve palsy is a rare presentation of dissection of the extracranial ICA (2). When a cause can be identified, most cases of vocal cord paralysis are secondary to either a tumor or a prior surgical procedure (5). An understanding of the course of the vagus nerve is important in determining the cause of vagal nerve palsy. The vagus nerve exits the base of the skull through the jugular foramen and then runs within the posterior aspect of the carotid sheath between the ICA (medially) and the internal jugular vein (laterally) (6). In the present case of dissection of

Received January 22, 1998; accepted after revision April 29.

From the Departments of Radiology (A.O.N., P.M.S., A.R.S.) and Otolaryngology (P.M.S.), Mount Sinai School of Medicine, City University of New York; and the Department of Radiology of the Mater Private Hospital, South Brisbane, Australia (P.D.).

Address reprint requests to Peter M. Som, MD, Department of Radiology, Mount Sinai Hospital, One Gustave L. Levy Place, New York, NY 10029.

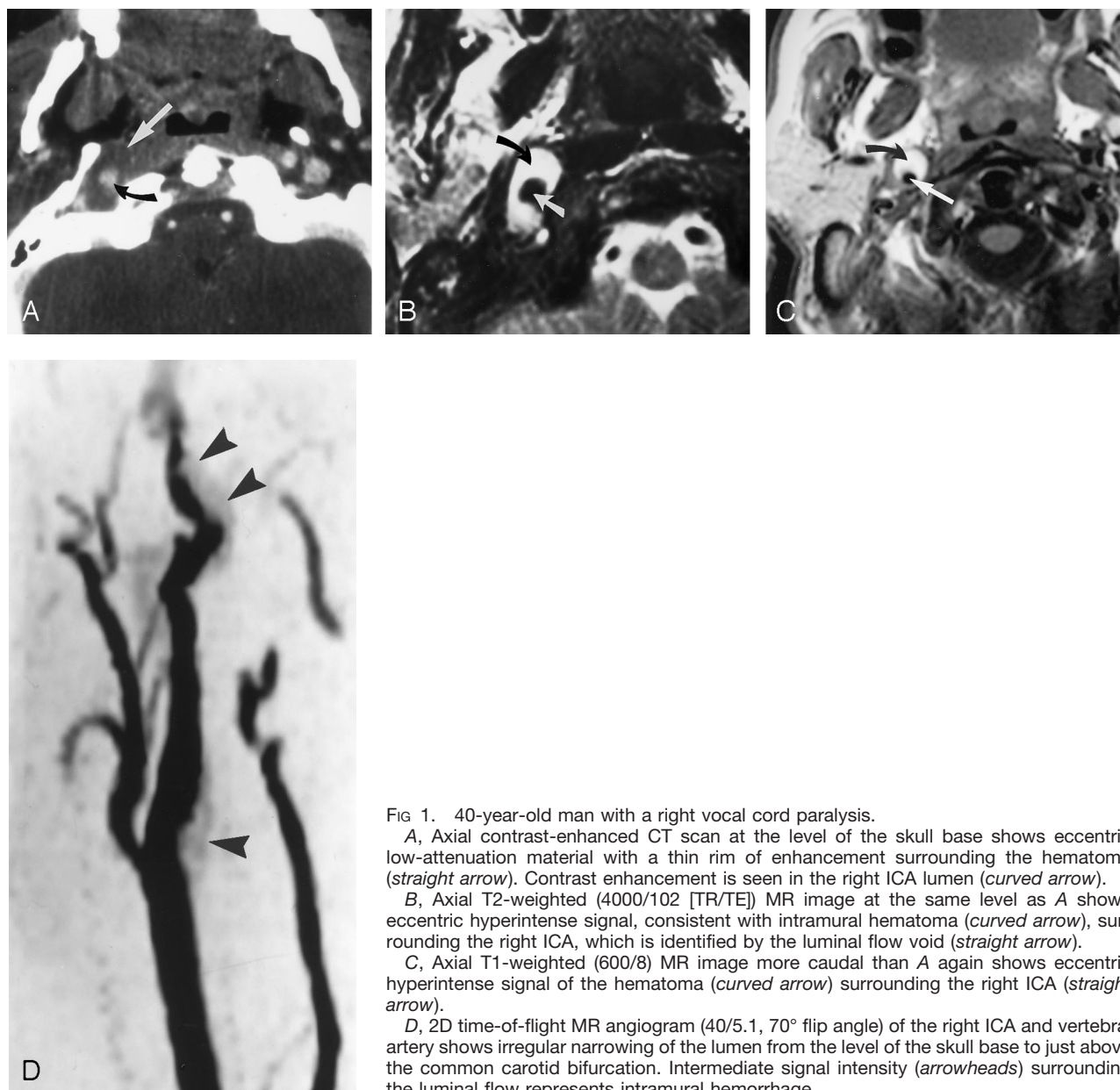


FIG 1. 40-year-old man with a right vocal cord paralysis.

A, Axial contrast-enhanced CT scan at the level of the skull base shows eccentric low-attenuation material with a thin rim of enhancement surrounding the hematoma (straight arrow). Contrast enhancement is seen in the right ICA lumen (curved arrow).

B, Axial T2-weighted (4000/102 [TR/TE]) MR image at the same level as A shows eccentric hyperintense signal, consistent with intramural hematoma (curved arrow), surrounding the right ICA, which is identified by the luminal flow void (straight arrow).

C, Axial T1-weighted (600/8) MR image more caudal than A again shows eccentric hyperintense signal of the hematoma (curved arrow) surrounding the right ICA (straight arrow).

D, 2D time-of-flight MR angiogram (40/5.1, 70° flip angle) of the right ICA and vertebral artery shows irregular narrowing of the lumen from the level of the skull base to just above the common carotid bifurcation. Intermediate signal intensity (arrowheads) surrounding the luminal flow represents intramural hemorrhage.

the ICA, the most likely pathogenesis for the palsy was compression or stretching of the nerve by intramural hemorrhage at the unyielding skull base. A less likely possibility was either a transient or a permanent interruption of the blood supply to the cranial nerve (7).

Mokri et al (7) found that cranial nerve palsy was present in 12% of 190 adults with spontaneous dissection of the extracranial ICA. Of these patients with cranial nerve findings, 65% had isolated cranial nerve palsy, most commonly involving cranial nerve V.

Two distinct syndromes of cranial nerve palsy have been recognized in association with dissection of the ICA: ocular motor palsies (III, IV, VI) and lower cranial nerve palsies (IX, X, XI, XII) (3, 4). Although these lower cranial nerves can be affected in multiple combinations, cranial nerve XII is almost always involved, frequently in association with an ipsilateral

headache. When the dissection involves the cavernous portion of the ICA, ocular motor palsy is seen.

Dissection of the ICA is recognized as a common cause of ischemic stroke in young adults, occurring in approximately 10% to 20% of this population (8). The most common clinical presentation is headache, but a focal neurologic deficit is also a frequent presenting symptom (3). In the majority of patients, the dissection involves the extracranial portion of the ICA and only infrequently extends intracranially or involves the intracranial segment alone. The pathogenesis of spontaneous dissection of the ICA is broad and includes minor trauma, fibromuscular dysplasia, Marfan syndrome, cystic medial necrosis, idiopathic regressing arteriopathy, type IV Ehlers-Danlos syndrome, hypertension, ICA redundancy, and  $\alpha_1$ -antitrypsin deficiency (9–12). The presumption that there

is preexisting arterial disease that predisposes cervical arteries to dissection is supported by reports of intracranial aneurysms associated with spontaneous cervical artery dissection, a familial association of intracranial aneurysms and cervical artery dissection, a familial occurrence of cervical artery dissection, and an occurrence of multivessel dissection (12).

The traditional method of imaging cervical cephalic arterial dissection has been catheter angiography, in which findings may include smooth or slightly irregular luminal narrowing, pseudoaneurysm, intimal flap, or distal branch occlusions secondary to embolization (13). CT and MR imaging provide noninvasive means of diagnosing arterial dissection, and findings on each of these studies include an eccentric rim of mural thickening surrounding a narrowed lumen. On CT scans, the intramural hemorrhage usually is hypodense relative to muscle and a thin rim of enhancement may be seen around the hematoma, presumably representing enhancement of the vasa vasorum (14). On MR images, the eccentric or circumferential periarterial rim of intramural hematoma typically shows hyperintense signal on T1- and T2-weighted images (13). The usefulness of MR angiography in the diagnosis of dissection is limited; probably the most useful MR sequence is fat-suppressed axial T1-weighted images with inferior saturation pulses (15).

Duplex sonography is less reliable than angiography and MR imaging, primarily because the dissection is usually distal to the region that can be seen well on sonograms. Sonographic findings may include an echogenic intimal flap or echogenic thrombus, and Doppler waveforms may show a highly resistive, obstructive pattern (16).

### Conclusion

The significance of this case lies in the recognition that a carotid dissection may be the cause of an isolated vagal neuropathy in a young patient. At our institution, if the origin of cranial nerve disease is thought to lie above the level of the oropharynx, contrast-enhanced MR imaging is the initial examination of choice. However, if the disease is thought to be caudal to this level (eg, recurrent laryngeal nerve),

contrast-enhanced CT is the preferred imaging method. In this particular case, the diagnosis was made on both CT and MR studies; however, in the presence of such clinical symptoms as neck pain or headache, MR imaging may be the best method for detecting an isolated carotid artery dissection. Since embolic stroke is a frequent complication of cervicocephalic arterial dissection, early diagnosis is important so that anticoagulant therapy can be promptly instituted and ischemic complications prevented.

### References

1. Berry H, Blair R. **Isolated vagus nerve palsy and vagal mononeuritis.** *Arch Otolaryngol* 1980;106:333-338
2. Davies L. **A case of vagal palsy due to dissecting aneurysm of the carotid artery.** *Med J Aust* 1987;147:352-353
3. Mokri B, Schievink W, Olsen K, Piepgras D. **Spontaneous dissection of the cervical internal carotid artery: presentation with lower cranial nerve palsies.** *Arch Otolaryngol Head Neck Surg* 1992;118:431-435
4. Schievink W, Mokri B, Garrity J, Nichols D, Piepgras D. **Ocular motor nerve palsies in spontaneous dissections of the cervical internal carotid artery.** *Neurology* 1993;43:1938-1941
5. Kearsley J. **Vocal cord paralysis (VCP): an aetiological review of 100 cases over 20 years.** *Aust N Z J Med* 1981;11:663-666
6. Reede D. **Brachial plexus.** In: Som P, Curtin H, eds. *Head and Neck Imaging*. 3rd ed. St Louis: Mosby; 1996;2:985-988
7. Mokri B, Silbert P, Schievink W, Piepgras D. **Cranial nerve palsy in spontaneous dissection of the extracranial internal carotid artery.** *Neurology* 1996;46:356-359
8. Bogousslavsky J, Regli F. **Ischemic stroke in adults younger than 30 years of age.** *Arch Neurol* 1987;44:479-482
9. Mokri B, Houser O, Sundt T. **Idiopathic regressing arteriopathy.** *Ann Neurol* 1977;2:466-472
10. Barbour P, Castaldo J, Rae-Grant A, et al. **Internal carotid artery redundancy is significantly associated with dissection.** *Stroke* 1994;25:1201-1206
11. Schievink W, Prakash U, Piepgras D, Mokri B. **Alpha 1-antitrypsin deficiency in intracranial aneurysms and cervical artery dissection.** *Lancet* 1994;343:452-453
12. Schievink W, Mokri B, O'Fallon W. **Recurrent spontaneous cervical-artery dissection.** *N Engl J Med* 1994;330:393-397
13. Houser O, Mokri B, Sundt TS Jr, Baker H, Reese D. **Spontaneous cervical cephalic arterial dissection and its residuum: angiographic spectrum.** *AJNR Am J Neuroradiol* 1984;5:27-34
14. Petro G, Witwer G, Cacayorin E. **Spontaneous dissection of the cervical internal carotid artery: correlation of arteriography, CT, and pathology.** *AJR Am J Roentgenol* 1986;148:393-398
15. Assaf M, Sweeney P, Kosmorsky G, Masaryk T. **Horner's syndrome secondary to angiogram negative, subadventitial carotid artery dissection.** *Can J Neurol Sci* 1993;20:62-64
16. Provenzale J. **Dissection of the internal carotid and vertebral arteries: imaging features.** *AJR Am J Roentgenol* 1995;165:1099-1104