



Discover Generics

Cost-Effective CT & MRI Contrast Agents



WATCH VIDEO

AJNR

The postoperative lumbar spine: evaluation of epidural scar over a 1-year period.

J S Ross, N Obuchowski and R Zepp

AJNR Am J Neuroradiol 1998, 19 (1) 183-186

<http://www.ajnr.org/content/19/1/183>

This information is current as
of June 13, 2025.

The Postoperative Lumbar Spine: Evaluation of Epidural Scar over a 1-Year Period

Jeffrey S. Ross, Nancy Obuchowski, and Richard Zepp

PURPOSE: We documented the morphological changes on enhanced MR imaging studies that occur in epidural scar over a period of 1 year after lumbar discectomy.

METHODS: The study population was culled from a randomized, multicenter clinical trial designed to evaluate the efficacy of a device inhibiting postoperative epidural fibrosis after single-level, unilateral laminectomy/discectomy for herniated lumbar disk. Analysis was restricted to 71 control subjects who did not receive the device. All patients underwent surgery after receiving clinical and MR examinations, with follow-up MR studies at 6 and 12 months. Evaluation of all MR images was performed by one interpreter, who was blinded to treatment arm and clinical findings. The extent of epidural scar seen at the 6- and 12-month MR examinations was graded on a scale of 0 to 4 for each quadrant at each imaging section encompassing the surgical level.

RESULTS: Eighty-five percent of the patients had no change in the amount of anterior epidural scar between the 6- and 12-month MR examinations; 75% of the patients showed no change in the amount of posterior epidural scar between the 6- and 12-month examinations.

CONCLUSION: The majority of our patients had no change in the amount of epidural scarring visible at enhanced MR imaging over a 1-year period after lumbar laminectomy/discectomy.

Little attention has been paid to the imaging appearance over time of lumbar epidural scar tissue that may occur after surgery for disk disease. This lack of study most likely relates to the impression that scar tissue is relatively static compared with the surgically important distinction of residual or recurrent herniation and/or bony stenosis. Reoperation solely to remove epidural scar is considered contraindicated, since the surgery would cause formation of more scar tissue (1). Recently, epidural scar has been shown to correlate with an increased amount of recurrent radicular pain following lumbar laminectomy and discectomy (2). Further, devices are being evaluated in Europe as well as in the United States that may segmentally modulate scar formation after surgery. The possibility of focally limiting epidural scar formation while maintaining healing of the more posterior surgical site necessitates a more thorough understanding of the natural history of epidural fibrosis if meaningful comparisons are to be made in clinical

trials. The purpose of our study was to document the morphological changes in epidural scar seen on magnetic resonance (MR) images over a period of 1 year after lumbar discectomy. The hypothesis tested was whether the amount of epidural scar seen 6 months after surgery was equal to the amount of scar seen 12 months after surgery.

Methods

Clinical Study Design

The study population has been reported in detail elsewhere (2). Briefly, the subjects were culled from a randomized, double-blind, controlled, multicenter clinical trial to evaluate the safety and effectiveness of ADCON-L (Gliatech, Inc, Cleveland, Ohio), a device designed to prevent epidural fibrosis and dural adhesions after single-level unilateral laminectomy/discectomy for lumbar disk herniation. Clinical assessments were conducted preoperatively and at 1, 3, 6, and 12 months after surgery. MR imaging studies of the lumbar spine were obtained without and with contrast enhancement (gadopentetate dimeglumine or equivalent, 0.1 mmol/kg) before and at 6 and 12 months after surgery. Analysis for the present study was restricted to 71 control patients from this trial who did not receive the device.

MR Imaging Evaluation

MR imaging studies were performed on commercial superconducting units using an 8-inch elliptical spine surface coil or its equivalent. MR imaging examinations followed a standard protocol at each clinical site as follows: two-dimensional axial

Received August 2, 1996; accepted after revision June 30, 1997.
Presented at the annual meeting of the American Society of Neuroradiology, Seattle, Wash, June 1996.

This work was funded by Gliatech, Inc, Cleveland, Ohio.
From the Division of Radiology, Desk L-10, Cleveland Clinic Foundation, 9500 Euclid Ave, Cleveland, OH 44195. Address reprint requests to Jeffrey S. Ross, MD.

T1-weighted spin-echo sequences and sagittal T1- and T2-weighted spin-echo sequences before contrast administration; administration of 0.1 mmol/kg contrast material via slow intravenous push; and axial and sagittal T1-weighted spin-echo sequences after administration of contrast material, completed within 20 minutes of injection.

Axial images were obtained in a gap-and-fill fashion to allow complete coverage of the surgical site and were contiguous (ie, not only disk space levels). Axial images covered at least one level above the surgical site to one level below. Fat saturation was not used.

All MR images were evaluated by one interpreter, who was blinded to clinical findings and treatment. For the purpose of evaluating epidural fibrosis, only the axial T1-weighted images with and without contrast enhancement were used.

The MR imaging evaluation detailed the location of epidural fibrosis on five contiguous axial sections centered on the intervertebral disk (Fig 1). Each of the five levels was further subdivided into four quadrants defined by perpendicular lines drawn from the central aspect of the thecal sac. The posterior

margin of the epidural evaluation site (at the laminectomy level) was defined by a line drawn between the most posterior aspects of the remaining bony lamina to exclude the scar along the more superficial surgical tract. The extent of epidural fibrosis was graded on a scale of 0 to 4 for each quadrant at each imaging section encompassing the surgical level (0 = no/trace scar; 1 = >0% and ≤25% filled with scar; 2 = >25% and ≤50% filled with scar; 3 = >50% and ≤75% filled with scar; and 4 = >75% and ≤100% of quadrant filled with scar).

Wilcoxon's signed-rank test was used to test the hypothesis for scar both dorsal and ventral to the thecal sac.

Results

For scar within the anterior epidural space at the 6-month time point, 4% of patients had a score of 0, 10% a score of 1, 14% a score of 2, 23% a score of 3, and 49% a score of 4. Posteriorly at the 6-month time point, 14% had a score of 0, 8% a score of 1, 23% a score of 2, 24% a score of 3, and 31% a score of 4.

Eighty-five percent of the patients had no change in the amount of anterior epidural scar between the 6- and 12-month examinations. The remaining 15% had a decrease in scar at 12 months (Figs 2 and 3). Seventy-five percent of the patients had no change in the amount of posterior epidural scar between the 6- and 12-month examinations. The remaining 25% had a decrease in scar at 12 months. Anteriorly, the overall average difference in scores between 6 and 12 months was 0.17 (SD, 0.41); this difference is statistically different from zero ($P = .001$). For the subgroup of patients with a change in scar anteriorly, the average difference was 1.09 (SD, 0.30). Posteriorly, the average difference in score between 6 and 12 months was 0.44 (SD, 0.89); this difference is also statistically different from zero ($P < 0.001$). For the subgroup of patients with a change in scar posteriorly, the average difference was 1.72 (SD, 0.96).

Within the anterior epidural space, there was no apparent relationship between the extent of scar at 6 months and whether the scar decreased by 12 months. However, posteriorly, there was a trend in which the more scar present at 6 months, the more likely it was to decrease by 12 months. The probability that the amount of scar would decrease by 12 months was 17% for patients with a 6-month score of 1, 19% with a

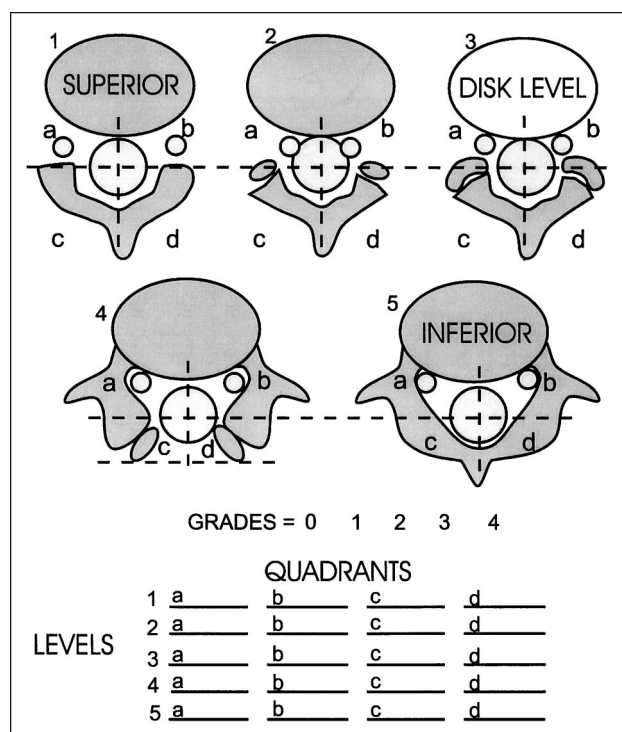
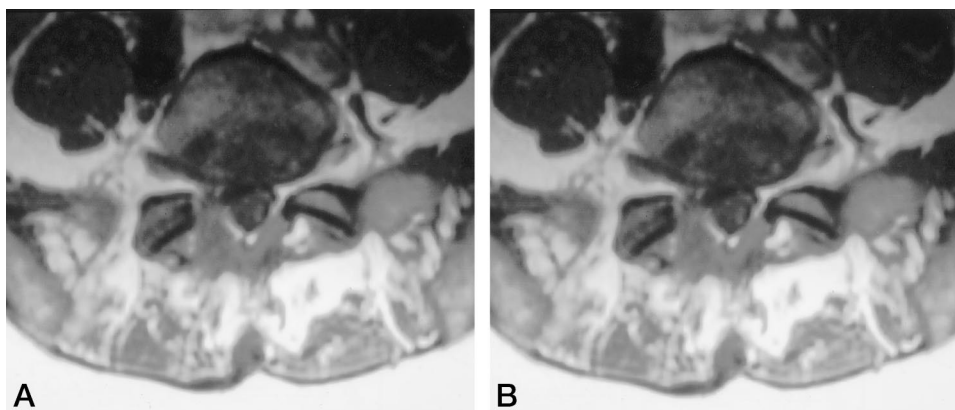


FIG 1. Schematic for scoring of epidural scar by dividing each of five levels into four quadrants centered on the thecal sac.

FIG 2. No change in epidural scar score between 6-month (A) and 12-month (B) MR examinations. The right posterior score is 4 for both images.



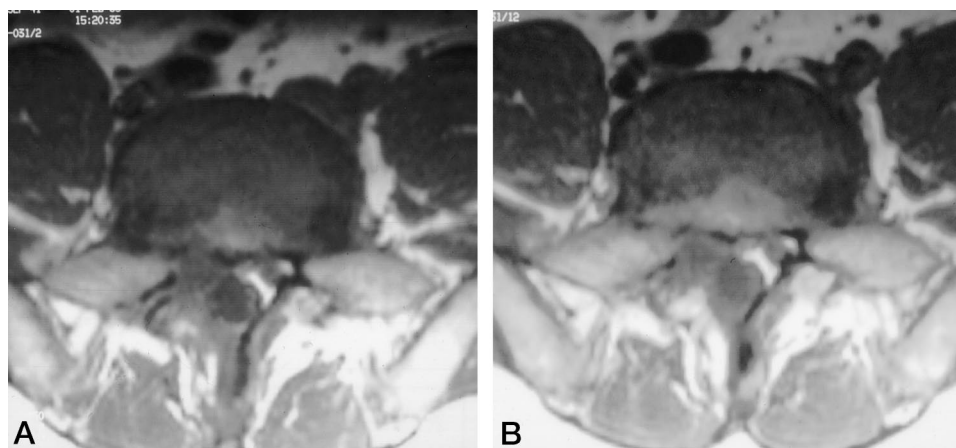


FIG 3. Axial T1-weighted images show right posterior grade-4 scar at 6 months (A), which changes to grade 2 at 12 months (B). The right anterior epidural space was grade 4 at both 6 and 12 months.

6-month score of 2, 24% for a 6-month score of 3, and 45% for patients with a 6-month score of 4.

The size of the original disk herniation was not associated with the amount of scar present anteriorly at 6 months (Spearman correlation, $r = -.01$; $P = .924$), the amount of scar present posteriorly at 6 months ($r = -.09$, $P = .480$), the presence/absence of scar reduction anteriorly ($P = .480$), or the presence/absence of scar reduction posteriorly ($P = .717$). Similarly, the type of surgery was not associated with the amount of scar present anteriorly at 6 months (Wilcoxon's test, $P = .513$), the amount of scar present posteriorly at 6 months ($P = .257$), the presence/absence of scar reduction anteriorly (Fisher's Exact Test, $P = 1.0$), or the presence/absence of scar reduction posteriorly ($P = .763$).

Discussion

Lumbar epidural scar may occur after lumbar discectomy, replacing the normal epidural fat with fibrotic tissue and binding the dura and nerve roots to the surrounding structures. The literature provides both basic scientific and clinical evidence that scar tissue may lead to postoperative symptoms. Nerve fibers that are encased in scar tissue are subject to increased tension, impaired axoplasmic transport, and restricted arterial supply and venous return. Spinal nerve roots and dorsal root ganglia are sensitive to mechanical deformation, and compression of nerve tissue can cause such symptoms as pain, muscle weakness, and numbness (3, 4). There is evidence that epidural scar formation after disk surgery contributes to poor outcome and recurrent symptoms (5–11). North et al (9) reported that favorable outcome was associated with absence of epidural scar requiring surgical lysis. Hurme et al (6) examined 40 patients 5 years after surgery for herniated lumbar disk and found that an increased amount of scar tissue correlated with poor results. Fandino et al (1) found scar to be a contraindication to reoperation if no disk material was present within the epidural space. A recent report describes 197 patients who underwent first-time single-level unilateral discectomy for lumbar

disk herniation who participated in a multicenter trial in which a significant association was found between the presence of extensive epidural scar at MR imaging and the occurrence of recurrent radicular pain (2). The probability of recurrent pain increased with increasing score, so that patients who had extensive epidural scar (a score of 4, denoting more than 75% of the imaging epidural space quadrant filled with scar) were 3.2 times more likely to experience recurrent radicular pain than were patients with less extensive epidural scarring. Stated another way, a logistic regression model suggested that for every 25% increase in scarring, the risk of recurrent radicular pain increased 2.02 times.

Owing to the real and perceived jeopardy that epidural scar tissue poses for the postoperative patient, a variety of materials have been evaluated in an effort to stop or limit epidural scar. These include Silastic, Dacron, methacrylate, bone graft, synthetic membranes and foams, free and pedicle fat grafts, carboxymethylcellulose, elastase, and sodium hyaluronate (12–17). Newer agents that inhibit fibroblast migration are also in clinical trials in the United States and are available in Europe, and are being used at the end of surgery to coat the dura and exiting roots before closure (18).

With renewed interest in the focal or segmental modulation of the formation of scar tissue, the lack of information concerning the natural history of epidural scar becomes more important. If clinical trials are to longitudinally assess the presence or absence of epidural scar after surgery and its change over time, then the routine appearance or change of epidural scar over time must first be known in order to establish a baseline. We have attempted to establish such a baseline in this study by evaluating the appearance of epidural scar over a period of 1 year. We found a small but statistically significant decrease in the extent of scarring between 6 and 12 months postoperatively; however, the majority (75% to 85%) of patients had no change in the amount of epidural scar visible by enhanced MR imaging over a 1-year period after lumbar laminectomy and discectomy.

Acknowledgments

We acknowledge the investigators and clinical sites that made this study possible: F. Porchet and N. de Tribolet at Centre Hospital Universitaire Vaudois, Lausanne, Switzerland; T. Lutz and O. Gratzl at Kantonsspital Basel (Switzerland); J. Brotchi at Hôpital Universitaire Erasme, Brussels, Belgium; R. E. H. van Acker at St Lucas Ziekenhuis, Amsterdam, the Netherlands; H. A. van Alphen at Academisch Ziekenhuis Vrije Universiteit, Amsterdam, the Netherlands; A. Benini at Kantonsspital St Gallen (Switzerland); K. Strommer and R. Bernays at Universitätsspital Zurich (Switzerland); J. Goffin at Academisch Ziekenhuis Gasthuisberg, Leuven, Belgium; and E. A. M. Beuls at Academisch Ziekenhuis Maastricht (the Netherlands).

References

1. Fandino J, Botana C, Viladrich A, Gomez-Bueno J. **Reoperation after lumbar disc surgery: results in 130 cases.** *Acta Neurochir* 1993;122:102-104
2. Ross JS, Frederickson RCA, Petrie JL, et al. **Association between peridural scar and recurrent radicular pain after lumbar discectomy: MR evaluation.** *Neurosurgery* 1996;38:855-863
3. Olmarker K, Rydevick B. **Pathophysiology of sciatica.** *Orthop Clin North Am* 1992;22:223-234
4. Sunderland S. **Nerves and Nerve Injuries.** 2nd ed. Edinburgh, Scotland: Churchill Livingstone; 1978
5. Caucoix J, Ficat C, Girard B. **Repeat surgery after disc excision.** *Spine* 1978;3:256-259
6. Hurme M, Katerio K, Nykist F, Aalto T, Alarouta H, Einola S. **CT five years after myelographic diagnosis of lumbar disk herniation.** *Acta Radiol* 1991;32:286-289
7. Martin-Ferrer S. **Failure of autologous fat grafts to prevent postoperative epidural fibrosis in surgery of the lumbar spine.** *Neurosurgery* 1989;24:718-721
8. Merrild U, Sogaard IB. **Sciatica caused by perifibrosis of the sciatic nerve.** *J Bone Joint Surg* 1986;68:706
9. North RB, Campbell JN, James CS, et al. **Failed back surgery syndrome: 5-year follow-up in 102 patients undergoing repeated operation.** *Neurosurgery* 1991;28:685-690
10. Siqueira EG, Kranzler LI, Dharkar DD. **Fibrosis of the dura mater: a cause of failed back syndrome.** *Surg Neurol* 1983;19:168-170
11. Weisz GM. **The value of CT in diagnosing postoperative lumbar conditions.** *Spine* 1986;11:164-166
12. Gill GG, Sakovich L, Thompson E. **Pedicle fat grafts for the prevention of scar formation after laminectomy: an experimental study in dogs.** *Spine* 1979;4:176-185
13. Jacobs RR, McClain O, Neff J. **Control of postlaminectomy scar formation.** *Spine* 1980;5:223-229
14. Lee CK, Alexander H. **Prevention of postlaminectomy scar formation.** *Spine* 1984;9:305-312
15. Kiviluoto O. **Use of free fat transplants to prevent epidural scar formation.** *Acta Orthop Scand* 1976;165(Suppl):3-75
16. Nussbaum CE, McDonald JV, Baggs RB. **Use of Vicryl (polyglactin-910) mesh to limit epidural scar formation after laminectomy.** *Neurosurgery* 1990;26:649-654
17. Yong-Hing K, Reilly J, de Korompay V, Kirkaldy-Willis WH. **Prevention of nerve root adhesions after laminectomy.** *Spine* 1980;5:59-64
18. Petrie JL, Ross JS. **Use of ADCON-L to inhibit postoperative peridural fibrosis and related symptoms following lumbar disc surgery: preliminary report.** *Eur Spine J* 1996;5:S10-S17