



## Discover Generics

Cost-Effective CT & MRI Contrast Agents



WATCH VIDEO

# AJNR

### **MR of parenchymal spinal cord signal change as a sign of active advancement in clinically progressive posttraumatic syringomyelia.**

J R Jenkins, S Reddy, C C Leite, C Bazan, 3rd and L Xiong

*AJNR Am J Neuroradiol* 1998, 19 (1) 177-182

<http://www.ajnr.org/content/19/1/177>

This information is current as of June 13, 2025.

# MR of Parenchymal Spinal Cord Signal Change as a Sign of Active Advancement in Clinically Progressive Posttraumatic Syringomyelia

J. R. Jenkins, S. Reddy, C. C. Leite, C. Bazan III, and L. Xiong

**Summary:** Extensive MR signal change in the craniad spinal cord parenchyma was found to be an ancillary sign of disease advancement in three patients with clinically progressive posttraumatic syringomyelia. This craniad margin of parenchymal spinal cord T2 hyperintensity resolved after cystoperitoneal shunt placement. There was a concomitant reduction or disappearance of the cyst in each instance, a halt in the progression of neurologic deficit, and some reversal of signs and symptoms.

Progressive posttraumatic cystic syringomyelia is an uncommon but potentially clinically serious complication of spinal cord injury (1). Delayed posttraumatic development of syringomyelia, once thought to occur in only 1% to 4% of cases, is now increasingly recognized as a major cause of morbidity (1). We describe the magnetic resonance (MR) findings in three patients with posttraumatic syringomyelia and progressive signs and symptoms, and describe a finding that may resolve after cystoperitoneal shunting. This observation may be of use in patient treatment.

## Case Reports

### Case 1

A 27-year-old woman had had a trauma to the cervical spine, resulting in a C5-6 fracture dislocation, 1 year before the first MR imaging examination. At the time of the injury, the spinal column was surgically fused anteriorly at three levels (C4-6) to correct posttraumatic spinal instability. Initially, the patient had a stable quadriplegia. During the 6 months preceding the first MR imaging study, she noted a progression of ascending signs and symptoms with increasing weakness in the left triceps muscle and paresthesias in the left side of the body and face. The MR study revealed a syringomyelia extending from the site of vertebral injury at C5-6 craniad to the level of the medulla (Fig 1A). There was an extensive margin of parenchymal hyperintensity along the craniad border of the cystic cavity on the T2-weighted acquisitions (Fig 1B). Neither cyst extension nor extensive parenchymal MR signal change could be identified caudal to the site of the primary injury to the cervical spine and cord. A narrow margin of parenchymal hyperintensity was noted along the caudal border of the cyst; however, it was confined to the area immediately surrounding the syrinx and the primary spinal cord injury at C-6. Subsequently, the patient had a cystoperitoneal shunt placed surgically at the C5-6 level, during which the shunt tip was advanced approximately 2 to 3 cm into the cystic cavity.

The patient was followed up clinically and with MR imaging at 2 weeks (Fig 1C) and 2 months after this intervention (Fig 1D and E). After shunt placement, the cyst gradually collapsed to the point of subtotal resolution. With this alteration, the craniad margin of parenchymal T2 hyperintensity also completely resolved. The narrow band of parenchymal hyperintensity caudal to the cyst did not resolve after surgical shunting. The patient's clinical status stabilized and somewhat improved in tandem with the imaging changes. At 1 year clinical follow-up, her signs and symptoms remained stable.

### Case 2

A 52-year-old man had had a motor vehicle accident 15 years before the present admission, which resulted in a compression fracture of the L-1 vertebral body. At the time of presentation, he reported left-sided burning pain involving the inside of his thigh and the medial aspect of his calf and foot, which had been worsening during the past 5 years. The pain was described as constant and increased with coughing. On coughing he also experienced shooting pain down the posterior aspect of his left arm. The patient denied weakness except in his right leg, which had resulted in a limp beginning approximately 2 years earlier. He had daily enuresis, and also reported several incidents of fecal incontinence during the past few months.

The initial MR imaging examination revealed a syringomyelia extending from the site of vertebral injury at L-1 craniad to the level of T1-2 (Fig 2A-D). There was an extensive margin of hyperintensity along the upper border of the cystic cavity on the T2-weighted images extending craniad to the C-3 level (Fig 2B). This parenchymal hyperintensity was primarily located centrally in the spinal cord, although some relative sparing of the deep gray matter could be identified on axial images (Fig 2C). No cyst extension or major parenchymal MR signal change could be detected along the caudal margin of the cyst, because the posttraumatic cyst began at the terminal end of the spinal cord. A cystoperitoneal shunt was inserted into the cyst at the T5-6 level, and the tip was advanced approximately 2 to 3 cm into the cystic cavity.

Two months after shunt placement a repeat MR examination showed that the cyst had collapsed to the point of subtotal resolution. Along with this alteration, the craniad margin of parenchymal T2 hyperintensity completely resolved (Fig 2E and F). The patient's clinical status stabilized with resolution of pain and weakness. At the 14-month clinical follow-up, the patient's signs and symptoms showed no evidence of progression.

### Case 3

A 72-year-old man had a history of thoracic spine trauma 2 years previously, which resulted in a T5-6 fracture dislocation.

Received March 10, 1997; accepted after revision June 23.

From the Department of Radiology, the University of Texas Health Science Center, 7703 F. Curl Dr, San Antonio, TX 78284.

Address reprint requests to J. Randy Jenkins, MD.

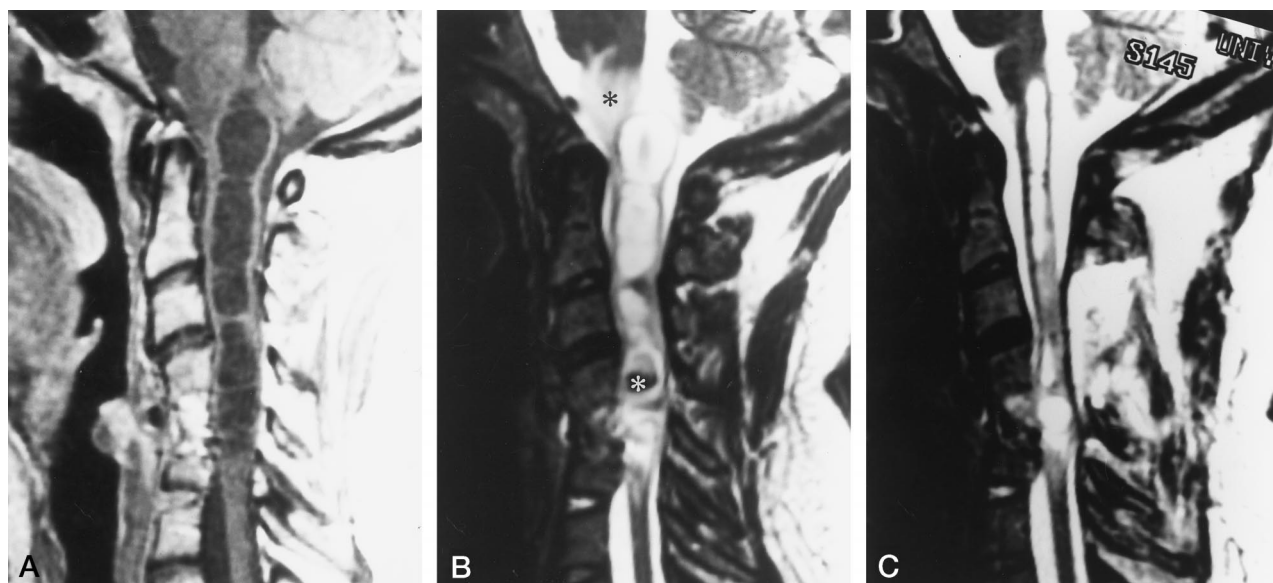


FIG 1. Case 1: MR of the cervical spine before, 2 weeks after, and 2 months after surgical cystoperitoneal shunt placement.

A, Initial sagittal T1-weighted (500/20/3) [repetition time/echo time/excitations] conventional spin-echo MR image shows syringomyelia extending from the site of vertebral injury at C5-6 craniad to the level of the medulla. Note little or no caudal extension of the cyst.

B, Initial sagittal T2-weighted (4000/119/4) fast spin-echo MR image reveals an extensive margin of parenchymal medullary hyperintensity (black asterisk) along the upper border of the cystic cavity. The hypointense areas (white asterisk) in the spinal cord at the level of the spinal trauma probably represent products of hemorrhage.

C, Sagittal T2-weighted (400/119/4) fast spin-echo MR image 2 weeks after cystoperitoneal shunt placement shows that the syringomyelic cyst has partially collapsed and the cranial margin of hyperintensity in the medulla has resolved.

D, Sagittal T1-weighted (500/14/3) conventional spin-echo MR image 2 months after cystoperitoneal shunt (arrow) placement shows that the syringomyelic cyst has collapsed to the point of subtotal resolution.

E, Sagittal T2-weighted (4000/119/4) fast spin-echo MR image acquired at the same time as D shows that the craniad parenchymal spinal cord hyperintensity remains completely resolved. The narrow band of hyperintensity caudal to the spinal cord cyst did not resolve, indicating that this probably represents an area of irreversible posttraumatic gliosis. (Compare with B.)

During the 6 months preceding the initial imaging study, the patient noted a progression of ascending signs and symptoms that included pain and paraesthesias along his upper extremities. The MR examination revealed a syringomyelia extending from the site of vertebral injury at T-5 craniad to the level of C4-5 (Fig 3A and B). There was an extensive margin of parenchymal hyperintensity along the upper border of the cystic cavity on the T2-weighted acquisition (Fig 3B) extending to the upper C-2 level. No cyst extension or major perilesional parenchymal MR signal change could be identified along the caudal margin of the cyst (Fig 3C). A cystoperitoneal shunt was placed at the T2-3 level and the shunt tip was advanced approximately 2 to 3 cm into the cystic cavity.

The patient was sequentially followed up after surgery, clinically and with MR imaging, at 2 (Fig 3D and E) and 6 months.

After shunt placement, the cyst gradually collapsed to the point of subtotal resolution. With this alteration, the craniad margin of parenchymal T2 hyperintensity completely resolved. The patient's clinical status stabilized and somewhat improved in concert with the imaging changes. At the 18-month clinical follow-up, the patient's signs and symptoms remained stable.

#### Clinically Stable Cases

Three patients with clinically stable posttraumatic quadriplegia were also studied by MR imaging in a manner identical to the group with clinically progressive signs and symptoms. The preceding trauma had occurred 1 to 5 years prior to the MR examinations. These patients all had focal syringomyelia in the cervical spinal cord. The cysts did not extend beyond one cervical vertebral body length. In one case, the spinal cord showed no discernible pericystic T2 signal change, while in the

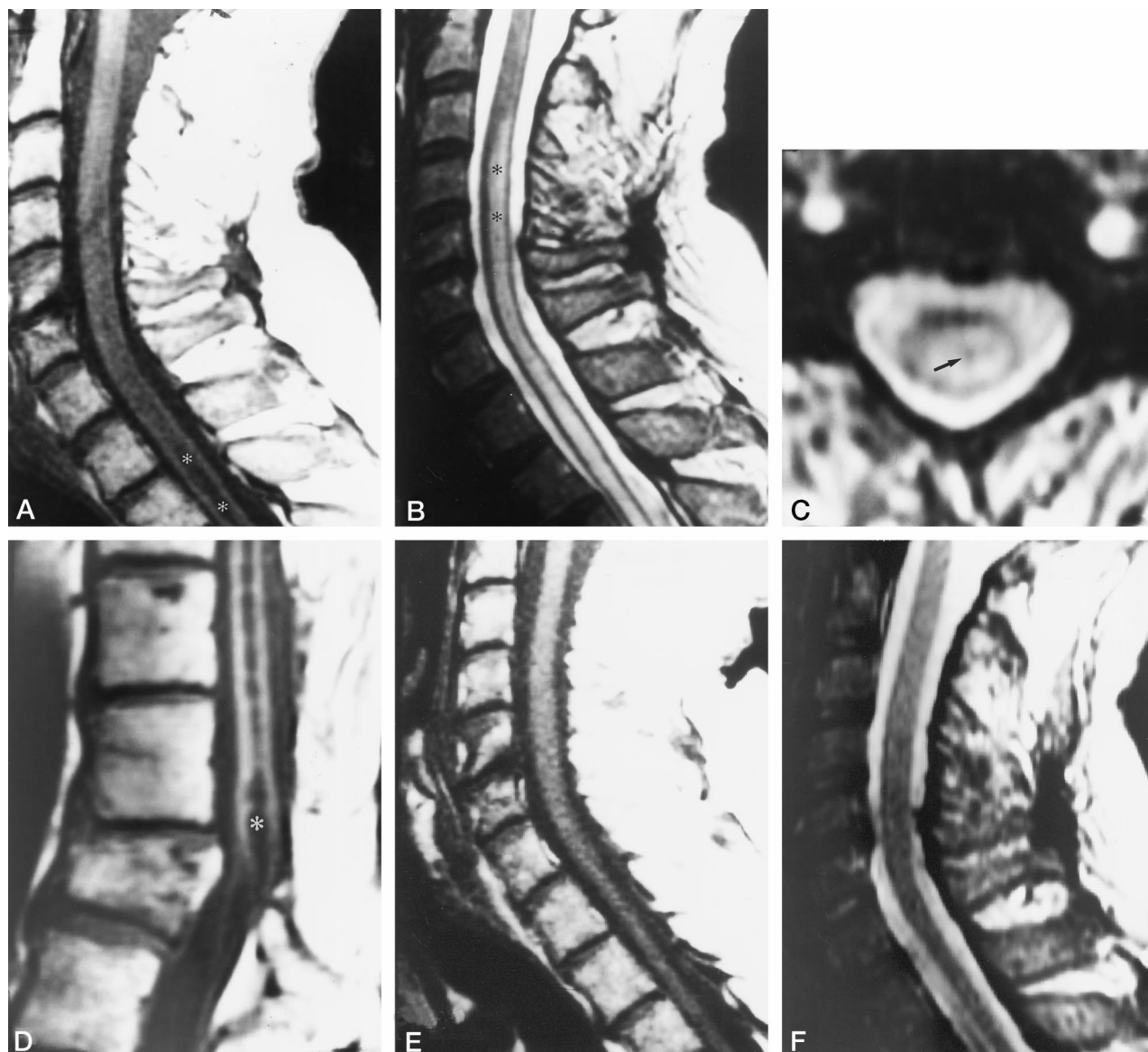


FIG 2. Case 2: MR of the cervical spine before and 2 months after surgical cystoperitoneal shunt placement.

A, Initial sagittal T1-weighted (500/15/3) conventional spin-echo MR image shows a hypointense syringomyelic cyst (asterisks) extending craniad from the site of vertebral injury at L-1 craniad to the level of C-5 (lumbar and thoracic MR studies not shown).

B, Initial sagittal T2-weighted (4000/119/4) fast spin-echo MR image reveals an extensive margin of parenchymal spinal cord hyperintensity (asterisks) along the upper border of the cystic cavity.

C, Axial T2-weighted (4000/119/4) fast spin-echo MR image at the C-4 level shows that the cranial margin of hyperintensity is centrally located in the spinal cord, although a focal area of relative hypointensity (arrow) may be related to the deep gray matter.

D, Sagittal T1-weighted (500/15/3) conventional spin-echo MR image acquired at the same time as A through C shows the wedge fracture of L-1 and the origin of the syringomyelic cyst (asterisk) at the terminal level of the spinal cord.

E, Sagittal T1-weighted (500/11/3) conventional spin-echo MR image 2 months after cystoperitoneal shunt placement shows that the cyst has resolved.

F, Sagittal T2-weighted (4000/119/4) fast spin-echo MR image acquired at the same time as E shows that the cranial margin of parenchymal spinal cord hyperintensity and the syringomyelia have completely resolved. (Compare with B.)

other two cases the T2 signal change was confined to the parenchyma of the spinal cord immediately surrounding the parenchymal cyst, not exceeding one vertebral body length.

### Discussion

Progressive signs and symptoms related to post-traumatic syringomyelia can occur as a late sequela to spinal cord injury (2–4). The prevalence of posttrau-

matic syringomyelia is much higher in patients with complete quadriplegia (8%) than in those with incomplete quadriplegia (2.5%), complete paraplegia (1%), or incomplete paraplegia (2%) (4). Signs and symptoms of posttraumatic syringomyelia have been reported as early as 3 months after spinal cord trauma or as late as 32 years after injury (4).

Ascending and descending posttraumatic myelopa-



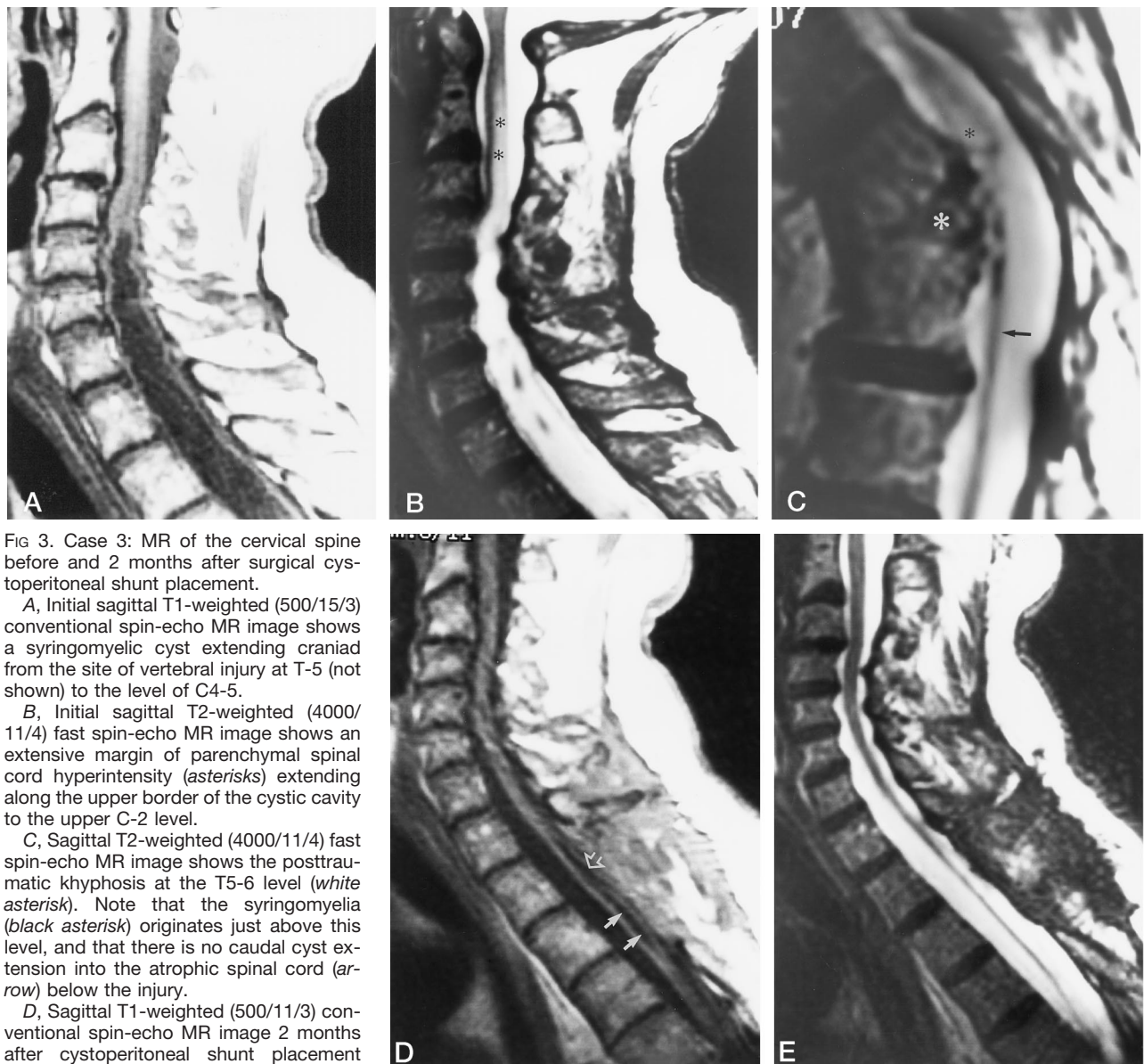


FIG 3. Case 3: MR of the cervical spine before and 2 months after surgical cystoperitoneal shunt placement.

A, Initial sagittal T1-weighted (500/15/3) conventional spin-echo MR image shows a syringomyelic cyst extending craniad from the site of vertebral injury at T-5 (not shown) to the level of C4-5.

B, Initial sagittal T2-weighted (4000/11/4) fast spin-echo MR image shows an extensive margin of parenchymal spinal cord hyperintensity (asterisks) extending along the upper border of the cystic cavity to the upper C-2 level.

C, Sagittal T2-weighted (4000/11/4) fast spin-echo MR image shows the posttraumatic kyphosis at the T5-6 level (white asterisk). Note that the syringomyelia (black asterisk) originates just above this level, and that there is no caudal cyst extension into the atrophic spinal cord (arrow) below the injury.

D, Sagittal T1-weighted (500/11/3) conventional spin-echo MR image 2 months after cystoperitoneal shunt placement shows that the majority of the cyst has resolved to a small residual cavity (closed arrows). The posterior border of the spinal cord is contiguous with the margin of the thecal sac; this may or may not indicate the presence of adhesion. The surgical posterior decompression at T2-4 indicates the level of cystoperitoneal shunt placement. Open arrow indicates shunt catheter.

E, Sagittal T2-weighted (4000/119/4) fast spin-echo MR image acquired at the same time as D shows that the craniad margin of parenchymal spinal cord hyperintensity has completely resolved. (Compare with B.)

thy is thought to begin at the time of injury or soon thereafter and may involve mechanisms such as the release of destructive enzymes, free radical products, or other toxic agents (5-8). Central or dorsocentral cores of necrotic tissue may extend for several spinal segments from the level of injury, and may liquify to form a cavity (1, 5). Conversion of necrotic spinal cord into a true cyst may take months to years (4, 7, 9). This probably accounts for the apparent continuum of noncystic to cystic myelopathy. The rate of progression of the pathologic process in individual cases is highly variable (7).

The pathogenesis of syringomyelia formation is unclear, although several theories have been proposed. Kao et al (10) have postulated that the rupture and

coalescence of microcysts lead to posttraumatic syringomyelia formation. Microcyst formation in contused, compressed, and transected spinal cords results in part from the egress of fluid from damaged axons (11, 12). Other proposed mechanisms that lead to formation of posttraumatic syringomyelic cavities include resorption of blood and necrotic tissue, lysosomal autolysis, secretion of cystic fluid by the developing cyst lining, infarction, posttraumatic reactive ependymal proliferation causing segmental closure of the central canal with resulting local distension, and passage of cerebrospinal fluid (CSF) into the injured central cord via enlarged perivascular spaces (1, 2, 10, 12-17). The formation of arachnoid adhesions may further alter the CSF dynamics so that abnormal

entry of CSF into the spinal cord via Virchow-Robin spaces results in progressive syringomyelia (7, 18, 19).

Reports indicate that posttraumatic syringomyelia most commonly extends superiorly from the injury site; less frequently, it may also have an inferior component. Inferior extension alone is uncommon (9). It has been theorized that because there is more space in the cervical than in the thoracic spinal canal, the cervical cord can expand more easily from the underlying cystic cavitation (20, 21). An additional limitation in caudal growth of cysts may be the posttraumatic parenchymal spinal cord atrophy and gliosis at and below the injury site, resulting in a more dense, compact cord that is therefore less able to expand. For these reasons, the cyst would be hypothetically freer to extend along the line of least resistance in the cranial direction (21).

The first clinical suggestion of advancement of a posttraumatic syringomyelia is usually the onset of ascending signs or the development of new symptoms after an apparently stable period (1, 22). The progressive clinical picture varies from a new onset of minimal sensory loss to a fully developed anesthesia with motor weakness of an extremity and the development of Charcot joints (12, 14, 22). In some patients, the chief symptom is severe pain (4, 22). Although sensory impairment is troublesome initially in many cases, in later stages motor loss may become sufficiently severe to warrant further radiologic investigation or active surgical intervention.

The presence of flow voids on MR images within the syringomyelic cystic cavity has been suggested by some to correlate with a greater potential for improvement after surgical shunting (22). In our cases we did not perform specific MR examinations, such as gated CSF flow studies to determine the nature of fluid dynamics within the syringeal cavities. We were therefore unable to correlate cystic fluid flow characteristics with our observations of high parenchymal signal on T2-weighted MR images above the cysts.

Gebariski et al (23) categorized posttraumatic progressive myelopathy into three groups on the basis of characteristic radiological findings and their responses to therapy: 1) myelomalacia with no cystic degeneration: poor response to therapy; 2) small cyst formation: poor response to surgical therapy; and 3) large cyst formation: effective treatment by surgical shunting.

Surgical shunting of these large cysts may halt the progression of the myelopathy and reverse the clinical deterioration in many cases (9). Hyperintense T2 MR signal within the spinal cord parenchyma adjacent to syringomyelia as shown in the current group of patients may correlate with both edema formation and myelin degeneration with or without gliosis. Such MR signal change is not typically observed distant from the site of focal cord trauma; permanent parenchymal signal alteration is usually only seen immediately surrounding the primary focus of cord trauma. Furthermore, in instances in which this parenchymal signal change only extends cephalad, and is reversible, the

chances are favorable that edema is the main factor: resolution of this abnormal parenchymal MR signal intensity after cystoperitoneal shunting appears to correlate with improvement in neurologic status.

Although these craniad parenchymal MR signal changes were presumably progressive, together with the craniad enlargement of the cyst, our small group of patients did not have prior imaging studies with which to compare the images acquired at the time of presentation of advancing signs and symptoms. This possibility can only be assessed in future studies of patients in whom there is more complete longitudinal imaging documentation. Nevertheless, the focality of the posttraumatic syringomyelia and the lack of extensive cranial T2 MR parenchymal spinal cord signal change in the second group of clinically stable posttraumatic quadriplegic patients supports the significance of the imaging findings in the patients with clinically progressive disease. Presumably, the T2 MR parenchymal spinal cord signal alteration that was seen immediately surrounding the spinal cord cysts in two of the clinically stable patients represented static posttraumatic gliosis (ie, myelomalacia).

In summary, some enlarging posttraumatic syringomyelic cysts are observed to have a cranial margin of parenchymal spinal cord T2 hyperintensity on MR studies. Because this abnormal parenchymal MR signal intensity resolved together with advancing signs and symptoms after surgical cystoperitoneal shunting of the cystic cavity, it may represent fluid escaping from the cyst or edema caused by as yet undefined pathologic alterations of the spinal cord adjacent to the enlarging cyst. While ascending/advancing clinical signs and symptoms are the main factors to consider in patients being considered for surgical shunting, the ancillary radiologic sign described here should be taken into account when imaging patients with posttraumatic syringomyelia and evidence of clinical progression.

## References

- Curati WL, Kingsley DP, Kendall BE, Moseley IF. **MRI in chronic spinal cord trauma.** *Neuroradiology* 1992;35:30-35
- Reddy KK, Del Bigio MR, Sutherland GR. **Ultrastructure of the human posttraumatic syrinx.** *J Neurosurg* 1989;71:239-243
- Barnett HJM, Jousse AT. **Case records of authors' series of post-traumatic syringomyelia.** In: Barnett HJM, Foster JB, Hodgson P, eds. *Syringomyelia*. London, England: Saunders; 1973:165-173
- Rossier AB, Foo D, Shillito J, Dyro FM. **Posttraumatic cervical syringomyelia: incidence, clinical presentation, electrophysiological studies, syrinx protein and results of conservative and operative treatment.** *Brain* 1985;108:439-461
- Fox JL, Wener L, Drennan DC, Manz HJ, Won DJ, Al-Mefty O. **Central spinal cord injury: magnetic resonance imaging confirmation and operative considerations.** *Neurosurgery* 1988;22:340-347
- Gardner WJ, McMurry FG. **"Non-communicating" syringomyelia: a non-existent entity.** *Surg Neurol* 1976;6:251-256
- Kerslake RW, Jaspan T, Worthington BS. **Magnetic resonance imaging of spinal trauma.** *Br J Radiol* 1991;64:386-402
- Stevens JM, Olney JS, Kendall BE. **Post-traumatic cystic and noncystic myelopathy.** *Neuroradiology* 1985;27:48-56
- Quencer RM, Green BA, Eismont FJ. **Posttraumatic spinal cord cysts: clinical features and characterization with metrizamide computed tomography.** *Radiology* 1983;146:415-423
- Kao CC, Chang LW, Bloodworth JM. **The mechanism of spinal cord cavitation following spinal cord transection, part 2: electron microscopic observation.** *J Neurosurg* 1977;46:745-756

11. Shannon N, Symon L, Logue V, Cull D, Kang J, Kendall B. **Clinical features, investigation and treatment of posttraumatic syringomyelia.** *J Neurol Neurosurg Psychiatry* 1981;44:35–42
12. MacDonald RL, Findlay JM, Tator CH. **Microcystic spinal cord degeneration causing posttraumatic myelopathy.** *J Neurosurg* 1988;68:466–471
13. Jenkins JR, Bashir R, Al-Mefty O, Al-Kawi MZ, Fox JL. **Cystic necrosis of the spinal cord in compressive cervical myelopathy: demonstration of iopamidol CT myelography.** *AJR Am J Roentgenol* 1986;147:767–775
14. Ball MJ, Dayan AD. **Pathogenesis of syringomyelia.** *Lancet* 1972;2:799–801
15. Vaquero J, Ramiro JM, Oya S, Cabezudo JM. **Ependymal reaction after experimental spinal cord injury.** *Acta Neurochir* 1981;55:295–302
16. Mathews MA, St Onge MF, Faciane CL. **An electron microscopic analysis of abnormal ependymal cell proliferation and envelopment of sprouting axons following spinal cord transection in the rat.** *Acta Neuropathol* 1979;45:27–36
17. Rascher K, Booz KH, Donauer E, Nacimiento AC. **Structural alterations in the spinal cord during progressive communicating syringomyelia: an experimental study in the cat.** *Acta Neuropathol* 1987;72:248–255
18. Castillo M, Quencer RM, Green BA, Montalvo BM. **Syringomyelia as a consequence of compressive extramedullary lesions: postoperative clinical and radiological manifestations.** *AJR Am J Roentgenol* 1988;150:391–396
19. Sherman JL, Barkovich AJ, Citrin CM. **The MR appearances of syringomyelia: new observations.** *AJR Am J Roentgenol* 1987;148:381–391
20. Barnett HJ, Butterell EH, Jousse AT, Wynne-Jones M. **Progressive myelopathy as a sequel to traumatic paraplegia.** *Med Serv J Can* 1966;22:631–650
21. Watson N. **Ascending cystic degeneration of the cord after spinal cord injury.** *Paraplegia* 1981;19:89–95
22. Asano M, Fujiwara K, Yonenobu K, Hiroshima K. **Post-traumatic syringomyelia.** *Spine* 1996;21:1446–1453
23. Gebarski SS, Maynard FW, Gabrielsen TO, Knake JE, Latack JT, Hoff JT. **Posttraumatic progressive myelopathy: clinical and radiologic correlation employing MR imaging, delayed CT metrizamide myelography, and intraoperative sonography.** *Radiology* 1985;157:379–385

Please see the Editorial on page 192 in this issue.