



Providing Choice & Value

Generic CT and MRI Contrast Agents

**FRESENIUS
KABI**

CONTACT REP

AJNR

This information is current as
of July 28, 2025.

**Single-voxel proton MR spectroscopy and
positron emission tomography for
lateralization of refractory temporal lobe
epilepsy.**

E Achten, P Santens, P Boon, D De Coo, T Van De
Kerckhove, J De Reuck, J Caemaert and M Kunnen

AJNR Am J Neuroradiol 1998, 19 (1) 1-8
<http://www.ajnr.org/content/19/1/1>

Single-Voxel Proton MR Spectroscopy and Positron Emission Tomography for Lateralization of Refractory Temporal Lobe Epilepsy

Eric Achten, Patrick Santens, Paul Boon, Danny De Coo, Tom Van De Kerckhove, Jacques De Reuck, Jacques Caemaert, and Mark Kunnen

PURPOSE: We compared the metabolic information obtained from single-voxel proton MR spectroscopy and positron emission tomography (PET) in patients with temporal lobe epilepsy.

METHODS: Twenty-nine patients with temporal lobe epilepsy were screened for metabolic abnormalities with both proton MR spectroscopy and PET. Lateralization with MR spectroscopy was possible by using NAA/(Cho+Cr) and an asymmetry index. Hypometabolism as determined by PET was classified as typical or complex.

RESULTS: Twenty-four (96%) of 25 patients whose seizure onset could be lateralized to one temporal lobe showed ipsilateral lateralization with either MR spectroscopy or PET, whereas concordant lateralization with both techniques was possible only in 14 (56%) of the 25 patients. MR spectroscopy showed 42 abnormal temporal lobes whereas PET showed only 25 lobes with decreased metabolism. All temporal lobes with hypometabolism at PET also had a low NAA/(Cho+Cr). Five patients (20%) with negative PET studies had seizures lateralized correctly with MR spectroscopy.

CONCLUSION: Proton MR spectroscopy is more sensitive in depicting metabolic abnormalities than is PET in patients with temporal lobe epilepsy. Patients with negative PET studies will benefit from MR spectroscopy for the purpose of lateralization.

Although many patients with so-called cryptogenic temporal lobe epilepsy have anomalies that can be depicted by using an optimized magnetic resonance (MR) imaging protocol (1), in some cases, lateralization with electroencephalography (EEG) and MR imaging is not accomplished easily. Neuropsychological examination and metabolic tests, such as positron emission tomography (PET), single-photon emission computed tomography (SPECT) (2), and MR spectroscopy (3), may be used to corroborate localizing results. The invasive intracarotid amytal procedure gives information about language location and memory support (4), and depth electrode studies are required when noninvasive presurgical tests produce conflicting results (5). Improving noninvasive diagnosis will diminish the need for invasive procedures.

Both single-voxel proton MR spectroscopy (6–11) and fludeoxyglucose F 18 positron emission tomography (FDG-PET) (12–20) are metabolic screening techniques that are used in the presurgical examination of patients with refractory temporal lobe epilepsy. Recent studies have shown that *N*-acetylaspartate (NAA) (3, 6–9) is often decreased in the temporal lobes of patients with temporal lobe epilepsy, and that variable changes in choline (Cho) and creatine/phosphocreatine (Cr) concentrations have also been reported (3, 9–11) (G. Ende, K. D. Laxer, R. Knowlton, et al, “Quantitative ¹H SI Shows Bilateral Metabolite Changes in Patients with Unilateral Temporal Lobe Epilepsy with and without Hippocampal Atrophy,” presented at the annual meeting of the Society of Magnetic Resonance in Medicine, Nice, France, August 1995; C. O. Duc, D. Meier, X. G. Golay, et al, “Investigation of Temporal Lobe Epilepsy by Quantitative ¹H MRS of the Hippocampus in Vivo,” presented at the annual meeting of the Society of Magnetic Resonance in Medicine, Nice, France, August 1995). Because absolute quantification remains difficult, the NAA/(Cho+Cr) or the NAA/Cr ratios, or the normalized value for NAA, are usually calculated (9–11, 21) (Ende et al, “Quantita-

Received February 10, 1997; accepted after revision July 7.

From the Departments of Radiology (E.A., M.K.), Neurology (P.S., P.B., D.D.C., J.D.R.), and Neurosurgery (T.V.D.K., J.C.), University Hospital Ghent (Belgium).

Address reprint requests to Eric Achten, MD, MR-department-1K12, Universitair Ziekenhuis Gent, De Pintelaan 185, 9000 Gent, Belgium.

TABLE 1: Categorization of patients with temporal lobe epilepsy by NAA/(Cho+Cr) levels and an adequate asymmetry index

Category	Label	NAA/(Cho+Cr)*	Asymmetry Index†
Normal	None	Both values normal	<0.11
Pure lateralization	Left or right (lat)	Unilateral low	>0.11
Bilateral	Bi	Bilateral low	<0.05
Bilateral but lateralized	Bi L or Bi R	Bilateral low	>0.05
Both sides in the normal range but lateralized	Norm L or Norm R	Both values normal	>0.11

* Cut-off value for NAA/(Cho+Cr) is 0.70 (see Achten et al [3]). Lateralization is always to the side with the lowest value.

† The absolute value of the asymmetry index.

tive...”; Duc et al, “Investigation...”). We have introduced the use of an asymmetry index in conjunction with NAA/(Cho+Cr) to improve the lateralizing capacity of MR spectroscopy (3) (Table 1).

Interictal PET findings can regionalize zones of interictal metabolic dysfunction related to the focus of partial epilepsy (12–20). Several reports indicate a 60% to 90% prevalence of temporal lobe hypometabolism in patients with medically refractory mesial temporal lobe epilepsy (14–17, 19). In this study, we compared MR spectroscopy and PET as to their effectiveness in lateralizing seizure focus, and we hypothesized a possible relationship between the metabolic abnormalities depicted.

Methods

Clinical and EEG Assessment

Twenty-nine consecutive patients (age range, 14 to 53 years) with symptoms of temporal lobe epilepsy refractory to medical treatment and with no tumors or vascular malformations, traumatic lesions, or neuronal migration disease were entered into a presurgical evaluation program (5). All patients underwent a clinical neurological examination and several scalp EEGs. Habitual complex partial seizures were recorded during prolonged video-EEG monitoring (Beehive and SZAC 32-channel digital EEG, Telefactor, West Conshohocken, Pa). Lateralization was attempted by using the EEG and clinical data.

Interictal MR Imaging and Proton MR Spectroscopy

MR imaging of the temporal lobes was performed on a clinical 1.5-T system. The temporal lobes and the hippocampal structures were examined on oblique coronal T1-weighted inversion recovery images, and the volumes of the hippocampus and amygdala were calculated from oblique coronal three-dimensional magnetization-prepared rapid gradient-echo images with a manual ray-tracing method (1). Single-voxel proton MR spectroscopy was carried out immediately after MR imaging using an 8-mL voxel ($20 \times 20 \times 20 \text{ mm}^3$) positioned over the mesotemporal lobe, including part of the hippocampus (Fig 1). The signal over the voxel of interest was shimmed to within a linewidth of 3 to 7 Hz. Water suppression was achieved by applying a gaussian 90° pulse on the water frequency followed by a strong spoiler gradient. Spectra were acquired using a spin-echo sequence with an echo time of 135 (22). The repetition time was 1600, and the number of excitations was 256. To compensate for eddy current artifacts, we acquired a reference scan with the same sequence parameters but without water suppression and with only eight acquisitions. After eddy current correction (23), the time domain spectra were zero-filled to 2048 points and a weak gaussian filter with a half-life of 256 milliseconds was applied before fast Fourier transformation. The resultant frequency domain spectra required minimal

zero-order and sometimes first-order phase correction; no baseline correction was applied. Three resonances of importance could be identified (Fig 1D): NAA at 2 ppm, Cr at 3 ppm, and Cho at 3.2 ppm. These peaks were quantified by simple triangulation. Then the metabolite ratio of NAA/(Cho+Cr) was calculated. The NAA/(Cho+Cr) ratio was considered abnormal if the value was below 0.70 (3).

The asymmetry index (AI) was calculated as

$$1) \quad AI = 2^*(R_r - R_l)/(R_r + R_l)$$

where R_r is the NAA/(Cho+Cr) ratio on the right side and R_l the NAA/(Cho+Cr) ratio on the left. When one or both NAA/(Cho+Cr) ratios are normal, an absolute asymmetry index value greater than 0.11 is considered lateralizing (Table 1). When both NAA/(Cho+Cr) ratios are abnormal, lateralization is possible with an asymmetry index value in excess of 0.05 (3).

PET Scanning and Evaluation

All PET studies were performed in a dimly lit room, with the patients' eyes open and ears unplugged. After a minimum 4-hour fast, patients were positioned in the gantry so that scan-plane orientation was parallel to the orbitomeatal line and the center of the field of view was 40 mm above this orbitomeatal line. For each patient, a transmission scan was performed by using a germanium-68/germanium-68 ring source to allow attenuation correction of the emission scans. Subsequently, 185 MBq (5 mCi) of FDG was injected intravenously. Thirty minutes later, a static emission scan was performed with data acquisition lasting 20 minutes. PET scans were obtained on an ECAT IV scanner (EG&G Ortec, Oak Ridge, Tenn) ($n = 20$) or an ECAT 951/31 scanner (Siemens, Knoxville, Tenn) ($n = 9$). Plane thickness was 16 mm and 3.375 mm at full-width, half-maximum, respectively. Axial/transaxial resolution at the center of the field of view was 8.1/14.1 mm for the ECAT IV scanner and 5.0/5.8 mm for the ECAT 951/31 scanner. Six interleaved planes were scanned in two series of three with the ECAT IV unit (Fig 2B) and 31 planes were acquired with the ECAT 951/31 unit (Fig 3C). Emission images were reconstructed by filtered back projection using a Hann cut-off filter.

After acquisition, the images were transported to a Sparc 20 workstation (Sun Microsystems, Mountain View, Calif) and displayed. The images were placed in a view box for interpretation, and findings were scored as proposed by Henry et al (16). Two types of FDG hypometabolism can be described: typical (eg, diffuse hypometabolism in one temporal lobe only) or complex (eg, hypometabolism not only confined to one temporal lobe but also present in other brain areas). Evaluations of the MR images, MR spectra, and PET scans were performed independently of one another.

Results

From the extracranial EEG recordings (interictal and ictal), 24 of 29 patients with temporal lobe epi-

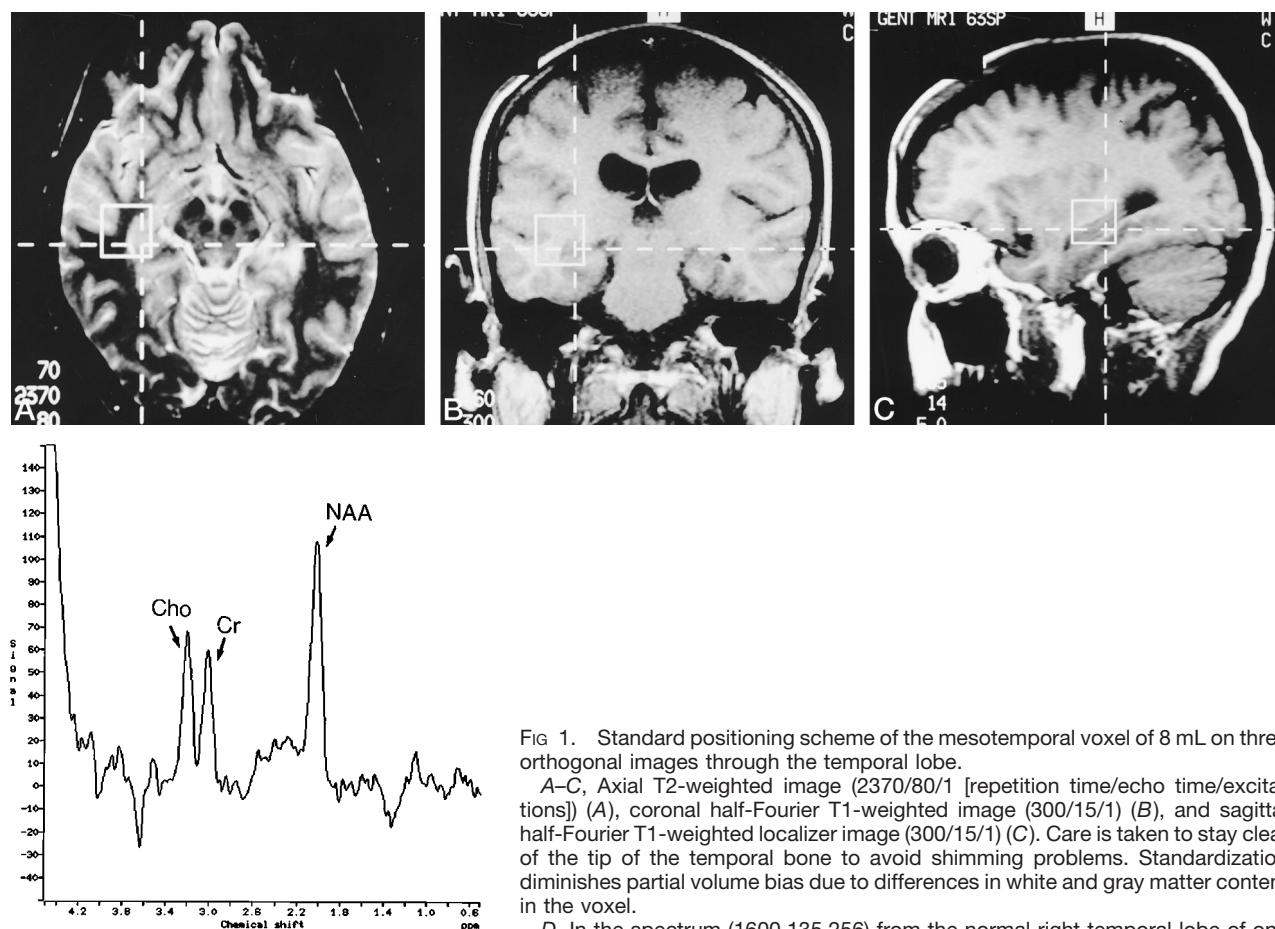


FIG 1. Standard positioning scheme of the mesotemporal voxel of 8 mL on three orthogonal images through the temporal lobe.

A–C, Axial T2-weighted image (2370/80/1 [repetition time/echo time/excitations]) (A), coronal half-Fourier T1-weighted image (300/15/1) (B), and sagittal half-Fourier T1-weighted localizer image (300/15/1) (C). Care is taken to stay clear of the tip of the temporal bone to avoid shimming problems. Standardization diminishes partial volume bias due to differences in white and gray matter content in the voxel.

D, In the spectrum (1600,135,256) from the normal right temporal lobe of one patient (case 9), three peaks can be recognized: from right to left: NAA at 2 ppm, Cr at 3 ppm, and Cho at 3.2 ppm.

D

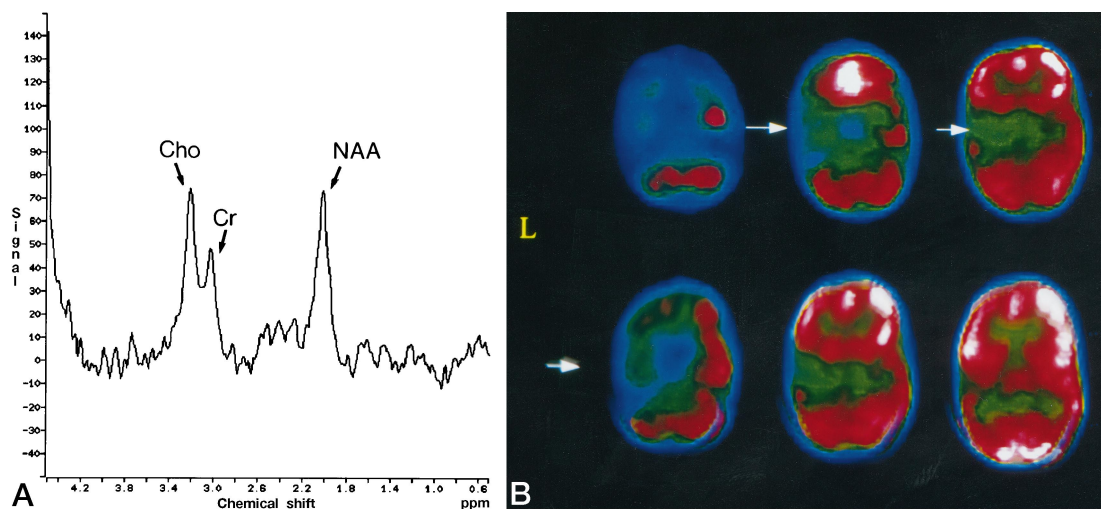


FIG 2. Case 9: patient with seizure onset lateralized to left temporal lobe by EEG studies. The inversion-recovery T1-weighted MR images (3500/20/1; inversion time, 300) (not shown) depicted hippocampal sclerosis on the left side as the only imaging abnormality. The spectrum (1600/135/256) shows a low NAA/(Cho+Cr) on the left side only (A), and the PET scan (ECAT IV camera) (B) has a typical diffuse hypometabolic focus in the left temporal lobe (arrows). A modified left temporal lobectomy was performed, and the patient remains seizure free after 36 months.

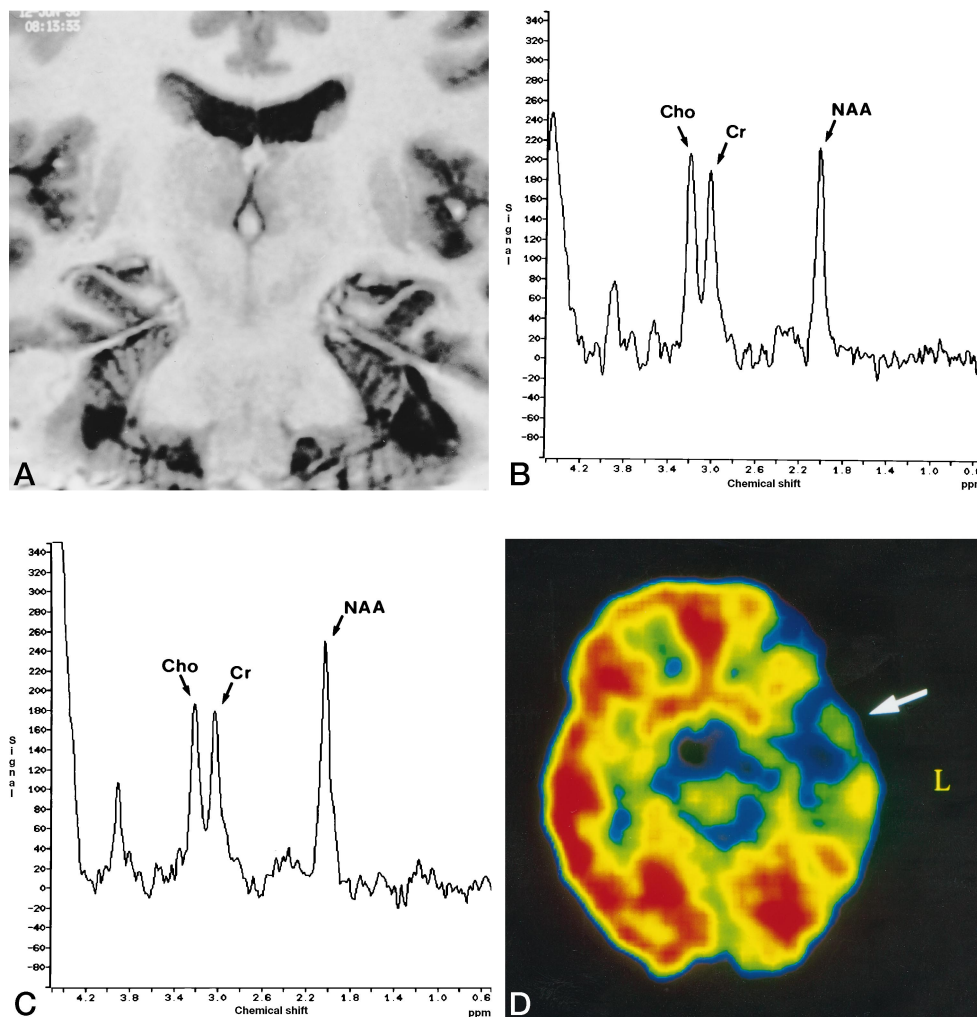


FIG 3. Case 19: patient with seizure onset lateralized to the left temporal lobe by EEG studies. Inversion-recovery T1-weighted image (3500/20/1; inversion time, 300) (A) shows symmetric hippocampal damage. The spectra (1600/135/256) show low NAA/(Cho+Cr) values on the left side only (B) while the right side (C) appears normal. The PET scan (ECAT 951/31 camera) (D) has a typical diffuse hypometabolic focus in the left temporal lobe (arrow). As yet, no definite decision has been reached concerning surgery.

lepsy were considered to have lateralized focal meso-temporal seizure onset; one patient (case 2) had regional frontotemporal onset from one side; and one patient (case 16) had bilateral independent epileptic activity. In three patients (cases 12, 22, 26), seizure onset could not be lateralized. Table 2 summarizes the test results for all patients.

When using our optimized MR imaging protocol in the group of 25 patients who showed lateralized seizure activity on the EEG examination (Table 2), we found that 22 (88%) had either hippocampal ($n = 14$) or mesial temporal ($n = 8$) sclerosis on the same side. One subject (case 28) had no abnormal imaging findings, and two (cases 17 and 19) had bilateral symmetric hippocampal damage. MR spectroscopy lateralized seizure onset correctly in 19 (76%) of 25 patients, and no discordance with the EEG findings was noted. PET also showed concordantly lateralized hypometabolism in 19 patients, also with no discrepancies regarding the EEG. On the other hand, seizure onset was lateralized concordantly with either MR spectroscopy or PET in 24 (96%) of the subjects, but in only

14 (56%) of the subjects with both techniques (Fig 2, Table 3). One of the patients with bilateral symmetric hippocampal damage (case 17) had bilateral symmetric low NAA/(Cho+Cr) values but had seizure onset lateralized with PET only, whereas the other patient (case 19, Fig 3) had seizure onset lateralized with both MR spectroscopy and PET. One patient with temporal lobe epilepsy and no MR imaging abnormalities (case 28) had normal values at MR spectroscopy and a normal PET scan.

Bilaterally low NAA/(Cho+Cr) ratios were found in 10 of 25 patients with temporal lobe epilepsy and lateralized seizure onset at EEG (Table 3); in six patients, seizures could further be lateralized with the asymmetry index, and the other four had symmetrically low NAA/(Cho+Cr) values. A classical, ipsilateral, diffuse temporal lobe hypometabolism was depicted by PET in nine of these subjects, and only one (case 6) also had bilateral PET hypometabolism but worse on the side ipsilateral to that depicted at EEG.

Six patients with lateralized temporal lobe epilepsy had normal findings at PET; four with the ECAT IV

TABLE 2: Test results from 29 patients with temporal lobe epilepsy

Case	Sex/ Age, y	EEG Lateralization	MR Imaging Lateralization	NAA/(Cho+Cr) Lateralization*	PET Hypometabolism†	PET Camera‡	Consensus Surgery Side	Outcome§	Follow- up, mo
1	M/21	L meso TL	L HCS	L	Complex: L hemisphere	951	L	Scheduled for surgery	...
2	F/28	L FTL	L meso TL	Bi L	Diffuse: L TL	IV	L	Depth electrode study: L regional onset	...
3	F/19	R meso TL	R HCS	R	Complex: R hemisphere	IV	R	1A	18
4	F/26	R meso TL	R HCS	R	None	IV	R	Refused surgery	...
5	F/31	R meso TL	R meso TL	Bi R	Diffuse: R TL	IV	R	1A	24
6	F/36	R meso TL	R HCS	Bi	Complex: R > L TL	IV	R	1A	18
7	M/35	R meso TL	R HCS	R	Diffuse: R TL	951	R	Recent surgery, no seizures	6
8	M/39	L meso TL	L meso TL	L	Diffuse: L TL	IV	L	1A	24
9	M/14	L meso TL	L HCS	L	Diffuse: L TL	IV	L	1A	36
10	M/18	L meso TL	L HCS	L	None	IV	L	Discrepant IAP, not operated on	...
11	M/46	L meso TL	L meso TL	Bi L	Diffuse: L TL	IV	L	Recent surgery, no seizures	<6
12	F/20	Nonlateralized	Bi HC damage	Bi L	Diffuse: L TL	IV	Not decided
13	F/29	L meso TL	L meso TL	L	Diffuse: L TL	IV	L	Depth electrode study: L regional onset	...
14	M/37	R meso TL	R HCS	Bi R	Diffuse: R TL	951	R	Recent surgery, no seizures	<6
15	F/37	R meso TL	R HCS	B	Diffuse: R TL	951	R	1A	12
16	F/32	Bi independent	L HC atrophy	B	Complex: R > L TL	IV	Not decided
17	F/30	R meso TL	B HCS	B	Diffuse: R TL	IV	R	1A	12
18	F/34	L meso TL	L meso TL	L	None	IV	L	Recent surgery, no seizures	<6
19	M/44	L meso TL	B HCS	L	Diffuse: L TL	951	Not decided
20	F/39	R meso TL	R HCS	B	Diffuse: R TL	IV	R	1A	6
21	F/19	L meso TL	L meso TL	L	Diffuse: L TL	IV	L	3A	12
22	F/26	Nonlateralized	B HCS, L>R	B	Diffuse: L TL (slight)	951	Not decided
23	F/26	R meso TL	R HCS	B R	Diffuse: R TL	IV	R	3A	12
24	M/19	L meso TL	L HCS	L	Diffuse: L TL	IV	L	1A	18
25	F/28	R meso TL	R meso TL	R	None	IV	R	1A	24
26	M/31	Nonlateralized	L meso TL	L	Diffuse: L TL	IV	Not decided
27	M/53	L meso TL	L HCS	Bi L	None	951	L	Scheduled for surgery	...
28	F/23	R meso TL	Normal	None	None	951	Not decided
29	F/37	L meso TL	L HCS	B	Diffuse: L TL	951	L	1A	12

Note.—Meso TL indicates focal mesotemporal lobe EEG location; FTL, regional frontotemporal EEG location; Bi, bilateral; HCS, hippocampal sclerosis; meso TS, mesotemporal lobe sclerosis, including hippocampus and surrounding areas, and IAP, intracarotid amytal procedure (Wada).

* See Table 1.

† FDG-PET hypometabolism categories modified from Henry et al (16).

‡ PET cameras were either an ECAT IV (IV) or an ECAT 951/31 (951).

§ Engel's classification of postsurgical seizure outcome (38).

scanner (cases 4, 10, 18, and 28) and two with the ECAT 951/31 (cases 27 and 28). In five of these six patients, MR spectroscopy lateralized seizure onset ipsilateral to the side depicted by EEG and MR imaging. Of these five patients, three (cases 4, 10, and 27) had only hippocampal sclerosis at MR imaging whereas two (cases 18 and 25) had signal changes in the anterior temporal lobe in addition to hippocampal sclerosis.

To date, a final decision concerning surgery has been reached in 23 of the 25 patients with lateralized temporal lobe epilepsy (Table 2): 17 have had surgery and two are scheduled for surgery in the near future. Depth electrode studies showed regional rather than focal onset in two patients (cases 2 and 13) and these patients were not operated on; one patient (case 4)

refused surgery, and one patient (case 10) could not be operated on because of discrepant results in the intracarotid amytal procedure (3). Among those who had surgery, two patients (cases 18 and 25) had ipsilateral abnormalities at MR spectroscopy and no FDG hypometabolism, and five patients (cases 6, 15, 17, 20, and 29) had ipsilateral FDG hypometabolism and nonlateralizing MR spectroscopic values. In two patients (cases 19 and 28), no consensus was reached. Pathologic examination showed clear signs of sclerosis in all patients who went to surgery. The quantitative correlation between the MR spectroscopic or PET data and the severity of the pathologic changes was not examined.

The patients with nonlateralized refractory epilepsy (four of 29; cases 12, 16, 22, and 26), none of

TABLE 3: PET versus MR spectroscopy in lateralization of temporal lobe epilepsy

MR Spectroscopy*	PET Hypometabolism†		
	None	Unilateral	Bilateral
Lateral L or R	5 (0)	9 (1)	0 (0)
Bilateral L or R	1 (0)	5 (1)	0 (0)
Bilateral	0 (0)	4 (1)	1 (1)‡

* Categorization from Table 1.

† FDG-PET hypometabolism categories modified from Henry et al (16).

‡ This patient had bilateral temporal hypometabolism on PET scans, but worse on the side of the epileptic focus.

whom had surgery, were considered to have temporal lobe epilepsy on grounds of the ictal symptoms and the presence of typical anamnestic findings (aura, loss of consciousness). Lateralized MR imaging findings were present in three of these four. All had lateralized FDG hypometabolism (three typical, one complex), two patients (cases 12 and 26) had seizures lateralized to the same side as the hypometabolism via MR spectroscopy, and two (cases 16 and 22) had symmetric, bilateral low NAA/(Cho+Cr). The patient with temporal lobe epilepsy and bilateral independent seizure activity (case 16) had atrophy of the left hippocampus as the only MR imaging abnormality; MR spectroscopy was nonlateralizing, but bilateral temporal lobe hypometabolism was seen on PET scans, worse on the right side. No other discrepancies were found. One subject (case 12), in whom seizures were not lateralized with EEG or MR imaging, had seizures lateralized to the same side via both PET and MR spectroscopy.

With MR imaging, signs of hippocampal damage (atrophy and signal changes) were found in 19 of 29 patients with temporal lobe epilepsy and, of these, nine had more widespread signal changes in the temporal lobe on T1-weighted inversion recovery images (signal decrease and visual volume loss). In 42 temporal lobes, a low NAA/(Cho+Cr) ratio was found, whereas only 25 temporal lobes showed hypometabolism at PET (Table 2). All temporal lobes with hypometabolism on PET had abnormally low NAA/(Cho+Cr) ratios.

Discussion

The sampling location for the MR spectra and the regional abnormalities described on PET scans are not spatially identical. Most of the signal of the MR spectra in our study came from the deep temporal white matter, only a small fraction was from the hippocampus (3); on the other hand, most of the metabolic abnormalities seen on the PET scans were in cortical areas.

Since NAA is considered a neuronal marker, its signal in our spectra was produced by the NAA in the axons of the fibers in the deep white matter and partly by mesial gray matter structures (mainly the hippocampus). These axons originate in part from pyra-

midal cells of the temporal neocortex and the mesial structures (hippocampus and amygdala). Pathologic studies in patients with mesial temporal lobe epilepsy have shown that such abnormalities as neuronal loss and astrocytic reactions often extend beyond the hippocampus (24, 25). In one recent study (26), the most important FDG hypometabolism was reported to be in the hippocampus and the anterior temporal lobe, and it was attributed to neuronal loss. Other researchers have found a more pronounced glucose hypometabolism in the lateral temporal neocortex than in the mesial areas (12–14, 16, 19), and have conjectured that this is not always the result of a diminished number of neurons. The precise mechanism of this widespread hypometabolism is unclear, and different explanations have been proposed (27). Consequently, and because of its limited spatial resolution, PET is not capable of depicting the precise seizure focus; however, its reported sensitivity and specificity in depicting regional hypometabolism in the afflicted temporal lobe in patients with temporal lobe epilepsy are high (15).

Single-voxel proton MR spectroscopy gives an indication as to which is the side of epileptogenesis, because metabolites in standardized voxels are analyzed in both temporal lobes (3). Although there is a trend toward the use of chemical-shift imaging for the regional assessment of NAA in epilepsy (28–30) (Ende et al, "Quantitative..."; Duc et al, "Investigation..."), we were unable to perform this technique with the equipment used for the patients described here. One study compared PET with chemical-shift imaging in the cerebellar hemisphere. In a patient with cerebellar diaschisis, NAA was more abundant in the white matter than in the cortex (31). FDG hypometabolism in the cerebellar cortex was accompanied by a decrease in NAA, mainly in the white matter. Therefore, it is reasonable to assume that metabolic alterations seen in the spectra and the changes in glucose metabolism depicted by PET may be attributed to the same cells.

Our study shows more temporal lobes with abnormal NAA/(Cho+Cr) ratios than with FDG hypometabolism. In most of our patients, the imaging abnormalities were confined to the hippocampus (Table 2). Of 42 temporal lobes with low NAA/(Cho+Cr) ratios, only 25 showed hypometabolism on PET scans (Table 3), and all temporal lobes with hypometabolism at PET had an abnormally low NAA/(Cho+Cr) ratio. Furthermore, six patients had normal PET findings. Four of these patients had unilateral low NAA/(Cho+Cr), ipsilateral to the side predicted by EEG and MR imaging abnormalities, and one subject had bilateral low NAA/(Cho+Cr) ratios, but had concordant seizure lateralization with EEG and MR imaging on the asymmetry index. One last patient had no abnormalities on either PET scans or MR spectra. This indicates that a low NAA, depicted here as a low NAA/(Cho+Cr) (3, 32), is a more sensitive marker of neuronal dysfunction than is glucose hypometabolism depicted by PET. If we accept the hypothesis that the metabolite changes depicted on MR spectra and PET

scans are co-localized to the same cells, it is possible that the glucose hypometabolism represents a more advanced state of neuronal damage than does low NAA. Diminished NAA/(Cho+Cr) and glucose metabolism may be sequential and may result from neuronal exhaustion and microstructural or metabolic reorganization after prolonged epilepsy.

Repeated electrical stimulation can produce electrophysiologic, metabolic, and perhaps even morphological changes in local tissue (33). It is known that stimulus-produced seizure activity can be progressively intensified by repeated high-frequency stimulation of certain components of the limbic system at intervals ranging from minutes to days (34, 35). The mechanism underlying this "kindling" may be similar to long-term potentiation, in which brief periods of intense electrical activity give rise to a persistent change in synaptic activity.

It is then possible that the epileptic focus, of which the substrate often is hippocampal sclerosis, initiates a seizure. Electrical signals are propelled to connecting neurons locally and regionally, but in certain instances also to areas farther away and to the contralateral side. Neurotransmitter imbalances result first, and more advanced metabolic alterations, such as diminished glucose metabolism, build over years of epileptic activity. This leads to a weakening of the neurons and eventually to cell death and diminished neuronal cell counts. Coregistration of PET images and metabolic maps from chemical-shift imaging studies may provide an answer to this enigma, as local NAA concentration can be shown with this technique (28–30).

It has been shown that regional hypometabolism can recover in unresected areas after temporal lobectomy for temporal lobe epilepsy (36). This means that, to some extent, the changes in metabolism are reversible. Regional interictal hypometabolism in temporal lobe epilepsy can, in some cases, be accounted for by a diminished neuronal count, but it is clear that other factors related to epilepsy also contribute to metabolic dysfunction (27).

The exact mechanism of neuronal damage or dysfunction is unclear (27), as is the possible relationship between low NAA and glucose hypometabolism. Despite the fact that NAA is present in high concentrations within the brain, little is known about its role in normal function or disease states (37). Studies have suggested that NAA is largely but not exclusively present in neurons and that NAA is more abundant than aspartate (38, 39). Glutamate and aspartate meet many of the criteria for excitatory neurotransmitters, and are used by some of the most widely distributed neuronal types. The metabolism of glutamate, aspartate, and NAA is linked to the mitochondria. Both aspartate and glutamate are nonessential amino acids and are synthesized from glucose and other precursors (40). As a reaction to seizures in temporal lobe epilepsy, probable changes in aspartate and glutamate metabolism result in a lowering of the NAA pool in interconnecting neurons.

Glucose is also used as the main energy source for

neurons. A diminished glucose uptake as depicted by PET is a reflection of a diminished glucose use rate in the tricarboxylic acid cycle of the neurons and a lower oxidation state, again a mitochondrial function. It is likely that the metabolic abnormalities depicted here by MR spectroscopy and PET are linked through mitochondrial dysfunction.

Conclusion

Our study indicates that single-voxel proton MR spectroscopy is more sensitive in depicting metabolic abnormalities than is FDG-PET, and, therefore, patients with a negative PET scan benefit from spectroscopic studies to help lateralize the seizure foci. The possible relationship between low glucose uptake and use as shown on PET scans and a low NAA level as seen at MR spectroscopy remains unclear.

References

1. Achten E, Boon P, De Poorter J, et al. A current optimum MR protocol for the pre-surgical work-up of patients with complex partial seizures of temporal lobe origin. *AJNR Am J Neuroradiol* 1995;16:1201–1213
2. Boon PA, Williamson PD. Presurgical evaluation of patients with intractable partial seizures: indications and evaluation techniques for resective surgery. *Clin Neurol Neurosurg* 1989;91:3–11
3. Achten E, Boon P, Van De Kerckhove T, Caemaert J, De Reuck J, Kunnen M. The value of different parameters from single-voxel proton MR spectroscopy in unilateral temporal lobe epilepsy. *AJNR Am J Neuroradiol* (in press)
4. Weiser HG, Engel JJ, Williamson PD, Babb TL, Goor P. Surgically remedial temporal lobe syndromes. In: Engel JJ, ed. *Surgical Treatment of the Epilepsies*. 2nd ed. New York, NY: Raven Press; 1993; 49–64
5. Boon P, Calliauw L, Van De Kerckhove T, et al. Epilepsy surgery: the Flemish experience. *Acta Neurol Belg* 1996;96:1–18
6. Matthews PM, Andermann F, Arnold DL. A proton magnetic resonance spectroscopy study of focal epilepsy in humans. *Neurology* 1990;40:985–989
7. Peeling J, Sutherland G. High-resolution ¹H NMR spectroscopy studies of extracts of human cerebral neoplasms. *Magn Reson Med* 1992;24:123–136
8. Peeling J, Sutherland G. ¹H magnetic resonance spectroscopy of extracts of human epileptic neocortex and hippocampus. *Neurology* 1993;43:589–594
9. Connelly A, Jackson GD, Duncan JS, King MD, Gadian DG. Magnetic resonance spectroscopy in temporal lobe epilepsy. *Neurology* 1994;44:1411–1417
10. Gadian DG, Connelly A, Duncan JS, et al. ¹H magnetic resonance spectroscopy in the investigation of intractable epilepsy. *Acta Neurol Scand Suppl* 1994;152:116–121
11. Jackson GD. New techniques in magnetic resonance and epilepsy. *Epilepsia* 1994;35:S2–S13
12. Sackellares JC, Siegel GL, Abou-Khalil BW, et al. Differences between lateral and mesial temporal metabolism interictally in epilepsy of temporal origin. *Neurology* 1990;40:1420–1426
13. Engel J Jr, Brown WJ, Kuhl DE, Phelps ME, Mazziotta JC, Crandall PH. Pathological findings underlying focal temporal lobe hypometabolism in partial epilepsy. *Ann Neurol* 1982;12:518–528
14. Theodore WH. MRI, PET, SPECT: interrelations, technical limits, and unanswered questions. *Epilepsy Res* 1992;5:127–134
15. Spencer SS. The relative contributions of MRI, SPECT and PET imaging in epilepsy. *Epilepsia* 1994;35:S72–S89
16. Henry TR, Chugani HT, Abou-Khalil BW, Theodore WH, Swartz BE. Positron emission tomography. In: Engel JJ, ed. *Surgical Treatment of the Epilepsies*. 2nd ed. New York, NY: Raven Press; 1993: 211–232
17. Debets RMC, van Veelen CWM, Maquet P, et al. Quantitative analysis of ¹⁸FDG-PET in the presurgical evaluation of patients suffering from refractory partial epilepsy: comparison with CT,

- MRI and combined subdural and depth EEG.** *Acta Neurochir* 1990;50:88–94
18. Engel J Jr, Kuhl DE, Phelps ME, Crandall PH. **Comparative localization of epileptic foci in partial epilepsy by PET and EEG.** *Ann Neurol* 1982;12:529–537
 19. Henry TR, Engel J Jr, Babb TL, Mazziotta JC, Phelps ME, Crandall PH. **Hippocampal neuronal loss and regional hypometabolism in temporal lobe epilepsy.** *Arch Neurol* 1994;36:925–927
 20. Radtke RA, Hanson MW, Hoffman JM, et al. **Temporal lobe hypometabolism on PET: predictor of seizure control after temporal lobectomy.** *Neurology* 1994;44:583–585
 21. Giroud-M, Walker-P, Bernard-D, et al. **Preliminary observations of metabolic characterization of bilateral temporal epileptic focus, using proton magnetic resonance spectroscopy: three cases.** *Neurol Res* 1994;16:481–483
 22. Bottomley PA. **Spatial localization in NMR spectroscopy in vivo.** *N Y Acad Sci* 1987;508:333–348
 23. Klose U. **In vivo proton spectroscopy in the presence of eddy currents.** *Magn Reson Med* 1990;14:26–30
 24. Falconer MA. **Mesial temporal (Ammon's horn) sclerosis as a common cause of epilepsy: aetiology, treatment and prevention.** *Lancet* 1974;2:767–770
 25. Bruton CJ. **The Neuropathology of Temporal Lobe Epilepsy.** Oxford, England: Oxford University Press; 1988:1–158
 26. Semah F, Baulac M, Hasboun D, et al. **Is interictal temporal hypometabolism related to mesial temporal sclerosis? A positron emission tomography/magnetic resonance confrontation.** *Epilepsia* 1995;36:447–456
 27. Henry TR. **Functional neuroimaging with positron emission tomography.** *Epilepsia* 1996;37:1141–1154
 28. Layer G, Traber F, Muller-Lisse U, Bunke J, Elger CE, Reisers M. **Spectroscopic imaging [in German].** *Radiologe* 1993;33:178–184
 29. Cendes F, Andermann F, Preul MC, Arnold DL. **Lateralization of temporal lobe epilepsy based on regional metabolic abnormalities in proton magnetic resonance spectroscopic images.** *Ann Neurol* 1994;35:211–216
 30. Hetherington H, Kuzniecky R, Pan J, et al. **Proton nuclear magnetic resonance spectroscopic imaging of human temporal lobe epilepsy at 4.1 T.** *Ann Neurol* 1995;38:396–404
 31. Fulham MJ, Dietz MJ, Duyn JH, Henry HL, Alger JR, Di Chiro G. **Transsynaptic reduction in N-acetyl-L-aspartate in cerebellar diaschisis: a proton MR spectroscopic imaging study.** *J Comput Assist Tomogr* 1994;18:697–704
 32. Kuzniecky RI, Jackson GD. **Magnetic resonance spectroscopy in epilepsy.** In: Kuzniecky RI, Jackson GD, eds. *Magnetic Resonance in Epilepsy.* New York, NY: Raven Press; 1995:289–314
 33. Martin JH. **The collective electrical behaviour of cortical neurons: the electroencephalogram and the mechanisms of epilepsy.** In: Kandel ER, Schwartz JH, Jessell TM, eds. *Principles of Neural Science.* 3rd ed. New York, NY: Elsevier; 1991:777–791
 34. Spencer EA, Kandel ER. **Electrophysiology of hippocampal neurons, IV: fast prepotentials.** *J Neurophysiol* 1961;24:272–285
 35. Goddard GV. **Development of epileptic seizures through brain stimulation at low intensity.** *Nature* 1967;214:1020–1021
 36. Hajek M, Wieser HG, Kahn N, et al. **Preoperative and postoperative glucose consumption in mesiotemporal and lateral temporal lobe epilepsy.** *Neurology* 1994;44:2125–2132
 37. Miller BL. **A review of chemical issues in 1H NMR spectroscopy: N-acetyl-aspartate, creatine and choline.** *NMR Biomed* 1991;4:47–52
 38. Tallan HH. **Studies on the distribution of N-acetyl-aspartic acid in brain.** *J Biol Chem* 1956;224:41–45
 39. Koller KJ, Zaczek R, Cole J. **N-acetyl-aspartyl-glutamate: regional levels in rat brain and effects of brain lesions as determined by a new HPLC method.** *J Neurochem* 1984;43:1136–1142
 40. Thomas RJ. **Excitatory amino acids in health and disease.** *J Am Geriatr Soc* 1996;43:1279–1289
 41. Engel JJ. **Seizures and Epilepsy.** Philadelphia, Pa: Davis; 1989

Please see the Editorial on page 189 in this issue.