



Discover Generics

Cost-Effective CT & MRI Contrast Agents



WATCH VIDEO

AJNR

Intracranial angioplasty: experience and complications.

C Takis, E S Kwan, M S Pessin, D H Jacobs and L R Caplan

AJNR Am J Neuroradiol 1997, 18 (9) 1661-1668

<http://www.ajnr.org/content/18/9/1661>

This information is current as
of June 22, 2025.

Intracranial Angioplasty: Experience and Complications

Constantino Takis, Eddie S. Kwan, Michael S. Pessin,* Daniel H. Jacobs, and Louis R. Caplan

PURPOSE: To review our experience with intracranial angioplasty, including the complications we encountered. **METHODS:** During a 3-year period, from 1993 to 1996, 10 patients had intracranial percutaneous transluminal angioplasty (PTA). The stenosed vessels included three internal carotid arteries, one middle cerebral artery, one basilar artery, and five vertebral arteries. Stenosis in all patients was 75%, or greater. PTA was technically successful in eight patients; in two patients it could not be performed owing to inability to traverse the stenosed area. **RESULTS:** Two patients had successful and uneventful PTA. Five patients had vasospasm, which resolved with local vasodilators in two and with repeat PTA in one. Vasospasm led to stroke in two patients. Compromise of perforating vessels and arterial dissection were associated with stroke in two patients. **CONCLUSION:** Intracranial PTA is technically feasible but associated with risks related to vasospasm, arterial trauma, and compromise of perforating vessels.

Index terms: Arteries, transluminal angioplasty; Atherosclerosis; Interventional neuroradiology, complications

AJNR Am J Neuroradiol 18:1661–1668, October 1997

Percutaneous transluminal angioplasty (PTA) is an endovascular technique described in 1964 by Dotter and Judkin (1) for the treatment of peripheral vascular atherosclerotic stenosis. Since then, extensive experience has accumulated in its use in the coronary, renal, and iliofemoral circulations. PTA now has an established role in the treatment of atherosclerotic stenosis in these circulations.

Reports of transluminal angioplasty of the extracranial and intracranial circulations appeared in 1980. Kerber et al (2) reported common carotid artery angioplasty, and Sundt et al (3) reported two basilar artery angioplasties. Experience with PTA for atherosclerotic and nonatherosclerotic narrowing of extracranial arteries has grown. The complications and restenosis rates have been low, and we know of no mortalities related to the procedure reported in published series (4–13).

In contrast, few reports are available about the use of PTA for intracranial atherosclerotic stenosis. Factors that probably delayed use of PTA for treatment of intracranial disease include the fear of distal embolization, the risk of occluding perforating arteries, and the unavailability, until recently, of a balloon catheter system that could negotiate the tortuous course of the intracranial vasculature. The indications, complications, and outcome of intracranial PTA are not well established. We report our experience with intracranial PTA and review the major problems encountered, in an effort to broaden the discussion of this potentially important procedure.

Materials and Methods

During a 3-year period, from 1993 to 1996, 10 patients with symptomatic atherosclerotic intracranial arterial and skull-base stenosis were treated via PTA at our institution. They were five men and five women, with a mean age of 65 years (range, 42 to 76 years). The initial presentation was stroke in three patients and transient ischemic attacks (TIAs) in seven patients. Of the seven patients with TIAs, two had a stroke before PTA could be undertaken.

* Deceased.

Received February 26, 1997; accepted April 27.

From the Departments of Neurology (C.T., D.H.J., L.R.C.) and Radiology (E.S.K.), Tufts University School of Medicine, New England Medical Center, Boston, Mass.

Address reprint requests to Louis R. Caplan, MD, Department of Neurology, New England Medical Center, 750 Washington St, Boston, MA 02111.

Clinical findings, imaging features, and outcome in 10 patients treated with intracranial percutaneous transluminal angioplasty (PTA)

| Case | Age, y/Sex | Clinical Findings | MR Imaging | Angiography | Complications | Best Angiographic Outcome after PTA | Follow-up |
|------|------------|--|--|---|---|---|--|
| 1 | 42/F | TIA of R hemiparesis, then stroke with dysarthria, R hemiparesis; multiple R limb shaking TIAs for 2 mo | L ACA-MCA border zone infarct | 90% stenosis of L ICA supraclinoid | Vasospasm 13 min later; stroke 6 h later | 20% to 30% residual stenosis (1 d later) | Stable for 5 mo on warfarin; died after CABG |
| 2 | 65/F | Multiple TIAs of LUE/LLE shaking, and of LUE/LLE weakness for 3 mo | R ACA-MCA border zone infarct | 90% stenosis of R supraclinoid ICA | None | <10% residual stenosis | 2 wk later L leg shaking, which resolved with anticonvulsants; stable for 4 wk on warfarin |
| 3 | 64/M | Multiple TIAs of aphasia/RUE weakness for 3 mo | Infarct in anterior limb of L internal capsule; L ACA-MCA border zone infarcts | 80% stenosis of petrous R ICA; L ICA occluded | None | 40% residual stenosis | Stable for 2 mo on warfarin; died after CABG |
| 4 | 62/F | 3 episodes of transient dysarthria for 10 d; 2 wk later stroke with dysarthria and R hemiparesis | Infarcts in L centrum semiovale and L frontal operculum | 90% stenosis of L M1 MCA | Vasospasm 2 h later with stroke | Normal diameter (2 d later) | Stable for 5 mo on warfarin |
| 5 | 75/F | Stroke with hypersomnolence, dysarthria, poor memory, vertical gaze palsy, R ataxia, R hypoaesthesia | Bilateral cerebellar, bilateral pontine thalamic, and R occipital infarcts | 99% R ICVA stenosis proximal to PICA; L intracranial VA occluded | Transient vasospasm | 40% residual stenosis | Stable for 20 mo on warfarin |
| 6 | 56/M | 10 TIAs of vertigo, blurred vision, diplopia, unsteadiness for 1 mo | Normal | 99% L VA stenosis distal to PICA; high-grade R VB junction stenosis | Vasospasm 8 min later, resolved with repeat PTA | 50% residual stenosis | Asymptomatic for 30 mo on aspirin |
| 7 | 66/M | Multiple TIAs of L perioral numbness, vertical diplopia for 1 mo; same TIAs recurred 7 mo later | L cerebellar infarct | 75% R VA stenosis distal to PICA; L intracranial VA occluded | Arterial dissection; stroke | Normal lumen at PTA site; arterial dissection still present (1 d later) | Stable 2 mo later on warfarin |
| 8 | 70/M | Multiple TIAs of dysarthria, alternating numbness/weakness or quadriparesis for 4 d | L pontine infarct | 95% mid-BA stenosis | Transient vasospasm; stroke | 10% to 20% residual stenosis | Stable for 10 mo on warfarin |
| 9 | 76/M | Stroke with L homonymous hemianopia in 1988; 5 y later multiple TIAs of dysarthria, diplopia, dizziness, ataxia for 1 y; memory loss 1 y after onset of TIAs | R occipital, bilateral cerebellar, and bilateral thalamic | 90% L VA stenosis proximal to PICA and 99% stenosis at VB junction; high-grade R VA stenosis proximal to PICA | Failed PTA | . . . | Stable for 9 mo on warfarin |

Continues

TABLE: Continued

| Case | Age, y/Sex | Clinical Findings | MR Imaging | Angiography | Complications | Best Angiographic Outcome after PTA | Follow-up |
|------|------------|---|--|---|---------------|-------------------------------------|-----------|
| 10 | 73/F | TIA of dysarthria, numbness of L face/R hand, R facial droop in 1990; 1 y later stroke with R limb/gait ataxia; 3 y later stroke with vertigo, dysarthria, R arm weakness | Bilateral pontine; bilateral thalamic; bilateral occipital and R cerebellar infarcts | 90% L VA stenosis distal to PICA and 99% stenosis at junction with BA; R intracranial VA occluded | Failed PTA | ... | None |

Note—ACA indicates anterior cerebral artery; MCA, middle cerebral artery; CABG, coronary artery bypass graft; LUE, left upper extremity; LLE, left lower extremity; IC, internal capsule; RUE, right upper extremity; VA, vertebral artery; PICA, posterior inferior cerebellar artery; VB, vertebrobasilar; and BA, basilar artery.

Neurovascular examination consisted of computed tomography (CT), magnetic resonance (MR) imaging, MR angiography, or duplex imaging of the internal carotid artery (ICA) and vertebral arteries, and transcranial Doppler sonography. Cerebral angiography documented the stenosis. All patients were treated with maximal medical therapy, consisting of oral anticoagulants, and in selected patients, addition of antiplatelet agents or modification of an antihypertensive regimen. Patients were considered for PTA when this regimen failed and they continued to have ischemic events. Informed consent was obtained from all participants.

The stenosed vessels consisted of five intracranial vertebral arteries, one basilar artery, three ICAs (one petrous and two supraclinoid segments), and one middle cerebral artery (MCA) at the M1 segment. The degree of stenosis was 75% or greater in all patients, measured by the ratio of luminal diameter at the level of the stenosis to the luminal diameter immediately proximal to the stenosis. Four patients had the procedure under general anesthesia, and six patients were conscious with intravenous midazolam sedation. In seven patients, arterial access was via a transfemoral approach, and in the other three patients a transbrachial approach was used. All the procedures were done under systemic heparinization, which was continued for at least 24 hours after PTA. In three patients, nitroglycerin was infused into the stenotic vessel before crossing it with the microguidewire and angioplasty balloon catheter. Four patients were on nimodipine before and after the procedure, and one patient was started on aspirin 1 week before the procedure. A Stealth balloon catheter (Target Therapeutics, Fremont, Calif) was used in five patients, and an autoperfusion flowtrack coronary angioplasty balloon catheter (Advanced Cardiovascular Systems, Santa Clara, Calif) was used in three patients. PTA was performed in eight patients and technical failure due to inability to traverse the stenosed area with the balloon catheter occurred in two patients with severe tandem vertebral artery stenoses. The arteries subjected to PTA were slightly underdilated to prevent potential rupture of the vessel. A technically successful PTA was defined as one leaving a residual stenosis of 50% or less. Patients have been followed up

with MR angiography and transcranial Doppler sonography to check for restenosis. No follow-up angiographic studies have been done.

Results

The clinical presentation, imaging studies, angiographic findings, outcome, and follow-up findings are summarized in the Table and in Figure 1.

ICA Angioplasty

Three patients had PTA of the ICA, two in the supraclinoid segment and one in the petrous segment. A 90% stenosis was present in both patients with lesions of the supraclinoid segment. In one of these patients, PTA was done with a 3-mm autoperfusion flowtrack balloon catheter, with a total of two dilatations for 60 seconds each at 6 atm. Vasospasm was seen 13 minutes later at the angioplasty site, and it did not resolve with local infusion of 180 mg of papaverine. Occlusion of the posterior temporal and angular artery was seen, presumably from distal embolization. A repeat PTA was not attempted. Six hours later, on waking from general anesthesia, the patient was aphasic with a right facial droop and mild right hemiparesis. Angiography the next day revealed a 20% to 30% residual stenosis, and CT showed a new left frontal infarct. The occlusions of the posterior temporal and angular arteries persisted with no area of infarction noted in this area on the CT scan. Over the next 5 months, the patient remained stable on warfarin, but then died after a coronary artery bypass graft procedure. At autopsy, intimal hyperplasia and fragmentation of

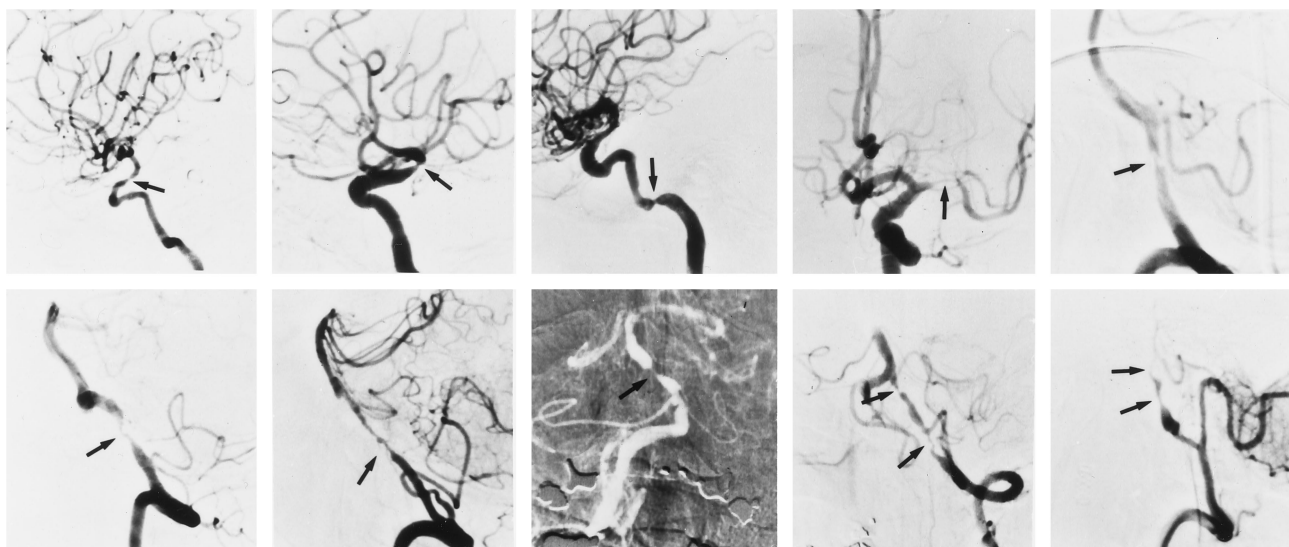


Fig 1. Angiograms obtained before PTA in all 10 patients show the areas of stenosis (see text and Table for details).

the internal elastic lamina was present in the supraclinoid segment of the ICA. The other patient had PTA done with a 3-mm Stealth balloon catheter at 6 atm for 30 seconds. Residual stenosis was less than 10%. The patient was discharged on warfarin. Two weeks later, an episode of left leg shaking occurred, which lasted a few minutes, and 2 days later she had transient stiffness of the left leg. Her blood pressure and level of anticoagulation were adequate, and MR imaging did not show any new area of infarction. MR angiography and transcranial Doppler sonography corroborated the patency of the supraclinoid segment of the ICA. An electroencephalogram showed slowing in the right temporal area. It was concluded that seizures were the cause, and anticonvulsants were started. At 4 weeks, the patient had no further seizures or brain ischemia.

The third patient had a 90% stenosis of the left petrous ICA and an 80% stenosis of the right petrous ICA on angiograms obtained at an outside institution. At angiography performed before PTA, the symptomatic left ICA was occluded. Because insufficient collateral flow to the left MCA came from the right ICA, PTA was performed in the right ICA. A 4-mm autoperfusion flowtrack balloon catheter was used with one dilation for 45 seconds at 6 atm. A small subintimal tear was seen. Repeat angiography performed the next day showed a smooth residual stenosis of 40%, with no intimal tear. The patient was discharged on warfarin and was asymptomatic for 2 months, at which time he

died after a coronary artery bypass graft procedure.

MCA Angioplasty

PTA was performed in one patient with a 90% stenosis of the MCA at the M1 segment. Initially, two dilatations were performed with a 2-mm Stealth balloon catheter for 30 seconds at 6 atm with no improvement of the stenotic lumen. Two more dilatations were performed with a 3-mm Stealth balloon catheter for 30 seconds at 6 atm. No residual stenosis was noted on the angiogram obtained immediately after PTA (Fig 2A). A subtle filling defect was seen 15 minutes later for which local urokinase was given with residual luminal irregularity. The patient was extubated 1 hour later with no change in the baseline neurologic examination. One hour later, aphasia and a right hemiplegia developed. Emergency angiography showed an MCA occlusion at the angioplasty site, presumably due to vasospasm (Fig 2B). Significant resolution of the vasospasm was obtained after local infusion of 300 mg of papaverine, and 20 mg of alteplase was given for thrombolysis. Because the vasospasm persisted, repeat PTA was attempted with the 3-mm Stealth balloon catheter but was unsuccessful owing to an inability to traverse the stenosis. The vasospasm persisted, with no response to additional local infusion of papaverine, and extended to involve the superior and inferior divisions of the MCA. The procedure was stopped 6 hours after the onset of

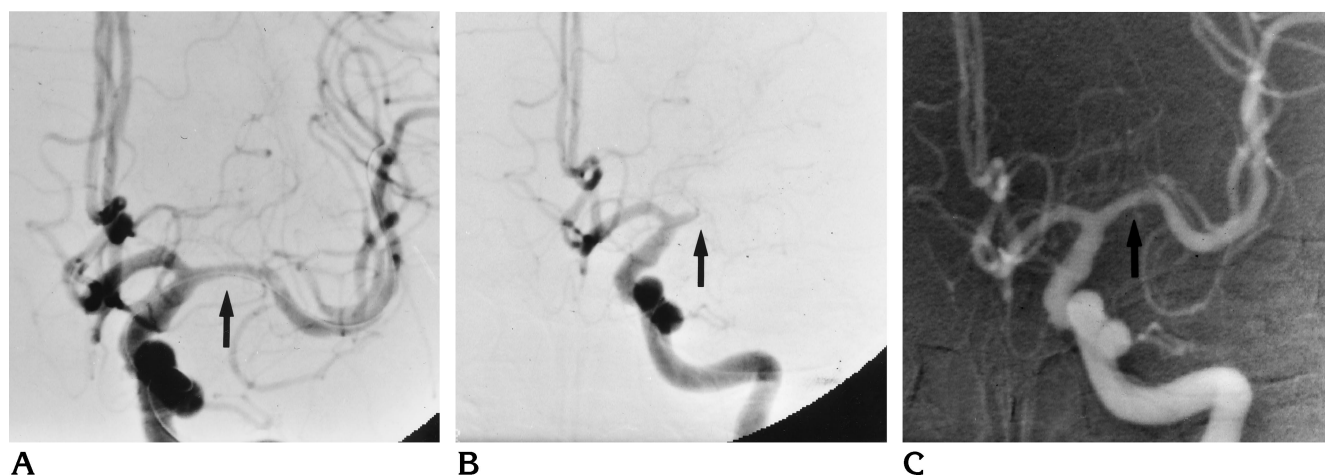


Fig 2. Case 4.

A, Angiogram obtained after PTA shows no residual stenosis of the MCA.

B, Emergency angiogram 2 hours later, after aphasia and right hemiplegia developed, shows an MCA occlusion at the angioplasty site.

C, Angiogram 2 days later shows the MCA has a normal diameter.

aphasia and hemiplegia, with no change in the patient's clinical status. A CT scan showed a large MCA territory infarct. A repeat angiogram obtained 2 days later showed a normal diameter MCA (Fig 2C). Five months later the patient was still aphasic, but otherwise fully functional on warfarin.

Vertebral Artery Angioplasty

Three patients had vertebral artery PTA; in one patient, the lesion was proximal to the posterior inferior cerebellar artery (PICA) and in two patients it was distal to the PICA. In the patient with a 99% stenosis proximal to the PICA, PTA was performed with a 3-mm Stealth balloon catheter, with a total of three dilatations of 15 seconds each at 5.5 atm. Vasospasm developed immediately at the angioplasty site, which resolved with local infusion of 100 mcg of nitroglycerin. Residual stenosis was 40%. At 20 months' follow-up the patient was clinically stable on warfarin, and MR angiography showed a patent vertebral artery with mild stenosis.

One of the two patients with vertebral artery stenosis distal to the PICA and a 99% stenosis had PTA with a 3-mm autoperfusion flowtrack balloon catheter at 5 atm for 20 seconds. Occlusion of the vertebral artery at the angioplasty site developed 8 minutes later, presumably due to vasospasm, which did not resolve with local infusion of 30 mg of papaverine. Repeat PTA with a similar 3.5-mm balloon catheter at 5 atm for 20 seconds led to resolution of the vaso-

spasm. The residual stenosis was 50%. The patient remained on warfarin for 6 months and was then switched to aspirin. MR angiography 12 months later showed a patent vertebral artery with slight residual stenosis. The patient was asymptomatic at 30 months. The other patient with 75% stenosis had PTA with a 3-mm Stealth balloon catheter at 6 atm for 45 seconds. Angiography performed after PTA showed a subintimal dissection starting at the distal portion of the angioplasty site and extending into the mid-basilar region with moderate luminal compromise. Nonetheless, flow in the basilar artery appeared improved on the basis of visibility of the posterior cerebral arteries. Angiography performed the next day still showed the dissection with an unchanged degree of luminal compromise, but no residual stenosis at the angioplasty site. The same day, a right ataxic hemiparesis developed, which slowly improved. No infarct was seen at MR imaging. The patient was discharged on warfarin and at the 2-month follow-up had improved significantly with no further TIAs.

Basilar Artery Angioplasty

PTA was performed in one patient with a 95% stenosis of the mid basilar artery distal to the anterior inferior cerebellar arteries. A 2.5-mm Stealth balloon catheter was used with five dilatations performed for 30 seconds each at 6 atm. Angiography performed after PTA showed vasospasm, which resolved with local infusion

of 30 mg of papaverine. Ten hours later dysarthria and a left hemiparesis developed. An angiogram the next day showed a widely patent basilar artery with a residual stenosis of 10% to 20%, unchanged from the previous day. An MR study confirmed a new infarct in the right basis pontis in the territory of a pontine perforator. Ten months later, the patient was fully independent, with slight residual hemiparesis. MR angiography 12 months later revealed a greater than 50% stenosis of the middle basilar artery, with no new areas of infarction on MR images. The patient remains on warfarin with no further TIAs.

Discussion

The complications and outcomes of intracranial PTA for the treatment of symptomatic atherosclerotic stenosis are not well established. In a review of the English-language literature, we found 98 cases of intracranial PTA, of which the great majority were reported in the last few years (3–5, 12, 14–22) (M. Marks, A. Norbash, J. Clark, G. Albers, G. Steinberg, "Angioplasty of Intracranial Circulation Stenosis" [abstract], *Stroke* 1995, 16:159). In all cases, maximal medical therapy had failed before PTA was undertaken. This is an important point, since intracranial PTA is still an experimental treatment and has not been shown to be superior to conventional treatments in controlled studies.

We were able to perform PTA in eight of 10 patients. Technical success, based on our definition of a residual stenosis of 50% or less, was achieved in all of eight patients. Technical failure occurred in two patients with high-grade tandem vertebral artery stenoses. The complications encountered included stroke, vasospasm, and arterial dissection. In terms of clinical outcome, five patients (63%) had a good outcome and three patients (37%) had an unfavorable outcome. There were no procedure-related deaths.

The stroke rate in our small series was 50% (four of eight patients), higher than in other series. Higashida et al (4) found a 33% stroke rate in 18 patients, Touho (19) reported a 15% rate in 13 patients, Clark et al (18) had a 9% rate in 22 patients, and McKenzie et al (20) reported an 8% stroke rate in 12 patients. Three of the four patients with stroke in our series had significant residual disabilities.

Strokes associated with PTA can be caused by arterial dissection, distal embolization, vaso-

spasm, vessel rupture, or from occlusion of perforating vessels. Compromise of penetrating vessels was the presumed cause of stroke first reported by Sundt et al (3), in which their patient had a gaze paresis and nystagmus the day after basilar artery PTA. Repeat angiography 8 days later documented the patency of the basilar artery, but the neurologic deficit in their patient could have been due to basilar artery spasm. The first basilar artery PTA patient described by Higashida et al (6) also had a stroke, which the authors attributed to compromise of pontine perforating vessels. Our patient with basilar artery stenosis had a paramedian pontine stroke 10 hours after PTA from suspected involvement of perforating vessels. Angiography the next day documented the wide patency of the basilar artery. The basilar artery and the M1 segment of the MCA are susceptible to this complication because of the large number of perforating vessels that arise from their parent trunks.

In five patients (63%) we observed significant vasospasm or elastic recoil following PTA. This complication has seldom been reported. Of the 98 intracranial PTAs reported in the literature, only two were associated with vasospasm. Sundt et al (3) mentioned the possibility of vasospasm causing a transient quadriplegia in their first patient, but no proof was provided. Purdy et al (15) reported severe vasospasm of the MCA, which was asymptomatic and resolved spontaneously in 45 minutes with no pharmacologic intervention. Five days later this patient's MCA was found to be occluded with no new symptoms. In the extracranial PTA group, a recent article by Eckert et al (13) reported a 65% rate of vasospasm in 54 ICA PTAs.

The striking absence of reports of vasospasm during and after intracranial angioplasty has several possible explanations. Serial angiograms may not be obtained after PTA if no symptoms are observed. Vasospasm might have been observed and successfully treated, so no comment was made. Last, it might be uncommon. Vasospasm may be asymptomatic, as in the case of Purdy et al (15). In three of our five patients, it was asymptomatic, and rapid treatment led to its resolution, in contrast to the case reported by Purdy et al (15), in which no treatment was given. In two of our patients, vasospasm was noted immediately after angioplasty, and in the other three, it was delayed (8 minutes, 13 minutes, and 2 hours, respectively). Of these three patients with de-

layed vasospasm, two had stroke. Whether delayed vasospasm carries a higher morbidity needs further study. Vasospasm can produce infarction by a hemodynamic (low-perfusion) mechanism with or without occlusion, and by in situ thrombosis with the possibility of distal embolization. In our two patients with vasospasm-related stroke, a hemodynamic (low-perfusion) mechanism was the probable cause in one and a thromboembolic mechanism in the other. We suggest that vasospasm be actively sought, including via delayed serial filming, and if observed, treated vigorously.

The pathogenesis of vasospasm after PTA is still not clear. Several mechanisms have been postulated in reports of coronary circulation studies: a reflex increase in myogenic tone (23), mechanical damage to the vasa vasorum (24), increased vasoreactivity to physiological constrictor stimuli, such as serotonin released by platelets adhering and aggregating at the angioplasty site (25), or the lack of the dilator effect of endothelium-derived relaxing factor from endothelial dysfunction after percutaneous transluminal coronary angioplasty (25). PTA produces intimal desquamation, splitting of the plaque (involving the intima and inner portions of the media) at its weakest point, and distension of the media (26–28). With the resulting denudation of the intima at the angioplasty site, platelet adhesion and aggregation, which have been observed in animal models, can produce the release of serotonin or thromboxane, inducing vasoconstriction (27, 29–31). Pretreatment with antiplatelet agents may benefit patients undergoing intracranial PTA. Pretreatment with aspirin or other antiplatelet agents is effective in reducing complications of percutaneous transluminal coronary angioplasty (32, 33) associated with platelet aggregation and acute thrombosis (33, 34), and should be considered with intracranial angioplasty. Higashida et al (4) recommend pretreatment with aspirin. Only one of our patients was pretreated with aspirin and had a good outcome. We pretreated four patients with calcium channel blockers: vasospasm developed in two, one immediately and the other 13 minutes later; in the other two it did not. The role of calcium channel blockers in the prevention of vasospasm in intracranial PTAs merits further investigation.

The lack of response to arterial vasodilators in two of our patients was puzzling. Experimental models and studies done in humans show

that smooth muscle mediated vasodilatation, like that induced by nitroglycerin or papaverine, is intact in the angioplasty segments (25, 29, 30). An arterial dissection is a possible explanation for lack of vasodilator response, but in one patient repeat angiography the next day showed minimal residual stenosis with no evidence of dissection. Elastic recoil can be confused with vasospasm. Elastic recoil, which is the natural tendency of an arterial wall to resume its shape after dilatation, can occur if the vessel is underdilated (35). This is the most likely explanation for the vasoconstriction in our other patient, which resolved after repeat PTA with a larger diameter balloon catheter.

Distal embolization was documented in one patient, which persisted on repeat angiography the next day. No clinical or CT evidence of infarction in this territory was documented. Distal embolization occurs in 1% of iliac PTAs (36) and has been reported in 0.2% of percutaneous transluminal coronary angioplasty procedures. DeMonte et al (38) documented release of atherosclerotic debris in an extracranial carotid PTA. Theron et al (39) reported obtaining cholesterol crystals in four of six samples from PTAs of the ICA bifurcation. Touho (19) obtained atherosclerotic debris and clots aspirated in five ICA PTAs. Markus et al (40) documented distal embolization by transcranial Doppler sonography in nine of 10 patients who had ICA PTA. All patients except one remained asymptomatic. Ferguson et al (36, 41) noted that the frequency of cerebral embolization may be low as a result of collateral vascular compensation without neuronal injury or because of subclinical brain injury, or it may occur infrequently. Our case of distal embolization in intracranial PTA, and the above-reported extracranial cases demonstrate that distal embolization does occur, and that it may be asymptomatic.

Intracranial PTA is a feasible procedure that deserves further study. Stroke from occlusion of perforating vessels can complicate PTA of the basilar artery and the M1 segment of the MCA. Pretreatment with antiplatelet agents to avoid complications from vasospasm and thrombosis at the PTA site should be studied further. Delayed vasospasm should be actively sought and treated.

References

1. Dotter CT, Judkins MP. Transluminal treatment of arteriosclerotic obstruction: description of a new technique and a preliminary report of its application. *Circulation* 1964;30:654–670

2. Kerber CW, Cromwell LD, Loehden OL. Catheter dilatation of proximal carotid stenosis during distal bifurcation endarterectomy. *AJNR Am J Neuroradiol* 1980;1:348-349
3. Sundt TM Jr, Smith HC, Campbell JK, Vlietstra RE, Cucchiara RF, Stanson AW. Transluminal angioplasty for basilar artery stenosis. *Mayo Clin Proc* 1980;55:673-680
4. Higashida RT, Tsai FY, Halbach VV, Dowd CF, Hieshima GB. Cerebral percutaneous transluminal angioplasty. *Heart Dis Stroke* 1993;2:497-502
5. Higashida RT, Tsai FY, Halbach VV, et al. Transluminal angioplasty for atherosclerotic disease of the vertebral and basilar arteries. *J Neurosurg* 1993;78:192-198
6. Higashida RT, Hieshima GB, Tsai FY, Halbach VV, Norman D, Newton TH. Transluminal angioplasty of the vertebral and basilar artery. *AJNR Am J Neuroradiol* 1987;8:745-749
7. Theron J, Raymond J, Cassasco A, Courtheoux F. Percutaneous angioplasty of atherosclerotic and post-surgical stenosis of the carotid arteries. *AJNR Am J Neuroradiol* 1987;8:495-500
8. Kachel R, Basche S, Heerklotz I, Grossmann K, Endler S. Percutaneous transluminal angioplasty (PTA) of supra-aortic arteries especially the internal carotid artery. *Neuroradiology* 1991;33:191-194
9. Tsai FY, Matovich V, Hieshima GB, et al. Percutaneous transluminal angioplasty of the carotid artery. *AJNR Am J Neuroradiol* 1986;7:349-358
10. Bockenheimer SAM, Mathias K. Percutaneous transluminal angioplasty in arteriosclerotic internal carotid artery stenosis. *AJNR Am J Neuroradiol* 1983;4:791-792
11. Porta M, Munari LM, Belloni G, Moschini L, Bonaldi G. Percutaneous angioplasty of atherosclerotic carotid arteries. *Cerebrovasc Dis* 1991;1:265-272
12. Bruckmann H, Ringelstein EB, Buchner H, Zeumer H. Percutaneous transluminal angioplasty of the vertebral artery: a therapeutic alternative to operative reconstruction of proximal vertebral artery stenoses. *J Neurol* 1986;233:336-339
13. Eckert B, Zanella FE, Thie A, Steinmetz J, Zeumer H. Angioplasty of the internal carotid artery: results, complications and follow-up in 61 cases. *Cerebrovasc Dis* 1996;6:97-105
14. O'Leary DH, Clouse ME. Percutaneous transluminal angioplasty of the cavernous carotid artery for recurrent ischemia. *AJNR Am J Neuroradiol* 1984;5:644-645
15. Purdy PD, Devous MD, Unwin DH, Giller CA, Batjer HH. Angioplasty of an atherosclerotic middle cerebral artery associated with improvement in regional cerebral blood flow. *AJNR Am J Neuroradiol* 1990;11:878-880
16. Rostomily RC, Mayberg MR, Eskridge JM, Goodkin R, Winn HR. Resolution of petrous internal carotid artery stenosis after transluminal angioplasty. *J Neurosurg* 1992;76:520-523
17. Ahuja A, Guterman LR, Hopkins LN. Angioplasty for basilar artery atherosclerosis. *J Neurosurg* 1992;77:941-944
18. Clark WM, Barnwell SL, Nesbit G, O'Neill OR, Wynn ML, Coull BM. Safety and efficacy of percutaneous transluminal angioplasty for intracranial atherosclerotic stenosis. *Stroke* 1995;26:1200-1204
19. Touho H. Percutaneous transluminal angioplasty in the treatment of atherosclerotic disease of the anterior cerebral circulation and hemodynamic evaluation. *J Neurosurg* 1995;82:953-960
20. McKenzie JD, Wallace RC, Dean BL, Flom RA, Khayata MH. Preliminary results of intracranial angioplasty for vascular stenosis caused by atherosclerosis and vasculitis. *AJNR Am J Neuroradiol* 1996;17:263-268
21. Terada T, Higashida RT, Halbach VV, et al. Transluminal angioplasty for arteriosclerotic disease of the distal vertebral and basilar arteries. *J Neurol Neurosurg Psychiatry* 1996;60:377-381
22. Yamamura A, Takamura Y, Yamaki T, Nakagawa T, Hashi K. Percutaneous transluminal angioplasty for progressing stroke caused by severe basilar artery stenosis: case report. *Neurol Surg* 1994;22:265-268
23. Fischell TA, Bausback KN, McDonald T. Evidence of altered epicardial coronary artery autoregulation as a cause of distal coronary vasoconstriction after successful percutaneous coronary angioplasty. *J Clin Invest* 1990;86:575-584
24. Barger AC, Beeuwkes R, Lainey LL, Silverman KJ. Hypothesis: vasa vasorum and neovascularization of human coronary arteries. *N Engl J Med* 1984;310:175-177
25. El-Tamimi H, Davies GJ, Hackett D, et al. Abnormal vasomotor changes early after coronary angioplasty: a quantitative arteriographic study of their time course. *Circulation* 1991;84:1198-1202
26. Castaneda-Zuniga WR, Formanek A, Tadavarthy M, et al. The mechanism of balloon angioplasty. *Radiology* 1980;135: 565-571
27. Block PC, Myler RK, Stertz S, Fallon JT. Morphology after transluminal angioplasty in human beings. *N Engl J Med* 1981; 305:382-385
28. Block PC. Mechanism of transluminal angioplasty. *Am J Cardiol* 1984;53:69C-71C
29. Lazzam C, Forster C, Gotlieb A, Dawood F, Schwartz L, Liu P. Impaired vascular reactivity following angioplasty is mainly due to endothelial injury. *Exp Mol Pathol* 1992;56:153-162
30. Mattson E, Jansen I, Edvinsson L, Bergqvist D. Endothelial influence on vessel wall induced vasospasm after balloon angioplasty. *Acta Radiol* 1993;34:156-161
31. Golino P, Buja ML, Sheng-Kun Y, McNatt J, Willerson JT. Failure of nitroglycerin and diltiazem to reduce platelet-mediated vasoconstriction in dogs with coronary artery stenosis and endothelial injury: further evidence for thromboxane A₂ and serotonin as mediators of coronary artery vasoconstriction in vivo. *J Am Coll Cardiol* 1990;15:718-726
32. Schwartz L, Bourassa MG, Lesperance J, et al. Aspirin and dipyridamole in the prevention of restenosis after percutaneous transluminal coronary angioplasty. *N Engl J Med* 1988;318:1714-1719
33. Lembo NJ, Black AJR, Roubin GS, et al. Effect of pretreatment with aspirin versus aspirin plus dipyridamole on frequency and type of acute complications of percutaneous transluminal coronary angioplasty. *Am J Cardiol* 1990;65:422-426
34. Wilentz JR, Sanborn TA, Haudenschild CC, Valeri CR, Ryan TJ, Faxon DP. Platelet accumulation in experimental angioplasty: time course and relation to vascular injury. *Circulation* 1987;75: 636-642
35. Hovsepian DM. Post-angioplasty elastic recoil. In: Laberge JM, Darcy MD, eds. *Peripheral Vascular Interventions Syllabus*. Fairfax, Va: Society of Cardiovascular and Interventional Radiologists; 1994: 244
36. Ferguson RDG, Ferguson JG, Lee LI. Endovascular revascularization therapy in cerebral athero-occlusive disease: angioplasty and stents, systemic and local thrombolysis. *Neurosurg Clin N Am* 1994;5:511-527
37. Cowley MJ, Dorros G, Kelsey SF, van Raden M, Detre KM. Acute coronary events associated with percutaneous transluminal coronary angioplasty. *Am J Cardiol* 1984;53:12C-16C
38. DeMonte F, Peerless SJ, Rankin RN. Carotid transluminal angioplasty with evidence of distal embolization. *J Neurosurg* 1989;70: 138-141
39. Theron J, Courtheoux P, Alachkar F, Bouvard G, Maiza D. New triple coaxial catheter system for carotid angioplasty with cerebral protection. *AJNR Am J Neuroradiol* 1990;11:869-874
40. Markus HS, Clifton A, Buckenham T, Brown MM. Carotid angioplasty: detection of embolic signals during and after the procedure. *Stroke* 1994;25:2403-2406
41. Ferguson R. Getting it right the first time. *AJNR Am J Neuroradiol* 1990;11:875-877