



## Discover Generics

Cost-Effective CT & MRI Contrast Agents



WATCH VIDEO

# AJNR

### CT-guided brachial plexus biopsy.

J W Cole, D J Quint, J E McGillicuddy and K P Murphy

*AJNR Am J Neuroradiol* 1997, 18 (8) 1420-1422

<http://www.ajnr.org/content/18/8/1420>

This information is current as  
of June 5, 2025.

---

# CT-Guided Brachial Plexus Biopsy

James W. Cole, Douglas J. Quint, John E. McGillicuddy, and Kieran P. Murphy

**Summary:** We describe a technique for conducting a CT-guided biopsy of the brachial plexus region, report two illustrative cases, discuss potential complications, and conclude that, in selected cases, biopsy of lesions in the region of the brachial plexus can be performed safely with CT guidance.

**Index terms:** Biopsies, computed tomography guidance; Brachial plexus

Patients with unilateral brachial plexopathy occasionally require biopsy for prognostic and treatment planning reasons. This is especially true for patients with a history of breast cancer previously treated with radiation, in whom the main differential diagnosis is neoplastic nodal recurrence versus radiation fibrosis. At our institution, until recently, biopsies in this area have been performed by neurosurgeons using an open surgical approach. In the past year, we have safely performed biopsies of brachial plexus lesions in three patients with isolated brachial plexopathy by using CT guidance. In each case, on-site cytologic evaluation was diagnostic, revealing neoplastic tissue. We describe our technique for CT-guided biopsy of brachial plexus lesions.

## Technique

Patients with known neoplasms, who present with new unilateral brachial plexopathy are first studied with magnetic resonance (MR) imaging (Fig 1). If abnormal soft tissue is identified that could be the cause of the patient's brachial plexopathy, computed tomographic (CT)-guided biopsy is planned.

For biopsy planning, a high-resolution (3 mm or less) contrast-enhanced axial CT scan is obtained *during* intravenous administration of contrast material from the C-5 vertebral level through the inferior axillary level. Contrast administration is timed to maximize vascular enhancement, as the subclavian vessels are valuable landmarks by which to locate the brachial plexus (Fig 2A). The field of

view must be large enough to include the anterior and lateral skin surfaces (with radiopaque markers affixed) and be centered over the side of interest.

The pathologic tissue farthest removed from regional neurovascular structures is targeted, and the skin is anesthetized with 2% lidocaine (with or without epinephrine). Importantly, we avoid deep administration of local anesthetic because it is desirable to have the patient able to comment on the type of pain being felt during the procedure to minimize the chance of damaging brachial plexus neural structures, and because local anesthetic can dissect along the perineural space, enter the spinal epidural or subarachnoid spaces, and cause high epidural (1) or spinal (2) anesthesia. Because of the proximity to the spinal canal, inadvertent spinal or epidural anesthesia is more likely with procedures performed in the interscalene region than elsewhere along the plexus.

For our biopsies, we use a coaxial technique with either a 6-inch 20-gauge or an 8-inch 22-gauge calibrated spinal style needle (MSPN #2006 or MSPN #2208, respectively; Manan Medical Products, Northbrook, Ill) inserted through a 4-inch 18-gauge calibrated spinal style needle (MSPN #1804, Manan Medical Products). The shortest anterior or anterolateral approach is taken to the pathologic tissue. Care is taken to avoid neurovascular structures, especially the subclavian and carotid arteries. Placement of the 18-gauge needle is monitored with CT until it is positioned within 1 to 2 cm of the area of interest. With the 18-gauge needle positioned near the lesion, multiple passes into the pathologic tissue can be made in relative safety with the 22-gauge needle. If paresthesias are experienced by the patient, the needle(s) must be repositioned. In the absence of paresthesia, aspiration of cells for cytologic examination can be performed. We do not advocate the use of cutting needles, given the increased risk to regional nerves and the fact that cytologic analysis should be adequate to distinguish between neoplasm and other entities in the majority of cases. At our institution, we routinely have a cytopathologist in the CT area who can notify us when a diagnostic quantity of tissue has been obtained. Part of each sample is smeared onto slides and stained for immediate microscopic examination by the cytopathologist, while the remainder is rinsed into a solution for cell block

---

Received July 10, 1996; accepted after revision November 18.

From the Departments of Radiology (J.W.C., D.J.Q., K.P.M.) and Surgery (J.E.M.), University of Michigan Hospitals, Ann Arbor.

Address reprint requests to Douglas J. Quint, MD, B1D520B, Neuroradiology/MRI, University of Michigan Hospitals, 1500 E Medical Center Dr, Ann Arbor, MI 48109.

AJNR 18:1420-1422, Sep 1997 0195-6108/97/1808-1420 © American Society of Neuroradiology

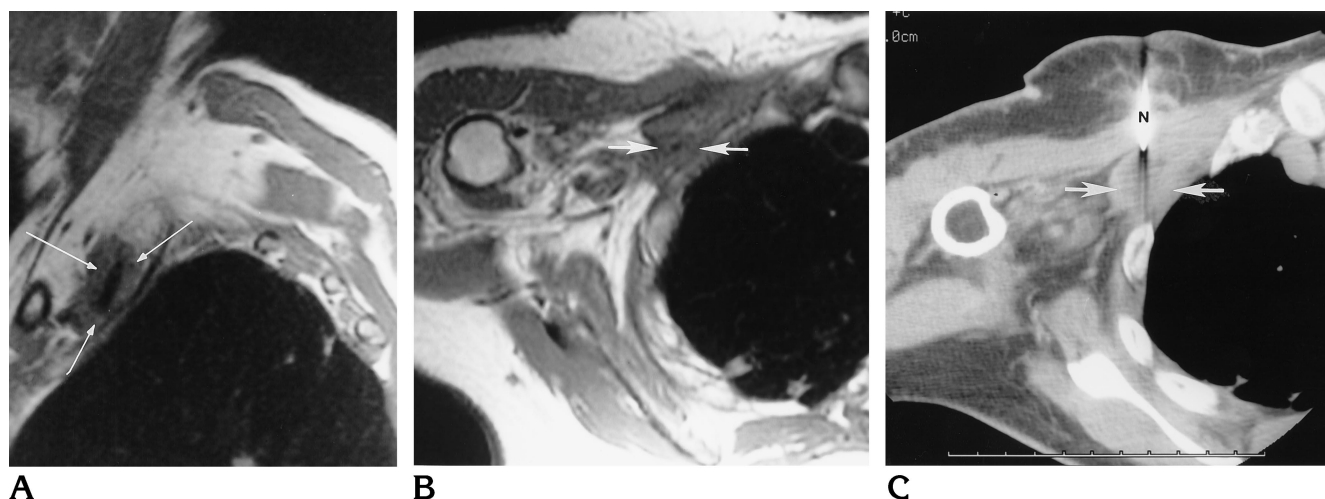


Fig 1. Metastatic squamous cell carcinoma.

A and B, Sagittal (A) and axial (B) T1-weighted MR images (700/16/2 [repetition time/echo time/excitations]) of the right brachial plexus show abnormal tissue (arrows) surrounding the neurovascular structures.

C, Axial CT scan shows the biopsy needle (N) within the lesion (arrows).

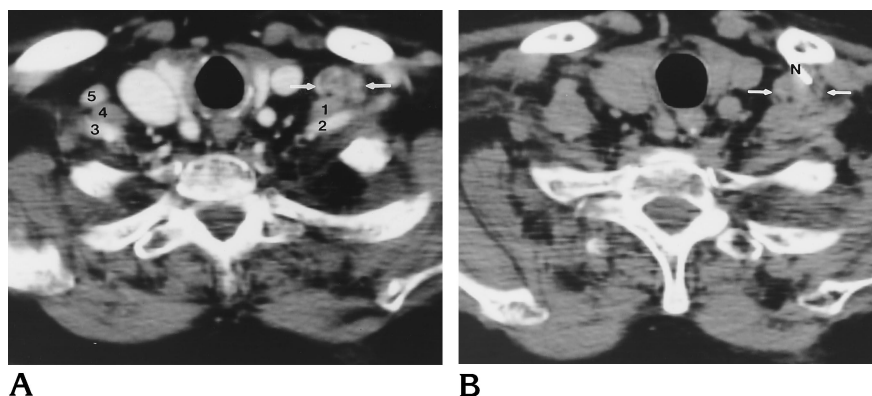


Fig 2. Metastatic adenocarcinoma.

A, Axial CT scan during infusion of iodinated intravenous contrast material shows abnormal soft tissue (arrows) anterior to the left anterior scalene muscle (1) and the left subclavian artery (2). The left subclavian vein is compressed by the abnormal soft tissue. Note normal right subclavian artery (3), right anterior scalene muscle (4), and right subclavian vein (5).

B, Axial contrast-enhanced CT scan at the same level as A 5 minutes after intravenous contrast administration. Note the difficulty in differentiating previously well-delineated structures. Percutaneously placed needle (N) is seen within the lesion (arrows).

preparation (preferences for slide preparation and cell block preparation vary with the cytopathologist). Care must be taken to avoid clotting of blood and drying of the specimen before its delivery to the cytopathologist. At the conclusion of the procedure, all needles are removed. In the event of inadvertent arterial puncture, hemostasis can be obtained by using direct digital pressure and/or a pressure dressing, as needed.

## Representative Cases

The first patient (Fig 1) had had a radical mastectomy 7 years earlier for carcinoma, and presented with a 4-month history of progressive right upper extremity pain and weakness to the point where she could no longer use her right arm. MR images showed abnormal soft tissue surrounding the inferior portion of the right brachial plexus (Fig 1A and B). Bolus thin-section CT scans confirmed focal abnormal soft tissue that was intimately associated

with the subclavian vessels and the lower trunk and medial cord of the right brachial plexus. CT-guided coaxial placement of a 22-gauge needle into the lesion (Fig 1C) with aspiration of poorly differentiated squamous cell carcinoma was performed without complication.

The second patient (Fig 2) had had radical left-sided mastectomy and radiation therapy in 1977 for breast adenocarcinoma. Additional radiation therapy was given for left-sided supraclavicular nodal recurrence in 1992. She experienced progressive weakness, paresthesias, and pain in the left upper extremity over the subsequent 3 years. Positron emission tomography with fludeoxyglucose F 18 revealed abnormally increased uptake in the inferior left brachial plexus region. MR imaging showed abnormal brachial plexus soft tissue. Bolus thin-section CT (Fig 2A) confirmed a  $1 \times 1 \times 1$ -cm lesion near the inferior trunk of the left brachial plexus. CT-guided coaxial placement of a 22-gauge needle into this lesion (Fig 2B) with aspiration of adenocarcinoma was performed without complication.

## Discussion

The location of the brachial plexus is predictable by understanding its relationship to a few key structures. Knowledge of these relationships is essential for the identification of pathologic soft tissue, neoplastic or otherwise, that can cause brachial plexopathy. Similarly, knowledge of the anatomy of the brachial plexus can enable one to perform biopsies of lesions in this area with relative safety. Excellent reviews of brachial plexus anatomy are available in the literature (3). Briefly, neural contributors to the brachial plexus arise from the anterior nerve roots of C-4 to T-2, inclusively. These nerve roots exit their respective neural foramina to course between the bellies of the anterior and middle scalene muscles. The anterior scalene muscle is most easily identified as the muscle passing between the subclavian vein (anterior) and artery (posterior) within the thoracic inlet (Fig 2A). Lateral to the scalene muscles, the elements of the brachial plexus are located just posterior and superior to the subclavian artery. The subclavian artery and brachial plexus elements enter the axilla between the first rib and the clavicle. In the axilla, brachial plexus elements surround the axillary artery, tending to cluster posterior to it.

Any tissue between the spinal column and the anterior scalene muscle, as well as any tissue within 2 cm of the anterior scalene muscle or the subclavian/axillary artery, should be considered at risk for harboring elements of the brachial plexus. The approach to any lesion thought to be responsible for causing brachial plexopathy must be carefully analyzed with respect to the above described anatomy in order to, on a case-by-case basis, select the safest route for needle placement. In each of our cases, we have been able to identify tissue sufficiently remote from the expected location of brachial plexus elements to allow for low-risk biopsy.

We have successfully, and without complications, performed biopsies in three patients at our institution by using the technique outlined above. We have not, however, had enough experience to establish meaningful complication rates for what we believe should be a low-morbidity procedure.

Anesthesiologists have extensive experience with needle placements in the brachial plexus region for the purpose of performing upper ex-

trinity anesthesia. Despite the fact that such needles are placed "blindly," the overall complication rate is low. Davis et al (4) from the Mayo Clinic reported no persistent neurologic deficit in over 500 brachial plexus blocks in which 97% were performed via an axillary approach. Local complications, such as regional hematoma formation and pneumothorax, are occasionally encountered with the relative frequency of these complications depending on the approach used (5). Reported rare and serious complications include transient high spinal and epidural anesthesia from dissection of anesthetic proximally along the perineural space to the spinal epidural (1) or subarachnoid (2) spaces, permanent motor weakness of plexus nerve roots (6), and development of reflex sympathetic dystrophy (7).

## Conclusion

Biopsy of mass lesions causing brachial plexopathy is occasionally necessary. CT-guided biopsy should be considered as an alternative to more expensive and invasive open surgical biopsy. The above-outlined technique is recommended, and should be safe in the majority of clinically encountered cases, particularly when pathologic tissue separate from neurovascular structures can be identified. While serious complications, including permanent injury to regional nerves, are possible, the use of CT guidance should, in the majority of cases, provide safety and accuracy equivalent to or greater than that achievable with open biopsy.

## References

1. Kumar A, Battit G, Froese A, Long M. Bilateral cervical and thoracic epidural blockade complicating interscalene brachial plexus block: report of two cases. *Anesthesiology* 1971;35:650-652
2. Ross S, Scarborough C. Total spinal anesthesia following brachial plexus block. *Anesthesiology* 1973;39:458
3. Reede D. Brachial plexus. In: Som P, Curtin H, eds. *Head and Neck Imaging*. St Louis, Mo: Mosby-Year Book; 1996;2:976-991
4. Davis W, Lennon R, Wedel D. Brachial plexus anesthesia for outpatient surgical procedures on an upper extremity. *Mayo Clin Proc* 1991;66:470-473
5. Murphy T. Complications of diagnostic and therapeutic nerve blocks. In: Gravenstein N, Kirby R, eds. *Complications in Anesthesiology*. Philadelphia, Pa: Lippincott-Raven; 1996;1:585-596
6. Barutell C, Vidal F, Raich M, Montero A. A neurological complication following interscalene brachial plexus block. *Anaesthesia* 1980;35:365-367
7. Gillespie J, Menk E, Middaugh R. Reflex sympathetic dystrophy: a complication of interscalene block. *Anesth Analg* 1987;66:1316-1317