



Discover Generics

Cost-Effective CT & MRI Contrast Agents



WATCH VIDEO

AJNR

Aneurysm clips made of titanium: magnetic characteristics and artifacts in MR.

W Wichmann, K Von Ammon, U Fink, T Weik and G M Yasargil

AJNR Am J Neuroradiol 1997, 18 (5) 939-944

<http://www.ajnr.org/content/18/5/939>

This information is current as
of June 23, 2025.

Aneurysm Clips Made of Titanium: Magnetic Characteristics and Artifacts in MR

Werner Wichmann, Klaus Von Ammon, Ulrich Fink, Thomas Weik, and Gazi M. Yaşargil

PURPOSE: To evaluate the magnetic characteristics, artifact formation, and implant safety of titanium aneurysm clips for use in MR imaging. **METHODS:** Aneurysm clips made of titanium alloy TiAl6V4 were tested in a magnetometer to determine their magnetic susceptibility and in a 1.5-T MR imager using both a geometric phantom and an animal model. A commercially available α -Phynox clip served as the reference standard. **RESULTS:** We found minimal magnetization and a significant reduction in image artifacts with the titanium clip as compared with the Phynox clip. **CONCLUSION:** The titanium clips improve image quality, biocompatibility, and patient safety in medical MR applications.

Index terms: Aneurysm, therapeutic blockade; Interventional instruments, clamps

AJNR Am J Neuroradiol 18:939–944, May 1997

Neurosurgical treatment of intracranial aneurysms by permanent closure with “spring clips” placed over the neck of the aneurysm was introduced more than 20 years ago and has since become a standard procedure (1–3). The spring aneurysm clip is a refinement of the ductile silver clip introduced by Cushing in 1910, making it technically possible to close blood vessels located in difficult-to-reach intracranial regions (4). Construction requirements of the spring clips include such mechanical characteristics as strength, elasticity, resistance to corrosion, and biological compatibility (5).

With the introduction of magnetic resonance (MR) imaging in the neurologic and neurosurgical examination of patients, magnetic compatibility has become another essential requirement (6, 7). At first, theoretical considerations resulted in a general hesitation to use MR imag-

ers operating at 0.5 to 1.5 T for the examination of patients in whom metallic aneurysm clips had been implanted (8). Indeed, a fatal outcome stemming from torque and displacement of a ferromagnetic clip in an MR imager has been reported (9).

However, metallurgical and physical testing of commercially available clips has proved the MR compatibility of clips manufactured from nonferromagnetic materials. Clinical use of MR imaging has demonstrated that the theoretical possibility of clip warming is negligible (10). Thus, it is possible to use MR imaging to examine patients with nonferromagnetic aneurysm clips without risk (8, 10–13). These investigations, however, disclosed considerable imaging artifacts surrounding the clips, which conceal contrast in their vicinity (11, 13–16). Therefore, it is necessary to find materials that produce minimal artifacts on MR images while still ensuring the aforementioned mechanical characteristics and biocompatibility.

It is known that a reduction in MR artifacts can be achieved by using titanium alloys (17–19). Our study investigated the magnetic characteristics and MR behavior of a Yaşargil titanium clip (TiAl6V4). Our purpose was to determine the extent of MR artifacts as well as MR compatibility and implant safety of these clips.

Received May 23, 1996; accepted after revision December 12.

From the Institute of Neuroradiology (W.W.) and the Department of Neurosurgery (K.V.A., G.M.Y.), University Hospital, Zürich, Switzerland; and Aesculap AG, Tuttlingen, Germany (U.F., T.W.).

Address reprint requests to Werner Wichmann, MD, Institute of Neuroradiology, University Hospital of Zürich, Frauenklinikstrasse 10, Nord I, C-200, CH-8091 Zürich, Switzerland.

AJNR 18:939–944, May 1997 0195-6108/97/1805-0939

© American Society of Neuroradiology

Fig 1. Photograph (A) and corresponding MR proton density-weighted image (2000/20/4) (B) of the phantom in which two identical α clips are placed 7.5 cm apart on a nylon thread (z-axis is parallel and frequency-encoding gradient is vertical to the section). The Co-based Phynox clip is labeled 1 and the titanium clip 2. A considerable reduction in artifacts is clearly visible around the titanium clip. (Incomplete imaging of the grid on the left side of the MR image is caused by slight tilting of the imaging plane.)

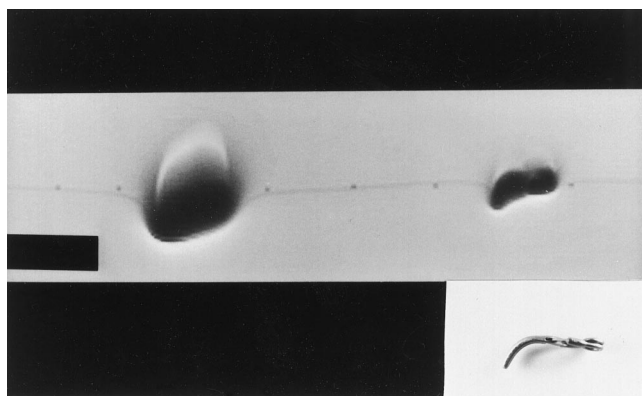
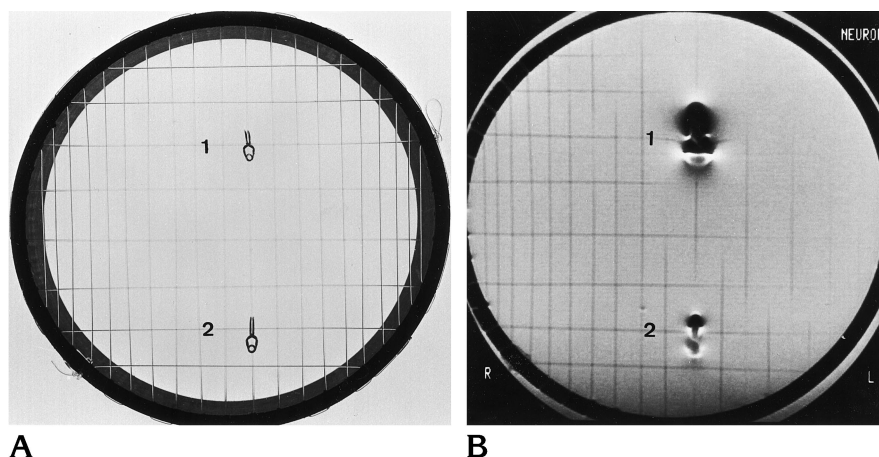


Fig 2. MR longitudinal view (clip orientation same as in the inset photo; proton density-weighted image 2000/20/4; z-axis is horizontal and frequency-encoding gradient is vertical to the section); the artifact on left is located next to the Phynox clip, the one on right is next to the titanium clip.

Materials and Methods

A generation of clips made of the titanium alloy TiAl6V4 has been invented. The basis for the design of the clips was the model FE Aesculap Yaşargil, with slightly bent blades belonging to the so-called α class (Figs 1A, 2, and 3A), which has been used successfully for years. This implant was manufactured with an alloy called *Phynox*, specified in the International Organization for Standardization (ISO) ISO 5832-7 for implant applications and composed of the following constituents: cobalt (Co) (40%), chrome (20%), nickel (16%), molybdenum (7%), and iron. The Co-based *Phynox*, known for its good spring characteristics, has outstanding mechanical advantages, which has made *Phynox* the material of choice for several clip manufacturers.

The new clip, which is identical to the Yaşargil *Phynox* in design, is made of TiAl6V4, which is specified ISO 5832-3. It is composed primarily of titanium (Ti) and also contains aluminum (Al; 6%) and vanadium (V; 4%). Unquestionably, this material is superior in its biocompatibility and hypoallergenicity as compared with the above-mentioned Co-based *Phynox* (20).

Both materials are nonferromagnetic alloys, so the basic requirement for MR compatibility is met. However, in principle, any material, even nonferromagnetic, may become polarized in an external magnetic field. The less the material in question is polarized, the fewer artifacts are seen on MR images. To determine the so-called susceptibility, the magnetic polarization of the materials under investigation were measured at the Institute of Physics at the University of Karlsruhe, Germany. Magnetic polarization was measured as a function of the external magnetic field on a SQUID (superconducting quantum interference device) magnetometer up to a field strength of 2.5 T. This method is sensitive and reliable for measuring the magnetic behavior of solid bodies. The SQUID was calibrated beforehand using standards provided by the US National Bureau of Standards.

After determining basic physical variables, clips that were identical in design but made of the two different materials were examined in a conventional 1.5-T clinical MR imager. Unlike the purely physical values measured, the results of these in vitro tests were specific to the MR equipment used (Philips S-15; 1.5 T).

The in vitro examination used a phantom composed of a plastic ring strung with nylon threads crossing at right angles, much like the strings of a tennis racket, in a 6.5-L water bath. The two clips made of different materials were placed in the phantom longitudinally 7.5 cm apart (Figs 1A and B and 2). The clips were oriented parallel to the main axis (z-axis) of the MR unit and examined in three planes using spin-echo T1- and T2-weighted sequences. Imaging parameters were 600/23/8 (repetition time/echo time/excitations) and 2000/20,90/4, respectively; section thickness at full width at half maximum of 4 mm and 5 mm, respectively, matrix size of 256×256 , and field of view of 16 cm.

In vivo MR studies were performed only with the titanium clip, in a 1.5-T magnet (Signa, General Electric, Milwaukee, Wis). A lateral aneurysm measuring approximately 4 mm in diameter was created, using a vein patch on the right common carotid artery of a 250-g rat (breed, SIV; Zurich Veterinary Hospital) using a previously re-

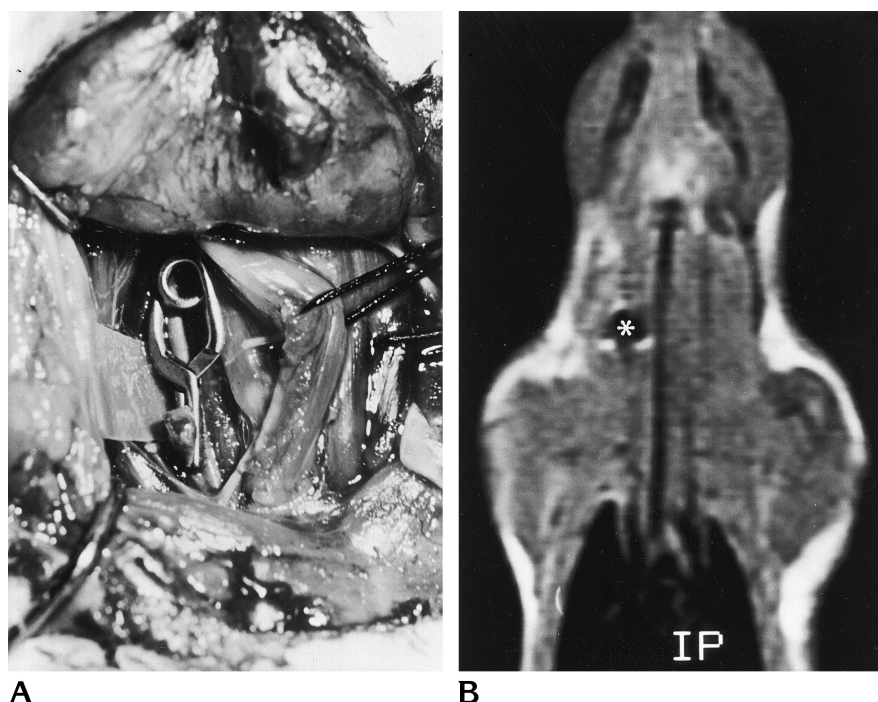

Fig 3. Intraoperative photograph (A) and corresponding coronal T1-weighted spin-echo MR image (600/15/4) (B) show site of the titanium clip implanted in a rat. The MR artifact (*asterisk*) can only be discerned around the spring, because the blades extend out of the thin section, owing to their curvature. (The esophagus, which contains air, appears in the middle as a wide, hypointense band.)

ported technique (21). Eight hours after preparation, the aneurysm was clipped at the neck using the titanium clip (see Fig 3A). Fourteen days later, an MR examination was performed with the animal under anesthesia (intramuscular neuroleptanesthesia, according to the Swiss Act on Prevention of Cruelty to Animals). Coronal spin-echo T1-weighted (600/15/4, section thickness at full width at half maximum of 3 mm, matrix of 256×192 , field of view of 16 cm) (Fig 3B) and coronal fast spin-echo T2-weighted (3500/23,115/4, echo train length of 8, section thickness at full width at half maximum of 3 mm, matrix of 256×192 , field of view of 12 cm) images were obtained.

Results

The two clips belonging to the α class (model FE Aesculap Yaşargil with slightly bent blades) had dimensions of 15×5 mm, with a wire thickness of 1.2 mm. Design and dimensions of the two clips were identical. The Phynox clip weighed 126.5×10^{-3} g and the one made from titanium alloy weighed 74.6×10^{-3} g.

Using the SQUID magnetometer, we determined the magnetic susceptibilities (χ) as $\chi = 14.6 \times 10^{-6}$ for the titanium alloy and $\chi = 181 \times 10^{-6}$ for the Co-based alloy (Phynox). The susceptibilities are stated according to the CGS (centimeter-gram-second) system. This physical quantity has no unit.

The in vitro MR investigation revealed that the clip composed of TiAl6V4 caused considerably

fewer artifacts in terms of signal alteration and image distortion (Figs 1B and 2). On the T2-weighted sequences, the ellipsoid artifact concealing the surrounding area measured 15×9 mm for the Phynox clip, diminishing to 10×5 mm for the titanium clip.

T1-weighted MR images are, in general, not as greatly impaired by susceptibility artifacts as are T2-weighted images (24, 26). Comparing the two clips in the phantom, we observed that on the T1-weighted images, considerably fewer artifacts were present with the titanium clip than with the Co-based clip. Also, on the T1-weighted MR image of the rat, only a small artifact, measuring approximately 7 mm in diameter, was detected around the titanium clip (Fig 3B).

Discussion

The new titanium alloy clip was compared with a geometrically identical clip made of Phynox. The reason that the comparison was made with this type of clip was that the Phynox clips and the nearly identical Elgiloy alloy clips together account for roughly 75% of all intracranial aneurysms clips implanted today in the United States.

In manufacturing clips suitable for permanent closure of intracranial aneurysms, clip design

and choice of material are equally important (5). Suitable alloys must ensure permanent closure, be resistant to corrosion, pose no biological risk, and be compatible with MR imaging (8, 12, 13). MR imaging has established itself as the most important diagnostic tool for neurosurgical and neurologic diseases (6, 7, 22). The demand for MR-compatible implants has increased accordingly.

MR compatibility means that a patient is not at risk as a result of the clip's shifting or slipping during MR imaging. It is important to take such shifting and slippage into account when using clips made of ferromagnetic alloys, as considerable mechanical forces are generated on these materials (9). In the case of ferromagnetic clips, even the proximity of an MR imager, regardless of the strength of the magnetic field, is a life-threatening situation for the patient (23). A death has recently been reported during MR imaging of a patient with a ferromagnetic aneurysm clip (9).

The physical difference between ferromagnetic and nonferromagnetic materials lies in the degree of magnetization. In the case of ferromagnetic materials, there is a sharp rise in magnetization even when they are exposed to a weak external magnetic field. Magnetization increases only slightly when the materials are exposed to a more powerful external magnetic field. With nonferromagnetic materials, there is only a slight increase in magnetization from low to high magnetic fields. Magnetization of ferromagnetic materials exposed to an external magnetic field of approximately 1.5 T is about 1000 times greater than that of nonferromagnetic materials (24).

The degree of magnetism depends primarily on the composition of the alloy. Some stainless steel clips that are being used are ferromagnetic (5, 12). In addition, there is deformation-induced magnetism, especially in the insufficiently stable austenites. These materials show no inherent magnetic properties. When deformed at room temperature, the crystalline structure of the metal is changed and the material becomes ferromagnetic. The manufacturing processes take advantage of this deformation, for example, to improve the spring characteristics of the material (5, 14).

A class of stainless steel materials with no ferromagnetic characteristics under any circumstances are the stable austenites. This class

includes, for example, the so-called AISI 316 L alloy, which is certainly MR compatible.

It must be reemphasized that all materials become magnetized when placed in an external magnetic field. The less the magnetization, the weaker the forces exerted on an aneurysm clip during MR imaging. This magnetization is stated in terms of magnetic susceptibility. Measurement of this physical unit has shown that the susceptibility of the titanium alloy is only one tenth that of the Co-based alloy Phynox. Thus, the forces exerted on the aneurysm clip during MR imaging are reduced to a fraction of the clip weight. Reduced magnetic susceptibility also results in a reduction of magnetism influencing MR imaging (10, 13, 16).

Two main effects cause artifacts around metal implants. First, a local field inhomogeneity is produced around the implant in the static MR field, because of the magnetic susceptibility of the metal. This local field inhomogeneity interferes with the imager gradients and leads to regional distortion of the resonance frequency (13, 26). Second, eddy currents, due to gradient switching, occur in a highly electroconductive material. These eddy currents disturb the local magnetic field homogeneity surrounding the implant, resulting in signal alterations, regional hypointensities, increased peripheral signals, and geometric image distortions in the immediate vicinity of the implant (13, 14, 16) (Figs 1B, 2, and 3B).

The presence of only mild artifacts seen around the once-used silver clips is due to eddy currents and not to magnetic susceptibility. Silver, which is highly electroconductive, makes the generation of eddy currents possible, but it has a low negative (diamagnetic) magnetic susceptibility, $\chi = -19.5 \times 10^{-6}$ (25), as compared with Phynox AISI 316 L and TiAl6V4. Because eddy currents play a minimal role in the production of clip-related artifacts, it can be concluded that magnetic susceptibility (χ) of the material used and its mass are the main factors determining the production of artifacts.

The magnetic characteristics of TiAl6V4 ($\chi = 14.6 \times 10^{-6}$ for titanium alloy compared with $\chi = 181 \times 10^{-6}$ for Co-based alloy) make it optimal for use in aneurysm clips. Titanium alloy has been shown to be highly biocompatible for more than 20 years, as demonstrated by the large number of orthopedic patients with permanent implants made of this material.

Good mechanical characteristics are impor-

tant prerequisites for spring aneurysm clips, which is why silver is not currently used. Titanium, which is relatively weak, is considered an unfavorable material for springs; but extensive developmental work has resulted in a clip in which the closing force is only slightly compromised in favor of better magnetic characteristics. In most clip models, the titanium alloy TiAl6V4 has the same closing force as the ones made of the Co-based alloy Phynox.

In MR investigations with a water phantom, we detected a considerable reduction in artifacts with the titanium clip as compared with the Co-based Phynox clip. The artifacts found with the titanium clip implanted in the laboratory animal, as compared with the phantom measurements, can be explained by the bent blades of the clip, which stuck out of the 3-mm section. Other factors contributing to diminished artifacts include the use of steeper readout gradients (which depend on the short prescribed echo time), thin sections, and a small field of view. Steeper readout gradients result in less spatial frequency spread of the susceptibility-induced resonant frequency distortion (26). However, the chosen section thickness of 3 mm and the fields of view of 12 cm and 16 cm in the in vivo studies were somewhat smaller than would be typically applied in two-dimensional Fourier transform (2DFT) brain imaging of humans. The loss of signal due to susceptibility effects is less when the size/volume of the voxels is decreased because of decreased intra-voxel dephasing. Thus, in imaging patients with such clips, the size of the artifact for comparable sequences (but with typically larger voxels) would be larger than the one encountered in our animal model.

The neuroradiologist should be aware of the MR compatibility of implanted aneurysm clips. The first three generations of Yaşargil clips, labeled *FD*, are now thought to be incompatible with MR imaging. The α -Phynox type, labeled *FE*, is a fourth-generation clip and the only one besides the new titanium type considered to be MR compatible (23). The neuroradiologist should not rely on verbal assurance from the neurosurgeon that the clip used is MR compatible but should require a written confirmation of the specific type of Yaşargil clip used in the operation (9).

The risk of interaction of aneurysm clips with strong magnetic fields can be reduced by using the material TiAl6V4. This alloy has less mag-

netic susceptibility, diminished MR artifacts, and better biocompatibility than the previously used material. However, it is still impossible to obtain exact anatomic information about the vessels in the immediate vicinity of a clip by means of MR imaging or MR angiography (27). Thus, the challenge remains to find yet more suitable materials for aneurysm clips that even better fulfil mechanical, biological, and magnetic requirements.

Acknowledgment

We thank Rosmarie Frick of the Microsurgical Laboratory for her valuable assistance with animal preparation.

References

1. Mayfield FH, Kees G Jr. A brief history of the development of the Mayfield clip: technical note. *J Neurosurg* 1971;35:97-100
2. Scoville WB. Miniature torsion bar spring aneurysm clip. *J Neurosurg* 1966;25:97
3. Yaşargil MG. *Microsurgery Applied to Neurosurgery*. Stuttgart, Germany: Georg Thieme; 1969:126-130
4. Cushing H. The control of bleeding in operations for brain tumors: with the description of silver "clips" for the occlusion of vessels inaccessible to ligature. *Ann Surg* 1911;54:1-19
5. Mc Fadden JT. Metallurgical principles in neurosurgery. *J Neurosurg* 1969;31:373-385
6. Bydder GM, Steiner RE, Young IR, et al. Clinical NMR imaging of the brain: 140 cases. *AJR Am J Roentgenol* 1982;139:215-236
7. Crooks LE, Ortendahl DA, Kaufman L, et al. Clinical efficiency of nuclear magnetic resonance imaging. *Radiology* 1983;146:123-128
8. Kanal E, Shellock FG, Talagala L. Safety considerations in MR imaging. *Radiology* 1990;176:593-606
9. Klucznik RP, Carrier DA, Pyka R, Haid RW. Placement of a ferromagnetic intracerebral aneurysm clip in a magnetic field with a fatal outcome. *Radiology* 1993;187:855-856
10. Davis PL, Crooks L, Arakawa M, McRee R, Kaufman L, Margulis AR. Potential hazards in NMR imaging: heating effects of changing magnetic fields and RF fields on small metallic implants. *AJR Am J Roentgenol* 1981;137:857-860
11. Becker RL, Norfray JF, Teitelbaum GP, et al. MR imaging in patients with intracranial aneurysm clips. *AJNR Am J Neuroradiol* 1988;9:885-889
12. Dujovny MD, Kossovsky N, Kossovsky R, et al. Aneurysm clip motion during magnetic resonance imaging: in vivo experimental study with metallurgical factor analysis. *Neurosurgery* 1985;17:543-548
13. Romner B, Olsson M, Ljunggren B, et al. Magnetic resonance imaging and aneurysm clips: magnetic properties and image artifacts. *J Neurosurg* 1989;70:426-431
14. Fache JS, Price C, Hawbolt EB, Li DK. MR imaging artifacts produced by dental materials. *AJNR Am J Neuroradiol* 1987;8:837-840
15. New PF, Rosen BR, Brady TJ, et al. Potential hazards and artifacts of ferromagnetic and nonferromagnetic surgical and dental materials and devices in nuclear magnetic resonance imaging. *Radiology* 1983;147:139-148
16. Teitelbaum GP, Bradley WG Jr, Klein BD. MR imaging artifacts,

- ferromagnetism, and magnetic torque of intravascular filters, stents, and coils. *Radiology* 1988;166:657-664
17. Clayman DA, Murakami ME, Vines FS. Compatibility of cervical spine braces with MR imaging: a study of nine non-ferrous devices. *AJNR Am J Neuroradiol* 1990;11:385-390
18. Mirvis SE, Geisler F, Joslyn JN, Zrebeet H. Use of titanium wire in cervical spine fixation as a means to reduce MR artifacts. *AJNR Am J Neuroradiol* 1988;9:1229-1231
19. Teitelbaum GP, Ortega HV, Vinitski S, et al. Low-artifact intravascular devices: MR imaging evaluation. *Radiology* 1988;168:713-719
20. Steinemann, S. Metallurgie der Knochen- und Gelenkimplantate. *Langenbecks Arch Chir* 1979;349:307
21. Young PH, Fischer VW, Guity A, Young PA. Mural repair following obliteration of aneurysms: production of experimental aneurysms. *Microsurgery* 1987;8:128-137
22. Crooks LE, Mills CM, Davis PL, et al. Visualisation of cerebral and vascular abnormalities by NMR imaging: the effects of imaging parameters on contrast. *Radiology* 1982;144:843-852
23. Kanal E, Shellock FG. MR imaging of patients with intracranial aneurysm clips. *Radiology* 1993;187:612-614
24. Saini S, Frankel RB, Stark DD, Ferrucci JT Jr. Magnetism: a primer and review. *AJNR Am J Neuroradiol* 1988;150:735-743
25. Weast RC, Astle MJ, eds. *CRC Handbook of Chemistry and Physics. Section E: General Physical Constants*. 59th ed. Boca Raton, Fla: CRC Press; 1978-1979:E-125
26. Lüdeke KM, Röschmann P, Tischler R. Susceptibility artifacts in NMR imaging. *Magn Reson Imaging* 1985;3:329-343
27. Ross JS, Masaryk TJ, Modic MT, Ruggieri PM, Haacke EM, Selman WR. Intracranial aneurysms: evaluation by MR angiography. *AJNR Am J Neuroradiol* 1990;11:449-455