



Discover Generics

Cost-Effective CT & MRI Contrast Agents



WATCH VIDEO

AJNR

Carotid artery stenosis: optimization of CT angiography with a combination of shaded surface display and source images.

Z Papp, M Patel, M Ashtari, M Takahashi, J Goldstein, W Maguire and P G Herman

This information is current as of June 5, 2025.

AJNR Am J Neuroradiol 1997, 18 (4) 759-763
<http://www.ajnr.org/content/18/4/759>

Carotid Artery Stenosis: Optimization of CT Angiography with a Combination of Shaded Surface Display and Source Images

Zsuzsanna Papp, Mahendra Patel, Manzar Ashtari, Masashi Takahashi, Jacques Goldstein, William Maguire, and Peter G. Herman

PURPOSE: To evaluate the accuracy of CT angiography of occlusive disease of the carotid arteries using three-dimensional surface-rendered images alone and in conjunction with display of axial source images. **METHODS:** Forty-eight symptomatic patients had conventional angiography followed by CT angiography within 24 hours. Images of 96 carotid arteries were acquired using contrast-enhanced spiral CT. Image postprocessing was performed on a free-standing workstation to produce 3-D shaded surface display (SSD) images. Two readers independently evaluated the CT angiographic (SSD) images and then reevaluated each case while simultaneously reviewing the SSD and axial source images. Digital subtraction angiograms were evaluated in a separate session and eventually compared with CT angiograms. All evaluations were performed under blinded conditions to control for reader bias. **RESULTS** SSD images alone underestimated stenosis relative to angiograms whereas combined SSD and axial images did not. **CONCLUSION:** SSD angiograms in conjunction with the source images are better than SSD images alone in estimating the degree of stenosis in carotid artery disease.

Index terms: Arteries, stenosis and occlusion; Computed tomography, three-dimensional

AJNR Am J Neuroradiol 18:759–763, April 1997

Recently, computed tomographic (CT) angiography has shown promise in the evaluation of carotid artery disease. The advent of helical CT provides uninterrupted imaging volume acquisition and data collection from the region of interest in less than a minute (1, 2). In addition, vascular structures are well seen when the appropriate delay after intravenous injection of contrast material is chosen (3). Postprocessing with volume-rendering techniques can be done by using a maximum-intensity-projection algorithm similar to the one used for magnetic resonance (MR) angiography. Alternatively, surface-rendering methods are also used to create three-dimensional images of the vessels (5). In addition, CT angiography can help distinguish

calcified, high-density atherosclerotic plaques from the contrast-filled lumen.

Several studies have compared CT angiography with various imaging techniques in the evaluation of carotid artery disease. All these studies chose angiography as the standard of reference (6–10). The reported results of these studies vary substantially. A study published by Schwartz et al (7) showed excellent correlation between CT angiography and conventional angiography, with a 92% agreement rate. Studies by Dillon et al (8) and Cumming et al (9) each reported an agreement rate of 82%. However, in a study performed by Castillo (10), the agreement rate was as low as 50%. An assessment of interobserver agreement showing interclass correlation between observers revealed a correlation coefficient of .79 for CT angiography and .89 for digital subtraction angiography (DSA) (M. Patel, M. Takahashi, M. Ashtari, et al, "Comparison of CT Angiography and Digital Subtraction Angiography for Evaluation of Carotid Artery Disease," presented at the annual meeting of the American Society of Neuroradiology, Chicago, Ill, April 1995). Methodological

Received May 28, 1996; accepted after revision November 5.

Presented at the annual meeting of the American Society of Neuroradiology, Chicago, Ill, April 1995.

From the Department of Radiology, Long Island Campus for the Albert Einstein College of Medicine, 270-05 76th Ave, New Hyde Park, NY 11040. Address reprint requests to Mahendra Patel, MD.

AJNR 18:759–763, Apr 1997 0195-6108/97/1804-0759

© American Society of Neuroradiology

differences reported in the above studies may be the cause of inconsistencies in results. These discrepancies prompted the initiation of the present study in order to obtain more consistent results with shaded surface display (SSD) angiograms.

SSD images present a visually compelling representation of the vessels and a familiar visual analog to DSA, but some information is lost with the reduction of axial images in this type of representation. Our study was designed to determine whether SSD images capture all the relevant information for the evaluation of carotid artery stenosis or whether a simultaneous review of axial source images would enhance the ability of radiologists to provide an accurate assessment of the degree of stenosis shown by CT angiography.

Materials and Methods

Patients

Patients referred for DSA who exhibited symptoms of carotid artery disease were considered candidates for this study. Patients with contraindications to a second contrast examination (elevated serum creatinine level, congestive heart failure, etc) were excluded. This study was approved by our Institutional Review Board and informed consent was obtained from all patients.

Ninety-six carotid arteries in 48 patients (28 men and 20 women; mean age, 65 years; range, 43 to 87 years) were studied. Two arteries were excluded from the study: one was in a patient who had had endarterectomy, and the metallic clip artifact rendered the images unreadable; the other was in a patient in whom the bifurcation of the carotid artery was situated below the scanning field of view.

Imaging

All angiograms were obtained with the digital subtraction method. The common carotid artery was selectively catheterized using the Seldinger technique via a transfemoral approach. A 5F catheter was used and either ionic or nonionic contrast material was injected.

The source images for CT were obtained within 24 hours after angiography. The initial localizing image was acquired in the lateral projection to landmark the carotid arteries. The patient's head was extended to prevent dental artifacts. The gantry was not tilted, and scanning was performed from C-5 up to the base of the skull. The section thickness was 3 mm with a table speed of 3 mm/s (1:1 pitch). One hundred milliliters of nonionic contrast material (30 g iodine) was used with an injection rate of 1.5 mL/s and a prescan delay of 30 seconds (3). Tube settings were 120 kVp, 250 mA. Patients were instructed to breathe

quietly without swallowing during scanning. Sections were obtained contiguously with a 17-cm field of view. These sections were subsequently reconstructed in 1 mm overlaps, resulting in a total of 67 to 112 sections per patient.

CT Angiographic Reconstruction

All studies were reconstructed by one radiologist on a free-standing workstation using 3-D SSD with thresholding. SSD is a representation of pixels with Hounsfield units (HU) in a selected threshold range. All pixels below and above these threshold values are set equal to zero.

To segment the lumen, a fixed upper threshold of 300 HU was used. The lower threshold level was determined as follows: the lowest attenuation values at the periphery of the vessel were measured; an arbitrary value of 10 HU was then subtracted from this number to allow for variability at different levels (3, 7) (this value ranged from 110 to 180 HU among patients); and fixed thresholding limits of 330/1800 HU were used to segment the calcified plaques (3, 7).

Image Analysis

Two neuroradiologists independently evaluated the CT angiograms on the workstation with interactive controls. Initial estimation of the stenosis was made using the reconstructed SSD of the carotid arteries. This display could be rotated to any angle. After the initial evaluation, a second display was presented at a separate session for reevaluation of the stenosis. This time, the rotatable SSD representation and a single source image were displayed at the top of the screen. By moving a cursor along the displayed vessel, the reader could sequentially exhibit the appropriate source images so that movement of the cursor into the stenotic region revealed the source images depicting the stenosis. A second evaluation of the stenosis was made.

Evaluations of the DSA images were performed in separate sessions by the same two neuroradiologists. The reviewers were blinded to the previous SSD findings as well as to the DSA results. DSA films were displayed on an illuminator.

Readers evaluated the degree of stenosis of the internal carotid arteries by providing an estimate of the percentage of stenosis. For analysis, these estimates were later converted to a five-point scale based on the North American Symptomatic Carotid Endarterectomy Trial (NASCET) criteria, with 0% being normal; 1% to 29%, mild stenosis; 30% to 69%, moderate stenosis; 70% to 99%, severe stenosis; and 100%, total occlusion (11).

Statistical Analysis

During the original clinical evaluation of the DSA images, an estimate of the stenosis was provided as a percentage of stenosis to the referring clinicians. These estimates were recorded before this study and were used as

Calculation of error measures for each procedure and individual observers

Judgment Error	Percentage of Stenosis	
	Average Bias	Error, SD
SSD		
Reader 1	5.09	25.28
Reader 2	5.53	25.14
2-D axial images		
Reader 1	2.73	20.25
Reader 2	-3.88	22.22
DSA		
Reader 1	1.99	14.32
Reader 2	-3.09	15.62

Note.—SSD indicates shaded surface display images; DSA, digital subtraction angiograms.

the standard of reference. All subsequent CT angiographic and DSA data were then compared with this standard.

The error in each estimate was calculated by subtracting that estimate from the reference standard for each case. The mean and variance of each error distribution were then calculated. The mean of this distribution reflects any bias toward overestimation or underestimation, and the standard deviation reflects variability in judgments relative to the original clinical report. The error distributions of the DSA and CT angiographic data were compared by a mixed model analysis of variance of the error data.

Since 70% stenosis is the degree of narrowing reflecting whether surgery is or is not advised by NASCET criteria, the data were also converted to binary values using the 70% criterion, and sensitivity and specificity were calculated relative to the clinical reference standard. Sensitivity of the different protocols was compared using McNemar's test, with α level adjusted by Bonferroni's inequality (12).

Results

Error measures for each procedure and for individual observers were calculated and are shown in the Table. There was a significant effect using CT angiography versus DSA on mean error ($f[2,186] = 5.98$; $P = .003$). Estimates of stenosis using the SSD images alone significantly underestimated stenosis relative to catheter angiography ($f[1,93] = 5.87$), whereas the surface-rendered and axial images combined did not ($f[1,93] = .00$, $P = .989$) (Fig 1). Additionally, a test of homogeneity of variance showed that the variability of error was greater in the condition in which only the SSD images were viewed ($P < .05$).

Sensitivity and specificity of readers' judgments were considered as binary choices. Pooled surface-rendered judgments alone were significantly less sensitive than pooled surface-

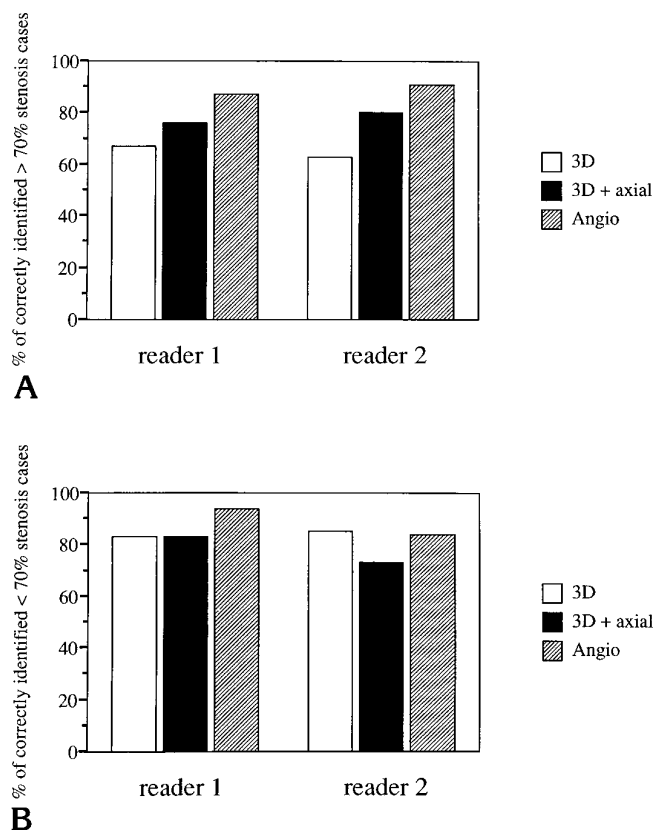


Fig 1. Graphic representation of the results of correctly identified cases of stenosis greater than 70% (A) and less than 70% (B).

rendered and axial image judgments (McNemar $\chi^2 = 6.72$, $P = .009$) or pooled angiography (McNemar $\chi^2 = 12.25$, $P = .005$), which did not significantly differ from one another. There were no significant differences in specificity.

The discrepancies found between the DSA estimates and the standard of reference were attributed to the inherent limitations in angiographic accuracy due to intrareader and inter-reader variability, as has been reported in a number of studies (13–16).

Discussion

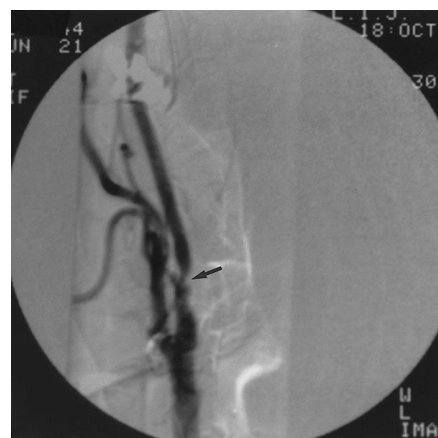Judgments of stenosis based on surface-rendered images underestimate the degree of stenosis and show increased variability relative to judgments based on DSA images. These problems are reduced when the radiologist simultaneously views the source images.

A number of anatomic characteristics of stenotic carotid arteries may contribute to the difficulties with CT angiographic surface-rendered images. These include short segment stenosis,

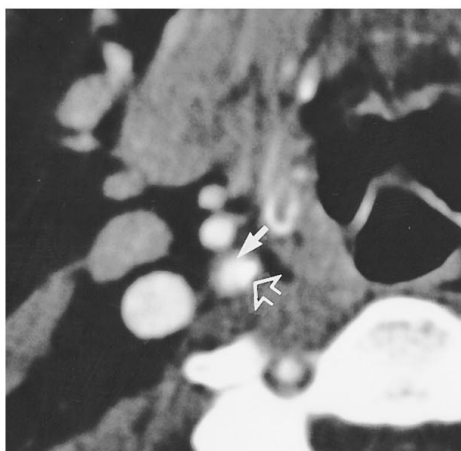
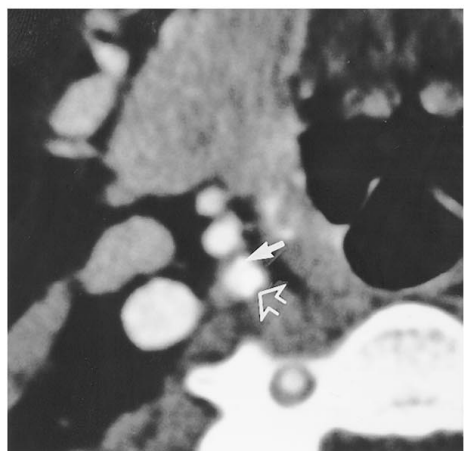
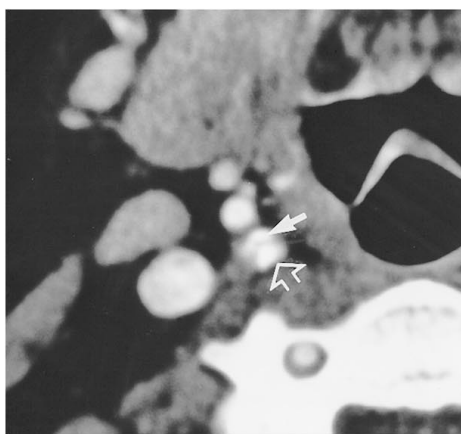
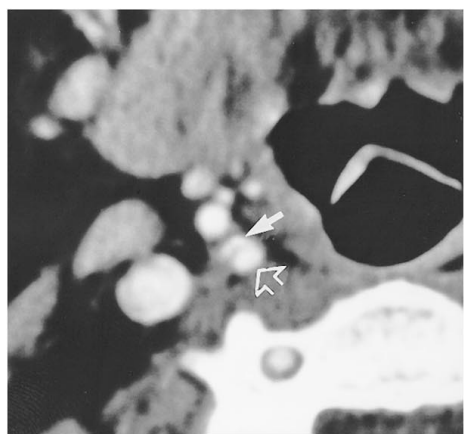
Fig 2. A, DSA image in lateral projection shows high-grade stenosis (arrow) of 75% by NASCET criteria.

B, Sequential CT source images show stenotic lumen (solid arrows) in the internal carotid artery caused by calcified plaque (open arrows).

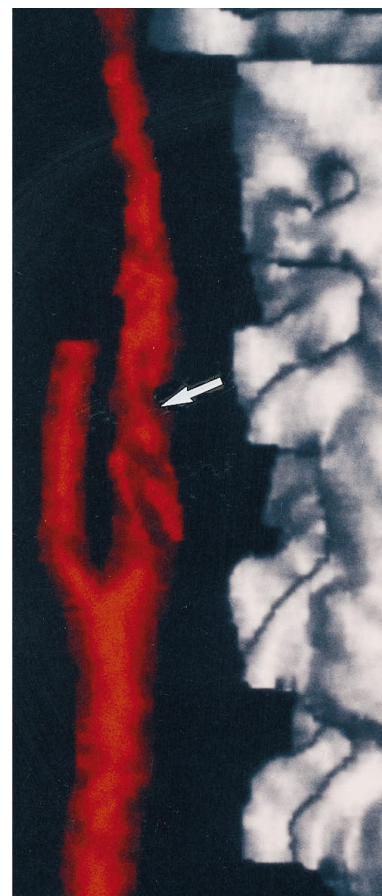
C, Three-dimensional SSD image of the internal carotid artery shows gross underestimation of stenosis (arrow points to site of stenosis seen in A and B).



A



B



C

vessel tortuosity, and calcification. All these anatomic changes produce volume averaging, which in turn causes the vessel lumen to appear larger above and below the stenosis, leading to a 3-D SSD representation that grossly underestimates the stenosis.

Figure 2 provides such an example. Figure 2A is the angiographic representation of a ves-

sel with a high-grade stenosis about 2 to 3 mm in length. Figure 2B shows the CT source images obtained sequentially through the same stenosis as on the DSA image. These sections show partial voluming due to severe calcification, which is manifested as normal lumen of the stenotic region because of the limitation of the section thickness (3 mm, with a 2- to 3-mm

stenotic segment). Figure 2C is the 3-D SSD reconstruction of the same vessel as on the DSA and source images, and depicts a gross underestimation of the stenosis. As is shown in this example, access to source images may reduce the effects of partial voluming and improve accuracy in the evaluation of the degree of stenosis.

In conclusion, our study suggests that spiral CT angiography in the evaluation of occlusive disease of the carotid arteries has the potential to complement conventional angiography and/or to be an alternative to other diagnostic techniques. CT angiography can be used as a screening test in patients who refuse or cannot tolerate catheter angiography. It can also be useful as a follow-up study. Our experience shows that the 3-D presentation in conjunction with the source images enhances the accuracy of evaluation of carotid artery stenoses by CT angiography.

Acknowledgments

We thank John Chang, Jon Cohen, and Glenn Faust from the Department of Vascular Surgery for referring patients for this study. We also thank Ann Fletcher, Fran Falco, and Terri Eacobacci for their help in preparing the manuscript.

References

1. Kalender WA, Polacin A. Physical performance characteristics of spiral CT scanning. *Med Phys* 1991;18:910-915
2. Kalender WA, Seissler W, Lotz E, et al. Spiral volumetric CT with single-breath-hold technique, continuous transport, and continuous scanner rotation. *Radiology* 1990;176:181-183
3. Dillon EH, van Leeuwen MS, Fernandez MA, Mali PTM. Spiral CT angiography. *AJR Am J Roentgenol* 1993;160:1273-1278
4. Napel S, Marks MP, Rubin GD, et al. CT angiography with spiral CT and maximum intensity projection. *Radiology* 1992;185:607-610
5. Magnusson M, Lenz R, Danielsson PE. Evaluation of methods for shaded surface display of CT volumes. *Comput Med Imaging Graph* 1991;15:247-256
6. Marks MP, Napal S, Jordan JE, et al. Diagnosis of carotid artery disease: preliminary experience with maximum-intensity-projection spiral CT angiography. *AJR Am J Roentgenol* 1993;160:1267-1271
7. Schwartz RB, Jones KM, Chernoff DM, et al. Common carotid artery bifurcation: evaluation with spiral CT. *Radiology* 1992;185:513-519
8. Dillon EH, van Leeuwen MS, Fernandez MA, et al. CT angiography: application to the evaluation of carotid artery stenosis. *Radiology* 1993;189:211-219
9. Cumming MJ, Morrow IM. Carotid artery stenosis: a prospective comparison of CT angiography and conventional angiography. *AJR Am J Roentgenol* 1994;163:517-523
10. Castillo M. Diagnosis of disease of the common carotid artery bifurcation: CT angiography vs catheter angiography. *AJR Am J Roentgenol* 1994;162:997-999
11. Fox AJ. How to measure carotid stenosis. *Radiology* 1993;186:316-318
12. Hays WL. *Statistics for the Social Sciences*. 4th ed. New York, NY: Holt Rinehart & Winston; 1988:410-414
13. Chikos PM, Fisher LD, Hirsch JH, et al. Observer variability in evaluating extracranial carotid artery stenosis. *Stroke* 1983;14:885-892
14. Fisher M, Ahmadi J, Zee CS, Weiner JM. Variability in arteriographic assessment of the carotid bifurcation. *Angiology* 1987;38:116-120
15. Brown PM, Johnston KW. The difficulty of quantifying the severity of carotid stenosis. *Surgery* 1982;92:468-473
16. Karkow WS, Cranley JJ. Variations in interpretation of arterial stenosis. *J Cardiovasc Surg* 1989;30:826-832