



## Discover Generics

Cost-Effective CT & MRI Contrast Agents



WATCH VIDEO

# AJNR

### **Arterial injuries in transsphenoidal surgery for pituitary adenoma; the role of angiography and endovascular treatment.**

J Raymond, J Hardy, R Czepko and D Roy

*AJNR Am J Neuroradiol* 1997, 18 (4) 655-665

<http://www.ajnr.org/content/18/4/655>

This information is current as of June 1, 2025.

# Arterial Injuries in Transsphenoidal Surgery for Pituitary Adenoma: The Role of Angiography and Endovascular Treatment

J. Raymond, J. Hardy, R. Czepko, and D. Roy

**PURPOSE:** To define the role of angiography and embolization in the treatment of patients who have arterial injuries during transsphenoidal surgery. **METHODS:** We retrospectively studied the arterial hemorrhagic complications, their management, and the clinical outcomes that occurred in 21 of the more than 1800 patients who had transsphenoidal surgery for pituitary adenomas. **RESULTS:** Of the 21 patients who had complications, 17 had internal carotid injuries and four had injuries of the sphenopalatine artery. Angiography was performed in 18 patients. Bleeding occurred and was controlled during surgery in 16 cases. Delayed epistaxis occurred in 10 patients, including five whose surgery was uneventful. After internal carotid injury, the most frequent angiographic findings were carotid occlusion (eight patients), stenosis (five patients), and false aneurysms (three patients). Internal carotid balloon occlusion was performed in five patients. No rebleeding occurred in patients who had complete carotid occlusion either from surgical packing or balloon embolization. Two of the patients who had carotid stenosis after surgical packing had delayed epistaxis necessitating balloon occlusion. Injuries to the sphenopalatine artery were successfully treated by surgery (one patient) or by endovascular treatment (three patients) without complication. Three deaths and five permanent deficits were directly related to the arterial injury or its treatment. **CONCLUSION:** Profuse bleeding during or after transsphenoidal surgery should be investigated by angiography. Lesions of the sphenopalatine arteries are effectively treated by embolization. Internal carotid injuries are best treated by carotid occlusion to prevent life-threatening epistaxis.

**Index terms:** Adenoma; Surgery, complications; Pituitary gland, neoplasms

*AJNR Am J Neuroradiol* 18:655–665, April 1997

Hemorrhagic complications during or after transsphenoidal surgery are rare, but when they occur they may lead to permanent disability or death (1). Anecdotal cases of carotid cavernous fistulas (2–4) and carotid false aneurysms (5–9) have been reported.

Many hazards and pitfalls of transsphenoidal surgery can be anticipated with experience and a thorough knowledge of anatomy. While many complications can be prevented, arterial injuries

can still occur given a sufficient number of operations on difficult lesions. The ability to treat complications once they have occurred is important in attaining a satisfactory outcome. The endovascular approach has proved useful in the management of some of these complications (4). We retrospectively reviewed all arterial complications after transsphenoidal surgery in our institution in an effort to improve prevention and treatment of these events and to define the role of angiography and endovascular treatment in that setting.

## Materials and Methods

Since 1969, all hemorrhagic complications that occurred in conjunction with the more than 1800 transsphenoidal surgeries performed in our institution have been recorded. After excluding patients with profuse venous bleeding from the cavernous sinus and those with postoperative hematomas following resection of giant adenomas

---

Received May 21, 1996; accepted after revision October 14.

From the Departments of Radiology and Neurosurgery (J.R., J.H., D.R.), University of Montréal (Quebec, Canada), Hôpital Notre-Dame, and the Department of Neurosurgery, Jagiellonian University, Krakow, Poland (R.C.).

Address reprint requests to Jean Raymond, MD, Department of Radiology, Hôpital Notre-Dame, 1560 Sherbrooke St E, Montreal, Quebec, Canada H2L 4M1.

*AJNR* 18:655–665, Apr 1997 0195-6108/97/1804-0655

© American Society of Neuroradiology

(10), we had 21 patients, of whom one was referred for endovascular treatment of a carotid injury after transsphenoidal surgery at another center.

We retrospectively studied the medical records and angiographic findings of these patients to search for risk factors. Individual treatment and related complications were noted as was the final outcome. Tumors were graded according to the radiologic classification described by Hardy (11). Adhesion to the carotid artery, invasion of the cavernous sinus, and carotid anomalies were noted on imaging studies performed before transsphenoidal surgery, and perioperative findings were reviewed.

The surgical technique used for transsphenoidal surgery has been described in detail elsewhere (11). In the event of intraoperative carotid injury, the cervical carotid artery was compressed to give sufficient time for tamponade with a variety of materials (including Surgicel [Johnson & Johnson], muscle plugs, tissue adhesives), which were held in place by closing the sellar window with a piece of cartilage or bone. Postoperative angiography was performed early after surgery in 12 patients or after delayed epistaxis in six patients. Three patients were not studied by angiography. Angiographic findings were labeled as normal or as showing carotid occlusion, stenosis, and false aneurysms. An occlusion was, by definition, a complete arrest of arterial flow. A stenosis was described as a narrowing involving the anterior wall of the carotid siphon below the origin of the ophthalmic artery. Extravasation of contrast material or opacification of a pouch of any shape was labeled a false aneurysm.

For endovascular occlusion of the carotid artery, latex balloons were hand tied with elastic ligatures on 2F microcatheters, as described by Debrun et al (12). The balloons were navigated as close as possible to the injured segment and inflated with contrast only. A 30-minute occlusion test was then performed, during which tolerance was assessed by clinical examination and collateral circulation was assessed by angiography, using the contralateral femoral artery. If carotid occlusion was well tolerated, the balloon was detached by simple traction and a second security balloon detached at the origin of the internal carotid artery.

When a false aneurysm of the sphenopalatine artery was found, the artery was selectively catheterized using Tracker catheters (Target Therapeutics; Fremont, Calif) and occluded with platinum coils (Target Therapeutics) or tissue adhesive (Histoacryl; B. Braun Melsungen AG, Melsungen, Germany). One patient had bilateral distal internal maxillary artery embolization with 250 to 355  $\mu$ m particles (Contour emboli, International Therapeutics Corp; Fremont, Calif).

## Results

### *Patients*

Nine men and 12 women comprised the study group. Ages ranged from 22 to 74 years, with a mean age of 40 years. Patient information, presenting signs and symptoms, radiologic

classification of tumors, previous treatment, and predisposing factors or surgical events are summarized in Table 1. The time of the hemorrhagic episodes, angiographic findings, surgical or endovascular management, complications of treatment, and outcomes are summarized in Table 2.

### *Predisposing Surgical Difficulties*

Predisposing surgical difficulties included cavernous sinus invasion by tumor (seven patients), adhesion of the tumor to the carotid artery (three patients), previous transsphenoidal surgery (five patients), radiation therapy (four patients), and long-term bromocriptine therapy (five patients). In seven patients, the surgical tract deviated from the midline and the cavernous sinus was accidentally entered; in three of these patients, sphenoidal sinus abnormalities (honeycomb configuration, nonpneumatized sphenoid bone, and oblique sphenoidal septum) were predisposing factors for deviation. One patient had a giant thrombosed cavernous aneurysm.

### *Intraoperative and Delayed Epistaxis*

Intraoperative arterial hemorrhage occurred in 16 patients. In 11 of these, the hemorrhage was well controlled and did not recur. Ten patients had delayed massive epistaxis. These events occurred as early as 6 hours and as late as 10 years after transsphenoidal surgery, but most commonly between 8 and 15 days after surgery (see Table 2). These delayed hemorrhagic events followed uneventful procedures in five patients.

### *Angiographic Findings*

In 12 patients, immediate postoperative angiography was performed after packing to control bleeding. In six other patients, angiography was performed only after delayed massive epistaxis. Cerebral angiography was not performed in three patients early in our experience. Multiple angiograms were obtained in five patients. Angiographic findings are summarized in Table 3.

Complete occlusion of the carotid siphon, a few millimeters below the origin of the ophthalmic artery, was the most frequent finding (eight patients). The occlusion was not always perma-

TABLE 1: Patients and predisposing surgical difficulties

Case	Sex/Age, y	Clinical Syndrome	Radiologic Classification	Cavernous Sinus Invasion	Previous Treatment	Predisposing Factors or Surgical Events
1	F/51	Cushing	I	No	None	None
2	F/55	Visual	II	No	None	Tract deviation; nonpneumatized sphenoid
3	F/22	Amenorrhoea	I	No	Bromocriptine	Tract deviation; multiple sphenoidal septa
4	F/38	Cushing	II	No	None	Tract deviation; oblique sphenoidal septum
5	F/48	Acromegaly	II	No	Somatostatine	Tumor adherent to carotid artery
6	M/27	Cushing	II	No	None	Tract deviation
7	F/44	Cushing	I	No	TSS	Tract deviation
8	M/27	Acromegaly	II	No	None	Tract deviation; acromegalic changes
9	M/42	Cushing	II	No	TSS, radiation	Tract deviation
10	M/48	Cushing	IV	Yes	None	Cavernous sinus invasion
11	F/36	Visual	IV	Yes	Bromocriptine	Cavernous sinus invasion
12	M/26	Acromegaly	III	Yes	None	Tumor adherent to carotid artery
13	M/28	Acromegaly	II	Yes	Radiation, TSS	Cavernous sinus invasion
14	F/50	Visual	I	Yes	TSS, radiation, bromocriptine	Cavernous sinus invasion
15	M/41	Impotence	I	No	Bromocriptine	Tumor adherent to carotid artery
16	F/74	Visual	IV	Yes	None	Cavernous aneurysm/cavernous invasion
17	M/49	Visual	IV	Yes	TSS × 2, radiation	Cavernous sinus invasion
18	F/33	Galactorrhea	II	No	Bromocriptine	Sphenopalatine artery avulsion during opening
19	F/34	Galactorrhea	I	No	None	None
20	M/40	Acromegaly	II	No	None	None
21	F/41	Acromegaly	IIB	No	None	Bleeding difficult to control during opening

Note.—TSS indicates transsphenoidal surgery.

nent: one patient had another angiogram (24 hours later) that showed an irregular stenosis at the same site (case 15). An eccentric, irregular, stenotic lesion of the anterior carotid siphon, below the origin of the ophthalmic artery, was found in five patients (Fig 1). Anterior or middle cerebral occlusion from emboli were found in two patients who also had ipsilateral carotid stenoses (cases 2 and 5). One patient had post-operative carotid occlusion and basilar artery displacement and compression (case 11). A false aneurysm of the internal carotid artery was found in three patients (cases 1, 13, and 16) (Fig 2). False aneurysms of the sphenopalatine artery were found in two patients (cases 19 and 20) (Fig 3). One patient had a normal angiogram (case 21). No patient had a carotid cavernous fistula.

#### *Surgical Management of Hemorrhagic Complications*

Profuse intraoperative bleeding from the internal carotid artery occurred in 14 patients.

Bleeding was controlled by surgical packing in all cases, but recurred later in three patients. Intraoperative bleeding from the sphenopalatine artery was noted in two patients and controlled by coagulation.

Repeat transsphenoidal surgery for epistaxis was performed in four patients. One patient (case 18) had successful repeat surgery on the same day to clip a bleeding sphenopalatine artery. Three patients had repeat surgery and packing after delayed epistaxis from carotid injury: one on day 9 with success (case 12) and one on day 9 followed by endovascular occlusion of the carotid artery, without recurrence (case 4). One patient had repeat surgery on day 12 for massive epistaxis, during which he had cardiac arrest and died (case 10).

Cranial nerve deficits were present after surgery in six patients, including four who had complete ophthalmoplegia and three who had unilateral blindness.

Cerebral ischemic complications after surgery included death in one patient who had carotid occlusion and basilar artery compres-

TABLE 2: Hemorrhagic complications and management

Case	Bleeding Episodes	Angiographic Findings	Treatment	Complications	Outcome	Follow-up
1	Three postop and four 10 y later	10 y: false aneurysm of carotid artery	Balloon occlusion	None	Good	12 y
2	Intraop	Postop: carotid stenosis, ACA embolus	Surgical packing	III, IV, VI NP, blindness	Fair, enucleation	10 y
3	Intraop	Postop: carotid occlusion	Surgical packing	None	Good	7 y
4	Intraop	Day 1: stenosis	Surgical packing on day 9	III, IV, VI NP	Fair, unilateral blindness	4 y
		Day 7: normal	Balloon occlusion on day 9	Blindness		
5	Day 9 Intraop	Day 9: occlusion	Surgical packing	VI NP, hemiplegia, aphasia	Fair	3 y
6	Intraop	Postop: carotid stenosis	Surgical packing, balloon occlusion and extracranial-intracranial bypass	Hemiplegia	Fair	2 y
7	Intraop	Postop: carotid occlusion	Surgical packing	III, IV, VII NP	Good	1 y
8	Intraop	Postop: carotid occlusion	Surgical packing	None	Good	6 mo
9	Intraop	Postop: carotid stenosis	Surgical packing, balloon occlusion	MCA infarct at 5 mo	Fair	2 y
	Three on days 6–9	Day 9: minimal carotid stenosis				
10	Three on day 12	No angiography	Attempt at reoperation	Hemorrhage	Death on day 12	...
11	Intraop	Postop: carotid occlusion, basilar artery compression	Surgical packing	Brain stem infarction	Death on day 7	...
12	Three on day 9	After second TSS: carotid occlusion	Surgical packing on day 9	III NP	Good	2 y
13	Intraop	Postop: normal	Surgical packing	None	Good	5 y
		Day 10: false aneurysm				
		5 y later: false aneurysm				
14	Intraop	No angiography	Surgical packing	None	Good	3 y*
15	Intraop	Postop day 0: carotid occlusion	Surgical packing	III, IV, VI NP	Good, III NP	6 mo
		Day 1: carotid stenosis	Balloon occlusion			
16	Intraop and 2 y later	Postop: false aneurysm	Surgical packing could not tolerate carotid occlusion test	III NP, blindness	Fair, death from epistaxis at 2 y	2 y
17	Intraop	Postop: carotid occlusion	Surgical packing	III, IV, VI NP	Fair	2 mo*
18	Intraop and 6 h later	No angiography	Reop, sphenopalatine artery clipping	None	Good	6 y
19	Day 11	Day 11: sphenopalatine false aneurysm	Sphenopalatine occlusion with coil	None	Good	1 y
20	Day 13	Day 13: sphenopalatine false aneurysm	Sphenopalatine artery occlusion with glue	None	Good	2 y†
21	Intraop and on day 15	Day 15: normal	Bilateral internal maxillary artery embolization	None	Good	3 mo

Note.—NP indicates nerve palsy; ACA, anterior cerebral artery; MCA, middle cerebral artery; TSS, transsphenoidal surgery; postop, postoperative; and intraop, intraoperative.

\* Died of recurrent tumor.

† Died of cardiomyopathy.

**TABLE 3: Angiographic findings in 21 patients who had arterial injuries during transsphenoidal surgery for pituitary adenoma**

Carotid occlusion	8
Carotid stenosis	6
Carotid false aneurysm	3
Sphenopalatine false aneurysm	2
Middle cerebral artery occlusion	1
Anterior cerebral artery occlusion	1
Basilar artery compression	1
Normal	1
Carotid cavernous fistula	0
<b>Total*</b>	<b>23</b>

\* Some patients have more than one finding.

sion, and hemiplegia and aphasia in one patient who had a middle cerebral artery embolus associated with carotid stenosis. It is worth noting the absence of ischemic complications in seven patients who had carotid occlusion after surgical packing of the sella.

#### *Endovascular Treatment of Sphenopalatine Artery Injuries*

Two patients had false aneurysms of the sphenopalatine artery, which were revealed by angiography performed after massive epistaxis 11 and 13 days, respectively, after uneventful transsphenoidal surgery. They were treated by selective occlusion of the sphenopalatine artery with fiber microcoils (case 19) or Histoacryl (case 20) with no recurrence and no complications (Fig 3).

One patient had epistaxis 15 days after transsphenoidal surgery, during which difficulties were encountered upon opening the sphenoidal sinus. Angiographic findings were completely normal and hemorrhage did not recur after empiric embolization of both internal maxillary arteries with particles (case 21); injury to the sphenopalatine artery was presumed to be the cause of hemorrhage.

#### *Endovascular Treatment of Internal Carotid Artery Injuries*

Five patients had balloon occlusion of the carotid artery and one patient had balloon test occlusion only. This last patient had persistent epistaxis after transsphenoidal surgery for a large adenoma associated with a cavernous carotid aneurysm (case 16). A new false aneurysm of the carotid artery was found arising from the cavernous lesion, but the patient could

not tolerate carotid test occlusion and she declined extracranial-intracranial (EC-IC) bypass. Bleeding spontaneously abated but she died 2 years later of massive epistaxis.

One patient (case 1) had three episodes of epistaxis 4 days after an apparently uneventful transsphenoidal operation for microadenoma associated with Cushing syndrome. Ten years later, she had four episodes of massive epistaxis resulting from a false aneurysm of the carotid artery. Balloon occlusion of the internal carotid artery was performed without complication and without recurrence (Fig 2).

One patient (case 4) was treated by permanent balloon occlusion despite the fact that the internal carotid artery was already occluded from packing performed during a second transsphenoidal surgery. This patient had three successive angiographic studies showing first a carotid "stenosis," which was treated conservatively, then a normal angiogram before discharge; she was readmitted in shock from massive epistaxis and had a second transsphenoidal operation to control bleeding by packing followed by the endovascular procedure with no recurrence and no complications.

Another patient (case 15) had complete occlusion of the carotid artery after intraoperative packing to control bleeding from carotid injury. A repeat angiographic study 24 hours later showed the typical irregular stenosis of the anterior wall of the carotid siphon. Permanent balloon occlusion was performed without recurrence or complication.

In two other patients (cases 6 and 9), recurrent massive epistaxis was associated with a carotid stenosis, and balloon occlusion of the carotid artery was performed (Fig 1).

#### *Ischemic Complications of Balloon Occlusion*

All patients treated by permanent balloon occlusion of the carotid artery had tolerated the 30-minute occlusion test. Nevertheless, one patient (case 6) had aphasia and hemiparesis 6 hours after occlusion, which was treated by emergency EC-IC bypass. The bypass thrombosed within hours and the patient suffered a moderate infarction of the middle cerebral artery territory with slow but incomplete recovery. Another patient (case 9) had transient hemiparesis 24 hours after balloon occlusion with no sequelae. Bilateral adrenalectomy was performed 5 months later, complicated postopera-

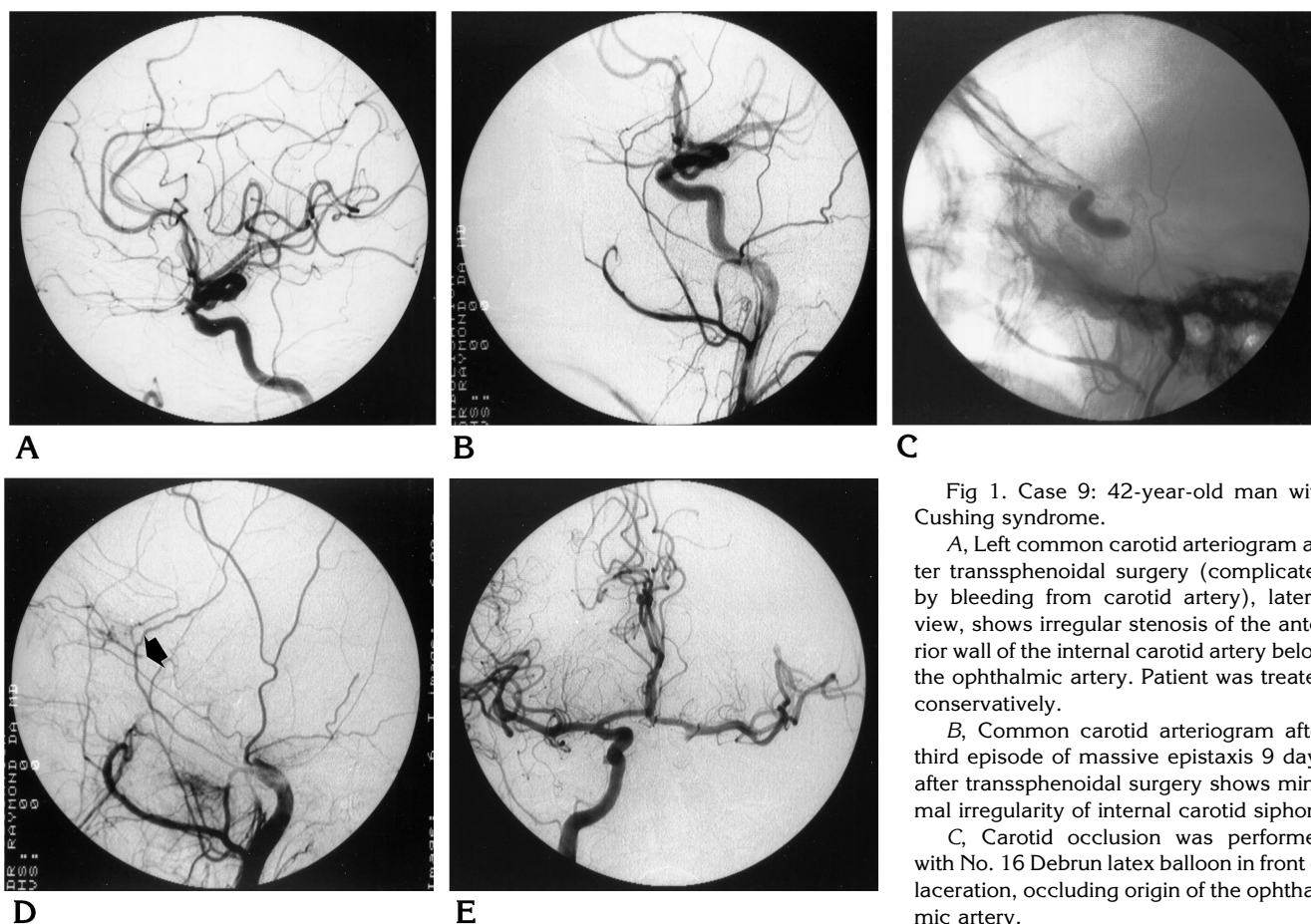


Fig 1. Case 9: 42-year-old man with Cushing syndrome.

A, Left common carotid arteriogram after transsphenoidal surgery (complicated by bleeding from carotid artery), lateral view, shows irregular stenosis of the anterior wall of the internal carotid artery below the ophthalmic artery. Patient was treated conservatively.

B, Common carotid arteriogram after third episode of massive epistaxis 9 days after transsphenoidal surgery shows minimal irregularity of internal carotid siphon.

C, Carotid occlusion was performed with No. 16 Debrun latex balloon in front of laceration, occluding origin of the ophthalmic artery.

D, Common carotid injection during occlusion shows retrograde opacification of ophthalmic artery (arrow) via collaterals from external carotid branches.

E, Right internal carotid arteriogram during occlusion shows adequate anterior communicating artery collateral filling. Permanent carotid occlusion was performed with no further episode of bleeding.

tively by a new infarction in the territory of the middle cerebral artery and hemiparesis, from which he completely recovered.

### Outcomes

The follow-up period varied from 7 days to 12 years (mean, 37 months). None of the patients with complete carotid occlusion rebled during the follow-up period. Two patients left with carotid stenosis did not rebleed, but one had a fair outcome from optic nerve injury (case 2) and the other had cerebral ischemia associated with a secondary embolus (case 5). Two patients with carotid stenosis rebled and were finally treated by carotid occlusion without recurrence (cases 4 and 9). All patients with sphenopalatine injuries had a good outcome with no recurrence of bleeding. Three deaths were directly related to the hemorrhagic complication or sub-

sequent treatment (14% related mortality): one patient died during a second operation for delayed massive epistaxis (case 10), one patient left untreated died 2 years after transsphenoidal surgery of massive epistaxis (case 16), and one patient died of hemispheric and brain stem infarction after packing to control carotid bleeding (case 11).

Five patients had residual deficits at follow-up (24% related morbidity): one had permanent ophthalmoplegia, two had permanent unilateral blindness, one had residual hemiparesis and dysphasia, and one had hemiplegia.

Three more deaths occurred that were unrelated to transsphenoidal surgery (14% unrelated mortality): two from recurrent invasive malignant tumors (cases 14 and 17) and one from acromegalic cardiomyopathy (case 20). The remaining 10 patients had a good outcome (48%).

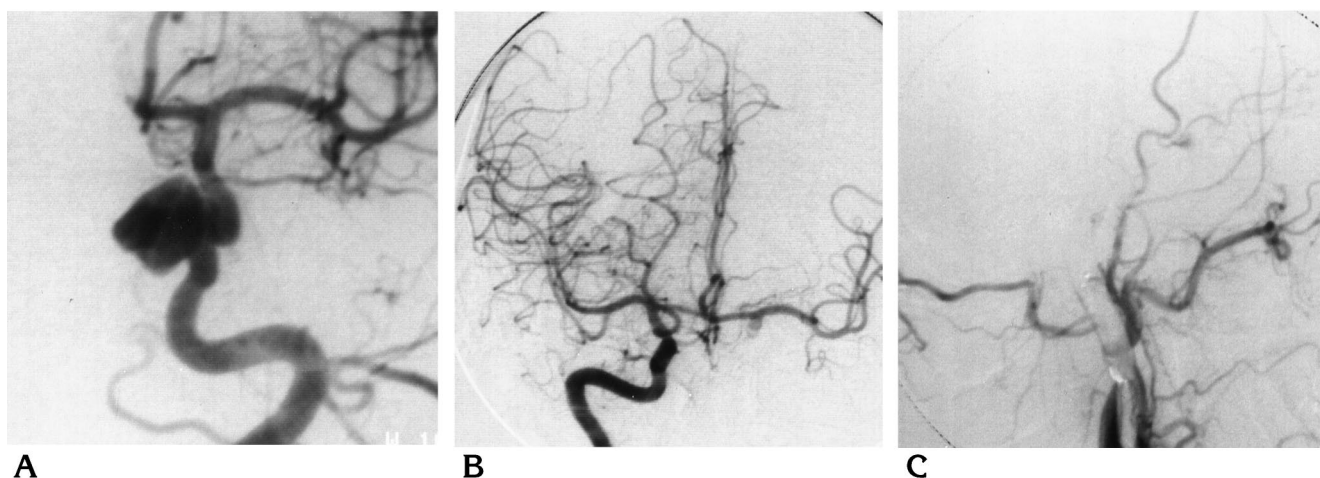


Fig 2. Case 1: 51-year-old woman with Cushing syndrome.

A, Left internal carotid arteriogram, oblique projection, after three episodes of massive epistaxis 10 years after transsphenoidal surgery shows false aneurysm of the internal carotid artery.

B, Right internal carotid injection shows adequate collateral circulation via circle of Willis.

C, Left common carotid arteriogram after permanent balloon occlusion of the internal carotid artery.

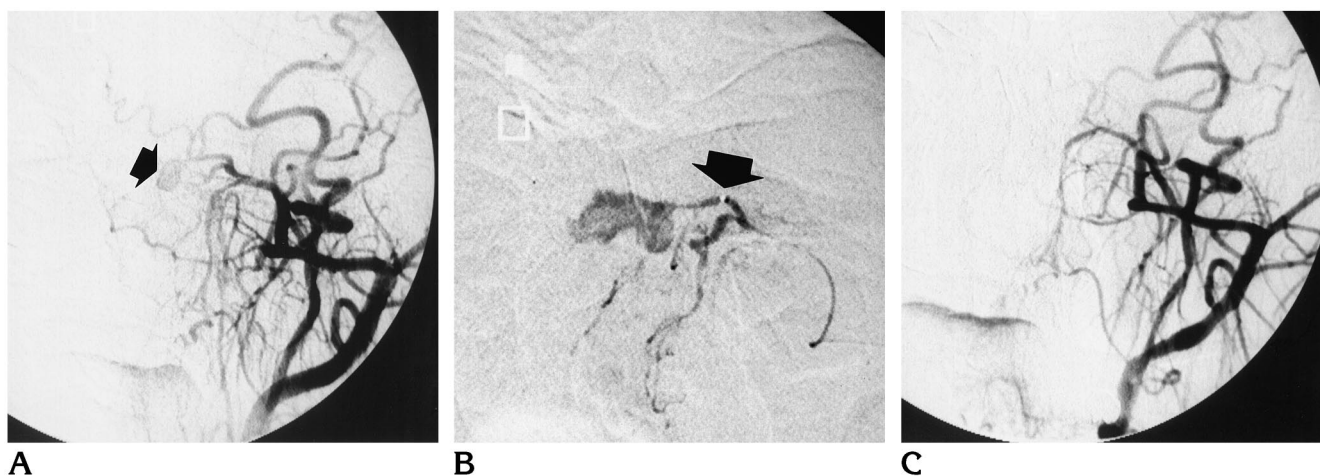


Fig 3. Case 20: 40-year-old man with acromegaly and massive epistaxis 13 days after transsphenoidal surgery.

A, External carotid arteriogram, anteroposterior view, shows false aneurysm of the septal branch of the sphenopalatine artery (arrow).

B, Selective injection of sphenopalatine artery; note metallic marker (arrow) at the tip of microcatheter. There was some reflux of contrast material, permitting opacification of the lateral branch. Embolization of the septal branch with 0.02 mL Histoacryl 50% was performed.

C, Postembolization external carotid arteriogram, anteroposterior view, shows occlusion of the septal branch of the sphenopalatine artery. Patient had no further bleeding at 2-year follow-up.

## Discussion

Arterial injuries during or after transsphenoidal surgery were relatively rare (1%) but were associated with significant morbidity (24%) and mortality (14%) in our series of 21 patients. These events may involve the sphenopalatine artery or, more frequently, the internal carotid artery.

## Sphenopalatine Artery Injuries

False aneurysms of the sphenopalatine artery occurring after transsphenoidal surgery have not been well described. They are less frequently recognized but an important cause of epistaxis that can be treated easily. The injury usually occurs during enlargement of the sphenoidal opening with the punch rongeur. This



artery is located in the hidden inferior lateral corner of the sphenoidal sinus; it can be avulsed, but then is difficult to coagulate because it has a tendency to retract toward the maxilla (13). The injury can go unrecognized and cause delayed life-threatening epistaxis, as was the case in patients 19 and 20. Delayed epistaxis occurred after 11, 13, and 15 days in three patients (cases 19, 20, and 21, respectively); for this reason, bilateral selective internal maxillary angiography should be part of the angiographic work-up when epistaxis occurs after transsphenoidal surgery. Embolization of these lesions proved successful in two patients (cases 19 and 20). The sphenopalatine artery anastomoses with ethmoidal branches of the ophthalmic artery. Other branches of the internal maxillary artery in the vicinity of the sphenopalatine artery anastomose to meningeal branches of the carotid artery and supply the trigeminal nerve. These anastomoses are potential causes of neurologic complications after embolization, which can be minimized with an adequate knowledge of anatomy and experience in endovascular techniques (14). Reoperation and clipping of a bleeding sphenopalatine artery a few hours after transsphenoidal surgery (case 18) was also performed. Empiric embolization of both distal internal maxillary arteries was successful in controlling an epistaxis presumed to be caused by sphenopalatine artery injury, but without angiographic confirmation (case 21).

### *Carotid Injuries*

Injuries to the carotid artery are more frequent, and treatment with occlusion carries the risk of associated cerebral ischemic complications. The indications for conservative treatment versus carotid occlusion have not always been clear and deserve further discussion.

*Predisposing Factors.*—Carotid injuries represent 80% of arterial injuries in this series. As already mentioned (1, 13, 15), these lesions occur more frequently during transsphenoidal surgery for large invasive adenomas. Lesions located laterally close to the cavernous sinus and cavernous segment of the carotid artery, even if small, are more at risk, as seen in three cases in our series. An attempt at complete resection of adenomas invading the cavernous sinus in six other patients with grade IV adenomas caused recognized laceration of the carotid

artery or delayed massive epistaxis from pseudoaneurysm. Hemorrhagic complications seem to occur more frequently in patients who have had transsphenoidal surgery or who have been treated by radiation therapy. These complications may be due to the higher risk of deviation from the midline because of distorted anatomy, more difficult dissection caused by fibrosis after radiation therapy or prolonged bromocriptine therapy, or they may simply reflect a more aggressive attempt at complete resection of lesions invading the cavernous sinus (13).

Carotid anomalies may predispose to injury during transsphenoidal surgery (13). These anomalies are usually recognized on imaging studies obtained before surgery. A cavernous carotid aneurysm was the single carotid anomaly of this series. Carotid arteries protruding into the sella were usually recognized and respected (13).

A strict midline tract is essential to minimize the risk of carotid injuries. Anatomic variations of the sphenoidal sinus, such as a honeycomb configuration or absence of pneumatization, are well-known pitfalls of transsphenoidal surgery (13) and were predisposing factors in two of six deviations from the midline and in carotid laceration by a bone chip avulsed from an oblique sphenoidal septum in a third patient.

Patients with acromegaly (six in our series) may be more at risk for this complication because of a distortion of nasal and sinusal anatomy (16) and a tendency to have tortuous and ectatic carotid arteries that may protrude into the sella (17).

*Initial Control.*—Life-threatening perioperative bleeding was controlled initially in all cases by vigorous packing with a variety of material. Packing may be difficult when all bony structures are destroyed by giant invasive grade IV lesions. "Overpacking" was associated with complete carotid occlusion, carotid stenosis, and basilar artery compression, and it may have contributed to postoperative ophthalmoplegia and optic nerve injury in some cases (15). These secondary complications appear difficult to prevent, since packing has to continue until life-threatening hemorrhage is effectively controlled.

*Delayed Epistaxis.*—Although most arterial injuries were recognized and controlled at the time of transsphenoidal surgery, three patients had carotid lesions that remained unnoticed until they caused massive epistaxis. In three other

patients with carotid injuries, bleeding was thought to be controlled but epistaxis recurred. Fatal or life-threatening epistaxis occurred as much as 2 years and 10 years after transsphenoidal surgery. These delayed events, despite satisfactory initial control, illustrate the need to examine all patients by selective angiography after transsphenoidal surgery that has been complicated by profuse bleeding or followed by epistaxis.

*Postoperative Angiography after Carotid Injuries.*—Postoperative angiographic findings reflect the injury and surgical treatment performed to control bleeding. Carotid occlusions and stenoses are probably caused by tight packing. Reversibility of the occlusion in one patient (case 15), variations in the degree of stenosis (case 9), and return to a normal appearance in another (case 4) suggest a variable and possibly temporary host reaction, such as local spasm, parietal hematoma, dissection, or partial thrombosis. Possible recanalization may expose the patient to risks of cerebral emboli, pseudoaneurysm formation, and recurrence of hemorrhagic episodes. Carotid stenoses were found in five patients who had intraoperative carotid injuries. Initially thought to be benign, this finding was associated with delayed life-threatening epistaxis in two patients (cases 4 and 9). Emboli were also encountered in two patients with carotid stenosis (cases 2 and 5). We now consider this finding to be a significant lesion that should be treated by permanent balloon occlusion. Complete postoperative carotid occlusions were found in eight patients. The occlusion was always located in the anterior carotid siphon, below the ophthalmic artery. Because of a long segment of absent blood flow between the origin of the internal carotid artery and the site of occlusion, the obstruction may erroneously be thought to be located more proximally. Layering of contrast material behind the column of unopacified blood may also mimic a dissection. This occlusion is usually permanent, but in one patient it proved reversible after 24 hours. Permanent occlusion of the carotid artery with balloons was done in a patient in whom the carotid was already occluded after packing. This patient had two life-threatening episodes of epistaxis after a sequence of three different angiographic findings (case 4).

To prove that carotid occlusion after surgical packing is permanent, a repeat carotid angiogram should be obtained 7 to 10 days later,

before discharge. A normal angiogram after transsphenoidal surgery complicated by carotid injury does not guarantee against recurrence, as seen in one of our patient (case 4) and as reported previously (4, 8, 18, 19). We also recommend a control angiogram 7 to 10 days later, before discharge, in any patient with normal angiographic findings after transsphenoidal surgery complicated by carotid injury that was well controlled by packing (4, 20).

According to our wide definition, false aneurysms of the carotid artery were encountered in three patients in this series. One patient had in fact a true cavernous aneurysm complicated by an iatrogenic rupture during transsphenoidal surgery. She suffered a fatal episode of epistaxis 2 years after a failed balloon test occlusion and refusal of further treatment. We have followed up another patient with an apparent, very small asymptomatic lesion, who is stable after 5 years (case 13). Because of the unusual location of the lesion (proximal cavernous segment) and atypical morphology, the significance of this finding and its relationship to surgical trauma were questioned. We do not, however, recommend this strategy when a false aneurysm is likely.

One patient had the typical presentation and angiographic appearance of a pseudoaneurysm (case 1). These lesions have been reported in patients who have had transsphenoidal surgery (4–7); they are most dangerous and should be treated by carotid occlusion (4). An attempt at endovascular occlusion of a false aneurysm with preservation of the carotid artery has been reported (9). We believe this experimental technique presents additional risks (19) and subtotal occlusion carries the risk of life-threatening recurrent epistaxis. Similarly, attempts at preserving the carotid artery in cases of carotid cavernous fistulas have been reported to be followed by massive epistaxis in two patients (4–8). We did not encounter an arteriovenous fistula, which probably reflects adequate packing after arterial injury.

*Endovascular Carotid Occlusion.*—The best treatment of carotid injuries is carotid occlusion. Reoperation for bleeding is no longer recommended. The endovascular approach is simple and can immediately follow the diagnostic study. The detachable balloon technique is well established and has been practiced for many years (12, 21–25). Controlled endovascular occlusion is more predictable than intraoperative

occlusion by packing and permits a test occlusion of the carotid artery to minimize ischemic complications. Carotid occlusion under emergency conditions is not without risks. Two of our patients suffered ischemic complications, despite a negative test occlusion, one with permanent disability. When another surgical treatment is indicated to treat the endocrine syndrome, meticulous blood pressure control is vital during subsequent general anesthesia.

The use of cerebral blood flow imaging in association with carotid test occlusion remains controversial. Many techniques have been described to help predict tolerance to a carotid occlusion that may become necessary during elective skull base surgery or during treatment of giant aneurysms (25–34). These elective physiological studies are certainly more difficult to apply in the setting of life-threatening epistaxis. Despite an incomplete circle of Willis, we elected to sacrifice the carotid artery in one patient (case 6) because of poorly controlled epistaxis. The other patient who suffered a postoperative stroke 5 months after carotid sacrifice probably had clinically inapparent, borderline cerebral perfusion that could have been detected by more sophisticated physiological testing. A patient who fails the test occlusion (either by clinical examination or cerebral blood flow imaging testing) is a candidate for some form of surgical bypass, provided that epistaxis is well controlled and that the hemodynamic condition is stable. These surgical procedures are not without risks, and their value in preventing ischemic complications is still controversial (21, 34–38). An additional operation on a patient who has suffered recent massive blood losses combined with the risks of temporizing the eradication of a dangerous carotid injury may jeopardize the theoretical benefits of revascularization techniques. We have chosen to restrict the use of bypass techniques to patients who fail the clinical test. A more liberal use of revascularization may or may not improve the overall outcome in this setting.

It is worth noting that eight of the 11 patients with carotid occlusion had no ischemic complication and none ever rebled.

#### *Prevention and Management of Arterial Injuries*

Careful planning of transsphenoidal surgery is possible with modern imaging. Anatomic

variations can be detected and problems with sphenoidal septa can be anticipated. Lesions lying close to the cavernous sinus or invading the sinus close to the carotid artery will be approached with caution when the risks of lacerating the carotid artery are known. A strict midline approach is essential, and the risks for patients who have had previous transsphenoidal surgery or radiation therapy should be kept in mind.

Any sudden arterial bleeding can usually be controlled by packing. Immediate postoperative angiography should be performed in all patients and should include bilateral selective internal maxillary injection when difficulties were encountered upon opening the sphenoidal sinus or after delayed epistaxis. We recommend balloon occlusion of the carotid artery for carotid cavernous fistulas, carotid stenoses, and carotid false aneurysms, provided the patient can tolerate carotid test occlusion and the circle of Willis is satisfactory. If there is doubt regarding tolerance to occlusion and bleeding has temporarily abated, a bypass procedure could be performed and the balloon test occlusion repeated. If postoperative angiographic findings are normal, a repeat control study is recommended after nasal packing is removed and before the patient is discharged. When postoperative angiography shows complete occlusion, permanent balloon occlusion may be performed. If balloon occlusion is not performed, a control angiogram before discharge is recommended to establish that the occlusion is permanent. Patients can be followed up by MR imaging to evaluate residual tumor and exclude a growing false aneurysm. Any delayed episode of significant or unusual epistaxis occurring after transsphenoidal surgery should be considered serious and selective angiography of both internal carotid and internal maxillary arteries should be performed.

Lesions of the sphenopalatine arteries can be easily treated by embolization. Carotid injuries are best treated by carotid balloon occlusion despite the risks of cerebral ischemia in order to prevent life-threatening bleeding episodes.

#### **Conclusion**

Careful planning of transsphenoidal surgery and a meticulous technique may prevent rare vascular complications. Angiography is mandatory when these injuries occur. Endovascular

treatment has proved effective in the management of complications from arterial injuries in transsphenoidal surgery.

## References

- Zervas NT. Surgical results for pituitary adenomas: results of an international survey. In: Black PMcL, Zervas NT, Ridgway EC Jr, Martin JB, eds. *Secretory Tumors of the Pituitary Gland*. New York, NY: Raven Press; 1984:377-385
- Pigott TJD, Holland IM, Punt JAG. Carotico-cavernous fistula after transsphenoidal hypophysectomy. *Br J Neurosurg* 1989;3:613-616
- Takahashi M, Killeffer F, Wilson G. Iatrogenic carotid cavernous fistula: case report. *J Neurosurg* 1969;30:498-500
- Ahuja A, Guterman LR, Hopkins LN. Carotid cavernous fistula and false aneurysm of the cavernous carotid artery: complications of transsphenoidal surgery. *Neurosurgery* 1992;31:774-779
- Cabezudo JM, Carrillo R, Vaquero J, Areitio E, Martinez R. Intracavernous aneurysm of the carotid artery following transsphenoidal surgery. *J Neurosurg* 1981;54:118-121
- Paullus WS, Norwood CW, Morgan HW. False aneurysm of the cavernous carotid artery and progressive external ophthalmoplegia after transsphenoidal hypophysectomy. *J Neurosurg* 1979;51:707-709
- Reddy K, Lesiuk H, West M, Fewer D. False aneurysm of the cavernous carotid artery: a complication of transsphenoidal surgery. *Surg Neurol* 1990;33:142-145
- Wilson CB, Dempsey LC. Transsphenoidal microsurgical removal of 250 pituitary adenomas. *J Neurosurg* 1978;48:13-22
- Kinugasa K, Mandai S, Tsuchida S, Kamata I, Ohmoto T. Direct thrombosis of a pseudoaneurysm after obliteration of a carotid-cavernous fistula with cellulose acetate polymer: technical case report. *Neurosurgery* 1994;35:755-760
- Mohr G, Hardy J, Comtois R, Beauregard H. Surgical management of giant pituitary adenomas. *Can J Neurol Sci* 1990;17:62-66
- Hardy J. Transsphenoidal approach to the sella. In: Wilson CB, ed. *Neurosurgical Procedures: Personal Approaches to Classic Operations*. Baltimore, Md: Williams & Wilkins; 1992:21-40
- Debrun G, Fox A, Drake C, Peerless S, Girvin J, Ferguson G. Giant unclippable aneurysms: treatment with detachable balloons. *AJNR Am J Neuroradiol* 1981;2:163-173
- Hardy J, McCutcheon IE. Pituitary microadenomas. In: Apuzzo MLJ, ed. *Brain Surgery: Complication Avoidance and Management*. New York, NY: Churchill Livingstone; 1992:276-295
- Lasjaunias P, Berenstein A. The internal maxillary system. In: *Surgical Neuro-angiography, 1: Functional Anatomy of Craniofacial Arteries*. New York, NY: Springer-Verlag; 1989:33-122
- Laws ER, Kern EB. Complications of transsphenoidal surgery. *Clin Neurosurg* 1976;23:401-416
- Hardy J. Traitement chirurgical de l'adénome hypophysaire. In: *Neuro-chirurgie: Acromégalie-gigantisme*. Paris, France: Masson; 1973:75-99
- Hatam A, Greitz T. Ectasia of cerebral arteries in acromegaly. *Acta Radiol* 1972;12:410-419
- Landolt AM. Carotid cavernous fistula and false aneurysm of the cavernous carotid artery: complications of transsphenoidal surgery: comments. *Neurosurgery* 1992;31:778-779
- Standard SC, Guterman LR, Hopkins L. Comments in: Direct thrombosis of a pseudoaneurysm after obliteration of a carotid-cavernous fistula with cellulose acetate polymer: technical case report. *Neurosurgery* 1994;35:759
- Wilson CB. Carotid cavernous fistula and false aneurysm of the cavernous carotid artery: complications of transsphenoidal surgery: comments. *Neurosurgery* 1992;31:779
- Raymond J, Théron J. Intracavernous aneurysms: treatment by proximal balloon occlusion of the internal carotid. *AJNR Am J Neuroradiol* 1986;7:1087-1092
- Fox AJ, Vinuela F, Pelz DM, et al. Use of detachable balloons for proximal artery occlusion in the treatment of unclippable cerebral aneurysms. *J Neurosurg* 1987;66:40-46
- Higashida RT, Halbach VV, Dowd C, et al. Endovascular detachable balloon embolization therapy of cavernous carotid artery aneurysms: results in 87 cases. *J Neurosurg* 1990;72:857-863
- Raymond J, Fontaine S, Dufresne M-P, et al. L'occlusion de la carotide par ballonnet détachable: indications, résultats et complications. *Radiologie* 1990;10:299-303
- Vazquez Anon V, Aymard A, Gobin YP, et al. Balloon occlusion of the internal carotid artery in 40 cases of giant intracavernous aneurysm: technical aspects, cerebral monitoring, and results. *Neuroradiology* 1992;34:245-251
- Peterman SB, Taylor A, Hoffman JC. Improved detection of cerebral hypoperfusion with internal carotid balloon test occlusion and <sup>99m</sup>Tc-HMPAO cerebral perfusion SPECT imaging. *AJNR Am J Neuroradiol* 1991;12:1035-1041
- Monsein LH, Jeffery PJ, van Heerden BB, et al. Assessing adequacy of collateral circulation during balloon test occlusion of the internal carotid artery with <sup>99m</sup>Tc-HMPAO SPECT. *AJNR Am J Neuroradiol* 1991;12:1045-1051
- Eskridge JM. The challenge of carotid occlusion. *AJNR Am J Neuroradiol* 1991;12:1053-1054
- Frackowiak R. Reply. *AJNR Am J Neuroradiol* 1992;13:1151-1152
- Eckard DA, Purdy PD, Bonte FJ. Temporary balloon occlusion of the carotid artery combined with brain blood flow imaging as a test to predict tolerance prior to permanent carotid sacrifice. *AJNR Am J Neuroradiol* 1992;13:1565-1569
- Barker DW, Jungreis CA, Horton JA, Pentheny S, Lemley T. Balloon test occlusion of the internal carotid artery: change in stump pressure over 15 minutes and its correlation with xenon CT cerebral blood flow. *AJNR Am J Neuroradiol* 1993;14:587-590
- McIvor NP, Willinsky RA, TerBrugge KG, Rutka JA, Freeman JL. Validity of test occlusion studies prior to internal carotid artery sacrifice. *Head Neck* 1994;16:11-16
- Brunberg JA, Frey KA, Horton JA, Deveikis JP, Ross DA, Koeppe RA. <sup>15</sup>OH<sub>2</sub>O positron emission tomography determination of cerebral blood flow during balloon test occlusion of the internal carotid artery. *AJNR Am J Neuroradiol* 1994;15:725-732
- Moody EB, Dawson RC, Sandler MP. <sup>99m</sup>Tc-HMPAO SPECT imaging in interventional neuroradiology: validation of balloon test occlusion. *AJNR Am J Neuroradiol* 1991;12:1043-1044
- Ishikawa T, Houkin K, Abe H, Isobe M, Kamiyama H. Cerebral haemodynamics and long term prognosis after extracranial-intracranial bypass surgery. *J Neurol Neurosurg Psychiatry* 1995;59:625-628
- The EC/IC Bypass Study Group: Failure of extracranial-intracranial arterial bypass to reduce the risk of ischemic stroke: results of an international randomized trial. *N Engl J Med* 1985;313:1191-1200
- Schmiedek P, Piepgras A, Leinsinger G, Kirsch C-M, Einhaupl K. Improvement of cerebrovascular reserve capacity by EC-IC arterial bypass surgery in patients with ICA occlusion and hemodynamic cerebral ischemia. *J Neurosurg* 1994;81:236-244
- Sekhar LS, Patel SJ. Permanent occlusion of the internal carotid artery during skull-base and vascular surgery: is it really safe? *Am J Otol* 1993;14:421-422