



Providing Choice & Value

Generic CT and MRI Contrast Agents



CONTACT REP

AJNR

Single-photon emission CT findings in acute Japanese encephalitis.

K Kimura, A Dosaka, Y Hashimoto, T Yasunaga, M Uchino and M Ando

AJNR Am J Neuroradiol 1997, 18 (3) 465-469

<http://www.ajnr.org/content/18/3/465>

This information is current as of July 19, 2025.

Single-Photon Emission CT Findings in Acute Japanese Encephalitis

Kazumi Kimura, Akihiro Dosaka, Yoichiro Hashimoto, Tadamasa Yasunaga, Makoto Uchino, and Masayuki Ando

PURPOSE: To determine the usefulness of single-photon emission CT (SPECT) in the diagnosis of acute Japanese encephalitis (JE). **METHODS:** We examined 10 patients (six men and four women; mean age, 69 years) with viral encephalitis. We divided the cases into two groups: the JE group (n = 4) and the non-JE group (n = 6; two with herpes simplex encephalitis and four with encephalitis of unknown origin). All cases were investigated with ^{99m}Tc -hexamethylpropyleneamine oxime (HMPAO) SPECT within 15 days after the onset of symptoms. Two patients in the JE group were also examined by SPECT at a later stage. In all cases MR imaging was performed after the SPECT study. **RESULTS:** In the acute stage, all patients in the JE group showed a marked increase of HMPAO uptake that matched the hyperintense area observed on MR images in the thalami and putamina bilaterally. Follow-up SPECT studies of two patients with JE revealed a decrease of HMPAO deposition in the areas of high uptake. None of the patients in the non-JE group had an increased accumulation of HMPAO in the thalami or the putamina. **CONCLUSIONS:** SPECT is helpful in differentiating JE from herpes simplex encephalitis and other types of encephalitis. SPECT may be useful as a diagnostic tool in the early stages of JE.

index terms: Encephalitis; Single-photon emission computed tomography

AJNR Am J Neuroradiol 18:465–469, March 1997

Epidemics of Japanese encephalitis (JE) occur in all countries throughout Asia (1). Japanese encephalitis usually appears in the summer and early fall, and is often severe, with rapid progression to coma. The characteristic neurologic findings during the acute stage are extrapyramidal signs, such as tremor, dystonia, and rigidity (2). When a patient with probable viral encephalitis has such neurologic signs, the diagnosis of JE is suspected. In the acute stage of JE, computed tomographic (CT) and magnetic resonance (MR) imaging findings are usually normal, and it takes 2 or 3 weeks to establish the diagnosis of JE serologically.

It is important to distinguish JE from other types of encephalitis, particularly herpes sim-

plex encephalitis, because antiviral therapy for herpes simplex encephalitis is very effective in the acute stage (3). Specific antiviral therapy is not available for JE; however, its treatment may require specific therapy, such as anticonvulsants and treatment for brain edema, respiratory, metabolic, and septic complications (4). We assessed the usefulness of brain perfusion scintigraphy with single-photon emission CT (SPECT) as a diagnostic tool for use in patients with acute JE.

Patients and Methods

Between April 1991 and September 1995, we examined 10 patients (six men and four women; mean age, 69 years) with viral encephalitis by using brain CT on admission, ^{99m}Tc -hexamethylpropyleneamine oxime (HMPAO) SPECT within 15 days after the onset of symptoms, and MR imaging in the latter half of the investigation. We divided the patients into two groups on the basis of the etiologic virus: the JE group, which consisted of four patients (cases 1 to 4) who had JE, and the non-JE group, which included two patients (cases 5 and 6) who had herpes simplex encephalitis and four patients (cases 7 to 10) who had encephalitis of unknown origin. The diagnosis of viral encephalitis was established when the patient had an abrupt or subacute onset of meningoencephalitis

Received May 1, 1996; accepted after revision October 7.

From the Departments of Cerebrovascular Disease (K.K.), Neurology (A.D., Y.H.), and Radiology (T.Y.), Kumamoto City (Japan) Hospital; and the Department of Neurology (M.U.) and the first Department of Internal Medicine (M.A.), Kumamoto University School of Medicine.

Address reprint requests to Kazumi Kimura, MD, Department of Cerebrovascular Disease, Kumamoto City Hospital, 1-1-60 Kotoh, Kumamoto City, Kumamoto 862, Japan.

AJNR 18:465–469, Mar 1997 0195-6108/97/1803-0465

© American Society of Neuroradiology

TABLE 1: Clinical, radiologic, and laboratory findings and outcome in four patients with Japanese encephalitis (JE)

Case	Age, y/Sex	Neurologic Symptoms	CSF Cell Count, mm ³	Serum Antibody Titers to JE Virus		SPECT		MR Imaging		Outcome
				Time after onset, d	HI	Time after Onset, d	Findings	Time after Onset, d	T2-Weighted Findings	
1	82/M	Coma	166	2	80	10	Increased perfusion in both thalami and putamina*	64	Abnormal high signal intensity in both thalami and putamina	Parkinsonism
				9	1280	41	Decreased perfusion in both thalami and putamina			
2	76/M	Coma	325	5	640	10	Increased perfusion in both thalami and putamina*	19	Abnormal high signal intensity in both thalami and putamina	Mild dementia
				10	5120	37	Decreased perfusion in both thalami and putamina			Parkinsonism
3	75/F	Coma	794	3	20	6	Increased perfusion in both thalami and putamina*	4	Abnormal high signal intensity in both thalami and putamina	Apathic state
4	72/F	Coma	912	19	640					
				4	20	4	Increased perfusion in both thalami and putamina*	75	Abnormal high signal intensity in both thalami and putamina	Apathic state
				24	80					

Note.—CSF indicates cerebrospinal fluid findings on admission; HI, hemagglutination inhibition test.

* $P < .001$ compared with non-JE group.

symptoms with electroencephalographic findings suggesting encephalitis and cerebrospinal fluid findings compatible with that diagnosis. The diagnosis of JE was established on the basis of the results of serologic examination; that is, a fourfold or greater rise in the hemagglutination inhibition test for JE virus in paired sera (5). The diagnosis of herpes simplex encephalitis was established by serologic findings of a significant increase in herpes simplex antibody titers on paired sera. All patients were tested serologically for JE and herpes simplex encephalitis.

The mean interval between the onset of symptoms of encephalitis and the first SPECT study was 7.5 days in the JE group and 8.2 days in the non-JE group. For SPECT imaging, a single-head rotating scintillation camera was used. Fifteen minutes after intravenous administration of 20 mCi (740 MBq) of ^{99m}Tc-HMPAO, 60 projections (six angles, sampling distance 2.73 mm) were obtained during a period of 30 minutes. After prereconstructional filtering of projections and correction for tissue absorption, 2.73-mm-thick axial cross sections (128 × 128 matrices) were reconstructed by filtered back-projection. The HMPAO uptake was recorded in 15 axial contiguous 1-cm-thick sections from 3 cm below the orbitomeatal line and superiorly. Two of the patients in the JE group were examined by SPECT again at 37 and 41 days after symptom onset. A radiologist and a neurologist independently evaluated the SPECT images visually and found the following abnormal

findings: the thalamic and/or putamenal activity was the same as or greater than the cortical activity, and the cortical activity in both hemispheres had increased unilaterally.

The mean interval between the onset of symptoms of encephalitis and MR imaging was 40 days in the JE group and 23 days in the non-JE group. In cases 1 and 3, MR imaging was performed on a 0.5-T superconducting magnet. The T1-weighted (500/20 [repetition time/echo time]) and T2-weighted (1800/110) MR images were obtained in the axial and sagittal planes. In cases 2 and 4 through 10, MR imaging was performed on a 1.5-T superconducting magnet. The T1-weighted (600/15) and T2-weighted (5500/110) MR images were obtained the axial and sagittal planes. Axial MR images were oriented parallel to the line of the anterior commissure-posterior commissure.

The χ^2 test was used to compare associations between the JE group and the non-JE group. The level of statistical significance was set at $P < .05$.

Results

The CT scans taken on admission revealed no abnormalities in any of our patients. Tables 1 and 2 summarize the clinical, SPECT, and MR findings of the study population.

TABLE 2: Clinical, radiologic, and laboratory findings and outcome in six patients with non-Japanese encephalitis

Case	Age, y/Sex	Neurologic Symptom	CSF Cell Count, mm ³	Cause of Encephalitis	SPECT		MR Imaging		Outcome
					Time after Onset, d	Findings	Time after Onset, d	T2-Weighted Findings	
5	62/M	Somnolence, R hemiparesis	63	Herpes simplex	15	Increased perfusion in L temporal lobe	50	Abnormal high signal intensity in L temporal lobe	Mild cognitive defects
6	69/M	Coma	89	Herpes simplex	6	Increased perfusion in R temporal lobe	18	Abnormal high signal intensity in R temporal lobe	Moderate cognitive defects
7	61/M	Somnolence	366	Unknown	8	Normal	13	Normal	No neurologic defects
8	76/F	Coma	10	Unknown	14	Normal	15	Normal	Apathic state
9	52/M	Somnolence	32	Unknown	4	Increased perfusion in L temporal lobe	13	Normal	Mild cognitive defects
10	62/F	Somnolence, seizures	38	Unknown	2	Normal	29	Normal	No neurologic defects, mild depression

Note.—CSF indicates cerebrospinal fluid findings on admission.

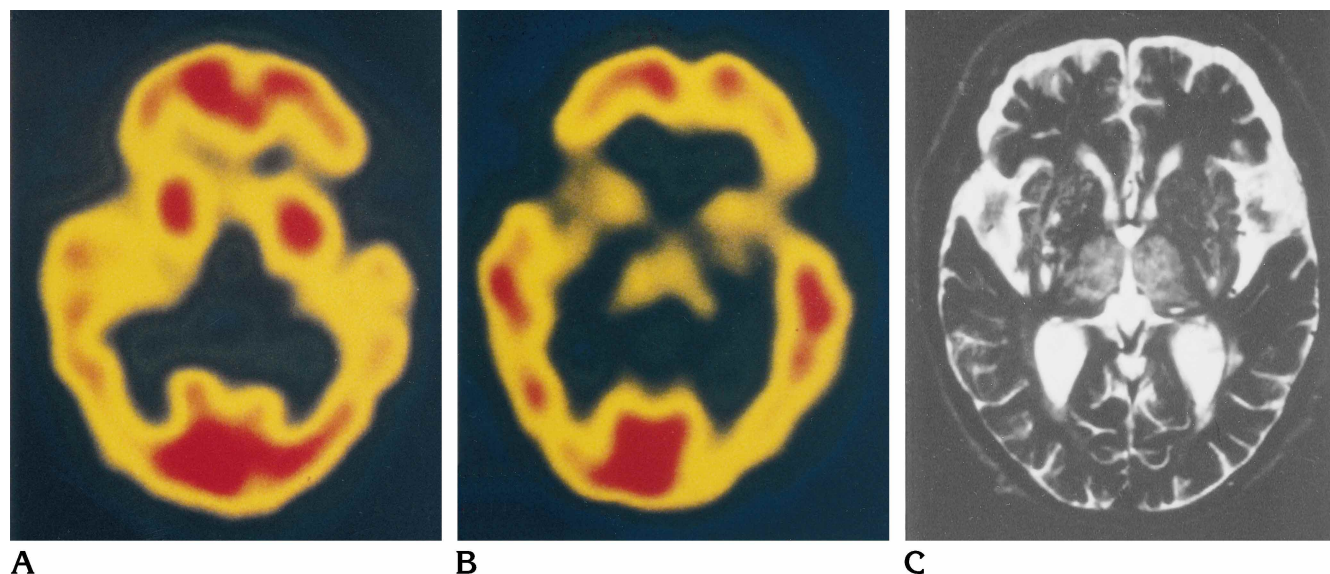


Fig 1. Case 2: 76-year-old man with Japanese encephalitis.
 A, SPECT scan 10 days after the onset of symptoms shows a marked increase of HMPAO accumulation in both thalami and putamina.
 B, Follow-up SPECT scan 37 days after the onset of symptoms shows a decrease of HMPAO deposition in the previously "active" areas.
 C, T2-weighted (5500/110/1 [repetition time/echo time/excitations]) MR image 19 days after the onset of symptoms shows high signal intensity in the thalami and putamina.

All the patients with JE had a marked increase of HMPAO accumulation in the bilateral thalami and putamina on the first SPECT study (Fig 1). In cases 1 and 2, the follow-up SPECT study revealed a decrease of HMPAO activity in the previously "active" areas. Moreover, all patients with JE had high signal intensity in the thalami and putamina on T2-weighted MR images. These findings were characteristic of the JE group ($P < .001$, χ^2 test).

In the non-JE group, two patients with herpes simplex encephalitis (cases 5 and 6) and one patient with encephalitis of unknown origin (case 9) had unilaterally increased perfusion of the temporal lobes without thalamic and putaminal activity (Fig 2), whereas in the other patients, SPECT revealed no abnormalities (Fig 3). None of the patients in the non-JE group had an increase of HMPAO accumulation in the thalami or putamina. In the patients with herpes

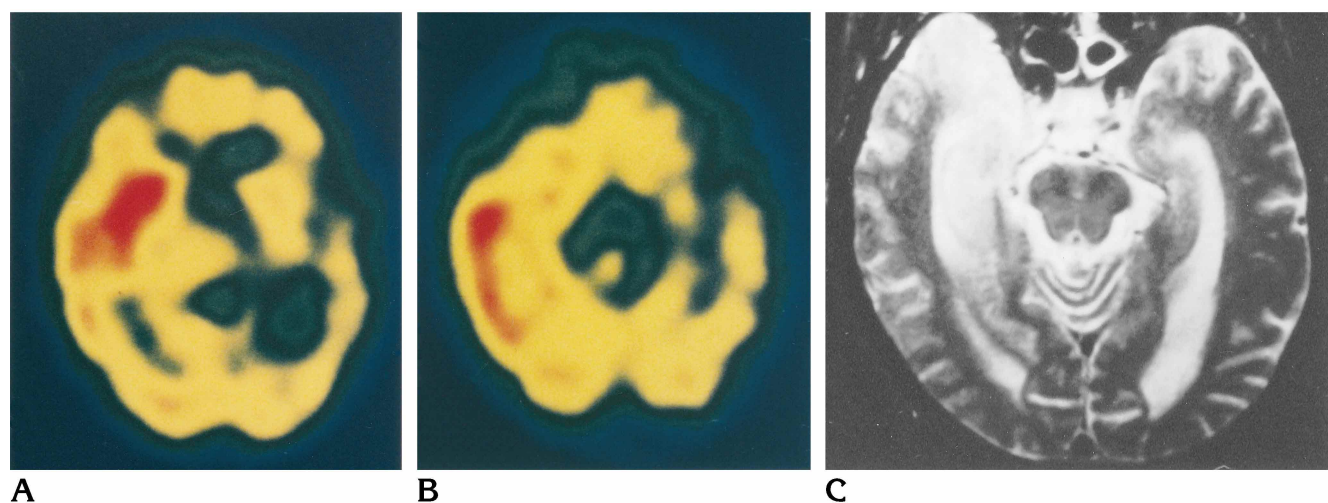


Fig 2. Case 6: 69-year-old man with herpes simplex encephalitis.

A, SPECT scan 6 days after the onset of symptoms shows a marked increase of HMPAO accumulation in the right temporal lobe without abnormal accumulation in the thalami or putamina.

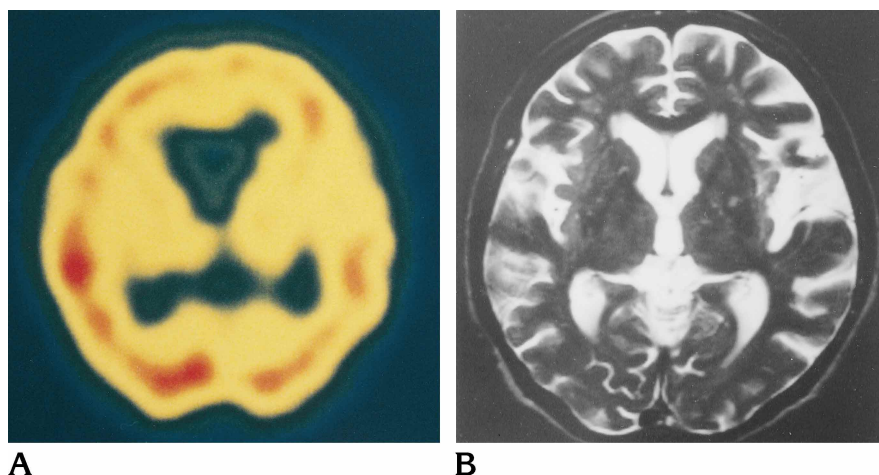
B, Another SPECT scan on same day shows a marked increase of HMPAO accumulation in the right temporal lobe.

C, T2-weighted (5500/110/1) MR image 18 days after onset of symptoms shows high signal intensity in the right temporal lobe.

Fig 3. Case 8: 76-year-old woman with encephalitis of unknown origin.

A, SPECT scan 14 days after the onset of symptoms shows no abnormalities.

B, T2-weighted (5500/110/1) MR image 15 days after the onset of symptoms shows no abnormalities.



simplex encephalitis, T2-weighted MR images showed high signal intensity in either the right or left temporal lobe (Fig 2). In the other patients, no abnormalities were observed on MR images (Fig 3).

Discussion

JE represents a serious health problem in Asia. Patients may rapidly progress to come, and for those over 50 years of age, this disease has a fatality rate of nearly 50% (4). At present, there is no specific treatment for JE. After the onset of symptoms, it takes 2 or 3 weeks to establish the diagnosis of JE serologically; thus, a sensitive and specific method to diagnose JE in the early stages would be of great benefit to

these patients. MR imaging and CT are commonly used for this purpose, but for most patients with acute JE, these techniques fail to show any abnormalities.

In patients with acute herpes simplex encephalitis, SPECT has been reported to be very useful because it shows an increased HMPAO uptake in the limbic and temporal lobes (6–9). But in adult patients with a nonherpes acute viral encephalitis, SPECT is not useful in the diagnostic workup. However, Kao et al (10) reported that abnormal findings were detected more often on SPECT scans than on CT or MR studies in children with acute viral encephalitis.

In our study, the first SPECT study disclosed a marked increase of HMPAO accumulation, which matched the hyperintense signal in the

thalami and putamina seen on MR images in patients with JE. More than 4 weeks after the onset of symptoms, decreased HMPAO activity was seen in the previously positive areas in two patients with JE. However, this finding was not seen in the patients with non-JE.

One group of investigators reported that patients with herpes simplex encephalitis showed a locally increased uptake of HMPAO in the acute stage of the disease, which then decreased at a later stage. In our study, we observed a similar phenomenon in patients with JE. Launes et al (6) hypothesized that an increased HMPAO uptake does not reflect a disruption of the blood-brain barrier but rather a local hyperperfusion or some other herpes simplex encephalitis-related abnormality that is currently unknown.

Shoji et al (11, 12) reported that MR imaging revealed abnormalities more clearly than CT in the thalamus and basal ganglia, including the putamen. In our study, all the patients had high signal intensity in the thalami and putamina on T2-weighted MR images, and these matched the areas of increased HMPAO uptake. In the acute stage of JE, pathologic findings are seen in the cerebral cortex, thalamus, basal ganglia, substantia nigra, brain stem, and anterior horn of the spinal cord. These include perivascular cuffing, glial nodules, and circumscribed necrotic foci (13, 14). The distribution of lesions in the thalamus and putamen found on MR imaging and SPECT studies was compatible with these pathologic findings. Recently, Dasai et al (15) reported that JE virus antigen was distributed in the human brain of autopsied cases in the thalamus, hippocampus, substantia nigra, and medulla oblongata. Our findings suggest that local hyperperfusion due to protracted inflammation was accompanied by high HMPAO uptake. The decreased accumulation of HMPAO at a later stage probably represents true hypoperfusion, since neuronal death results in decreased metabolism and a fall in regional blood flow.

It is important to distinguish JE from herpes simplex encephalitis and other JE-like diseases. If a patient with probable viral encephalitis has neurologic extrapyramidal signs, such as tremor, dystonia, and rigidity, in the summer and early fall, one should consider strongly the diagnosis of JE. When SPECT scans show a

marked increase of HMPAO uptake in the thalami and putamina bilaterally, the diagnostic probability of JE would be strengthened. Such patients would not then be treated with ineffective antiviral drugs, such as adenine arabinoside and acyclovir, thereby avoiding possible complications of drug toxicity with such therapy (eg, thrombocytopenia and disturbance of liver and kidney functions).

We conclude that SPECT is helpful in differentiating acute JE from herpes simplex encephalitis and other JE-like diseases, and therefore is useful in the early diagnosis of JE.

References

1. Umenai T, Krzysko R, Bektimirov TA, Assaad FA. Japanese encephalitis: current worldwide status. *Bull World Health Organ* 1985;63:625-631
2. Dickerson RB, Newton JR, Hansen JE. Diagnosis and immediate prognosis of Japanese B encephalitis. *Am J Med* 1952;12:277-288
3. Whitley RJ, Alford CA, Hirsch MS, et al. Vidarabine versus acyclovir therapy in herpes simplex encephalitis. *N Engl J Med* 1986; 314:144-149
4. Jackson AC, Johnson RT. *Handbook of Clinical Neurology*, 12th ed. New York, NY: Mckendall RR; 1989;125-148
5. Ishii K. Virological and serological diagnosis of Japanese encephalitis. *Adv Neurol Sci* 1967;11:300-311
6. Launes J, Nikkinen P, Lindroth L, Brownell AL, Liewendahl K, Livanainen M. Diagnosis of acute herpes simplex encephalitis by brain perfusion single photon emission computed tomography. *Lancet* 1988;1:1188-1191
7. Schmidbauer M, Podreka I, Wimberger D, et al. SPECT and MR imaging in herpes simplex encephalitis. *J Comput Assist Tomogr* 1991;15:811-815
8. Masdue JC, Van Heertum RL, Abdel DH. Viral infections of the brain. *J Neuroimaging* 1995;5:40-44
9. Lane R, Kirkbride V, Hughes P, Jones B, Costa D. Diagnosis of herpes simplex encephalitis by single photon emission computed tomography. *Lancet* 1989;1:778-779
10. Kao CH, Wang SJ, Mac SC, Shian WJ, Chi CS. Viral encephalitis in children: detection with technetium-99m HMPAO brain single photon emission CT and its value in prediction of outcome. *AJNR Am J Neuroradiol* 1994;15:1369-1373
11. Shoji H, Hiraki Y, Kuwasaki N, Kaji M, Okudera T. Japanese encephalitis in the Krume region of Japan: CT and MR findings. *J Neurol* 1989;236:255-259
12. Shoji H, Murakami T, Murai I, et al. A follow-up study by CT and MR in 3 cases of Japanese encephalitis. *Neuroradiology* 1990;32: 215-219
13. Haymaker LCW, Sabin AB. Topographic distribution of lesions in central nervous system in Japanese B encephalitis. *Arch Neurol Psychiatry* 1947;57:673-692
14. Zimmerman HM. The pathology of Japanese B encephalitis. *Am J Pathol* 1946;22:965-991
15. Desai A, Shanker SK, Ravi V, Chandramuki A, Gevi MG. Japanese encephalitis virus antigen in human brain and its topographic distribution. *Acta Neuropathol(Berl)* 1995;89:368-373