



## Discover Generics

Cost-Effective CT & MRI Contrast Agents



WATCH VIDEO

# AJNR

### **Self-induced ethmoidectomy from rhinotillexomania.**

R D Caruso, R G Sherry, A E Rosenbaum, S E Joy, J K  
Chang and D M Sanford

*AJNR Am J Neuroradiol* 1997, 18 (10) 1949-1950  
<http://www.ajnr.org/content/18/10/1949>

This information is current as  
of June 16, 2025.

---

# Self-induced Ethmoidectomy from Rhinotillexomania

Ronald D. Caruso, Richard G. Sherry, Arthur E. Rosenbaum, Stephen E. Joy, Ja Kwei Chang, and Douglas M. Sanford

**Summary:** A 53-year-old woman with a long history of compulsive nose picking (rhinotillexomania) presented with a large, self-inflicted nasal septal perforation and right-sided penetration of the ethmoidal sinus, or "ethmoidectomy."

**Index terms:** Nose, injuries; Paranasal sinuses

Chronic self-mutilation resulting in the loss of body parts is characteristically seen in schizophrenic patients. Such patients can have delusions of parasitic infestation of body parts, may believe the body part to be encumbered by foreign bodies, or may view the body part as no longer a part of themselves (1). Such behavior, however, may also be manifested by persons who are severely obsessive-compulsive or malingers (1).

## Case Report

A 53-year-old right-handed woman related a history of compulsive nose picking (rhinotillexomania) of the right nasal cavity since age 10. She could not control her compulsion, which involved removing recurrent intranasal crusts. This condition persisted while in the care of a psychiatrist. When referred to an otolaryngologist, a large right-sided self-induced ethmoidectomy cavity and a large nasal septal perforation from the trauma were noted. There was no history of nasal surgery, nor was an incision present. Computed tomography (CT) revealed the dilated ethmoidal cavity to be in proximity to both the orbit and the cribriform plate (Fig 1). Therapy was instituted in an effort to disrupt the cycle of digital trauma, mucus production, and crusting. This included behavior modification and supportive rhinologic care with nasal spray, crust suction, and medication. Early follow-up showed improvement.

## Discussion

Serious upper airway destruction due to compulsive nose picking is not addressed in standard textbooks of otolaryngology and pediatrics, although nose picking resulting in epistaxis

and/or septal perforation is cited (2–5). Conversely, the psychiatric literature has recognized that rhinotillexomania is a common, benign habit in children and adults that may rarely become a serious affliction advancing to significant self-injury (6). Such injuries are known to include nasal septal perforation and epistaxis, which may be resistant to control because of repetitive trauma (7–9). Anemia from the chronic blood loss may ensue, and subjects may attempt to conceal their affliction from their physician.

Interestingly, there are few prior reports of massive injury. Akhtar and Hastings (1) described a 36-year-old man, a compulsive nose picker, who had life-threatening epistaxis. Self-destructive behavior was so apparent that the left ala of the nose was absent, exposing the nasal passage. His injury was not the result of a true psychosis, but of a severe "passive-aggressive character disorder." Gigliotti and Waring (10) reported a 61-year-old woman with extensive self-mutilation affecting portions of the nasal septum, turbinates, hard palate, and other internal nasal structures such that a nasal prosthesis and complete upper denture had to be constructed. Neither of these case reports included radiologic studies.

The differential diagnosis in our patient would include granulomatous disease, such as Wegener granulomatosis, or cocaine abuse, although advanced unilateral involvement would be unusual.

In conclusion, we offer this uncommon case, with CT documentation, to demonstrate the extent of nasal and paranasal sinus destruction that may occur from self-inflicted digital nasal trauma in persons who are obsessive-compulsive or schizophrenic. The possibility of self-

---

Received August 29, 1996; accepted after revision January 10, 1997.

From the Department of Radiology, Division of Neuroradiology, State University of New York Health Science Center at Syracuse (R.D.C., A.E.R., S.E.J., J.K.C.); Northern Radiology Associates, Watertown, NY (R.G.S.); and Watertown Ear, Nose, & Throat Group PC, Watertown, NY (D.M.S.).

Address reprint requests to Ronald D. Caruso, MD, Department of Radiology, SUNY Health Science Center, 750 E Adams St, Syracuse, NY 13210.

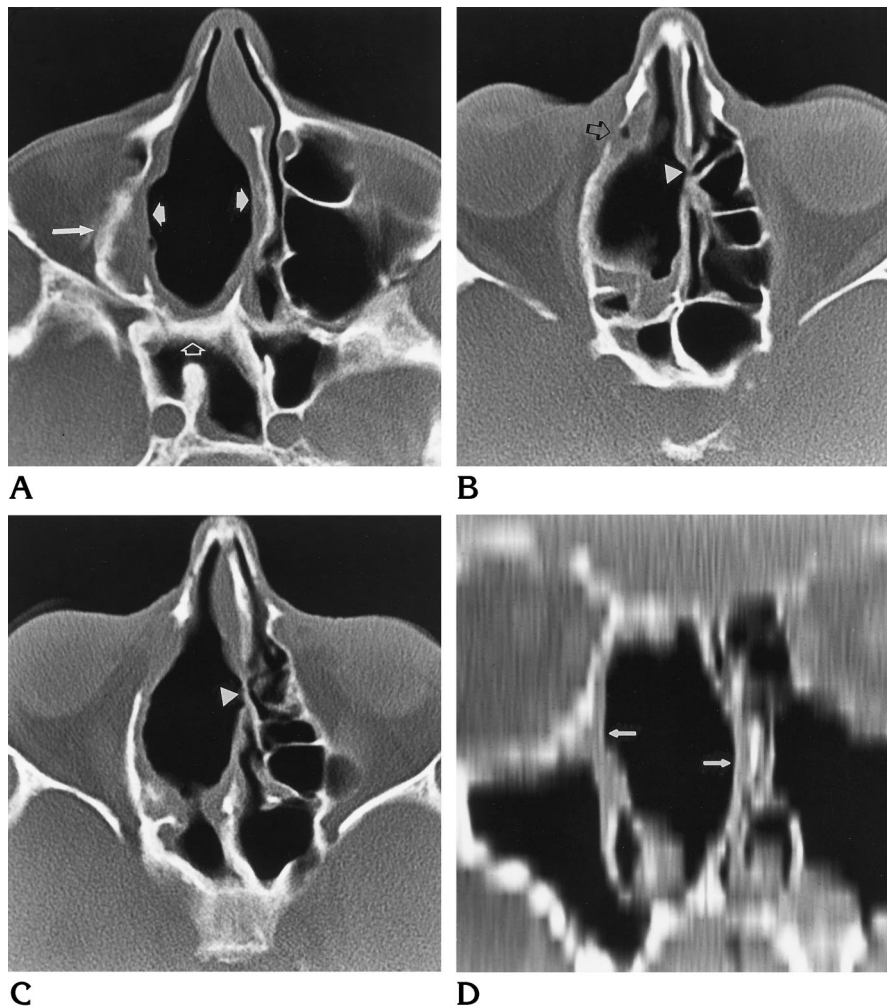
AJNR 18:1949–1950, Nov 1997 0195-6108/97/1810-1949 © American Society of Neuroradiology

Fig 1. CT scans show an extensive right-sided self-induced ethmoidectomy with deviated, perforated nasal septum.

A, Granulation tissue lines the large excavated cavity (short solid arrows). There is hyperostosis and remodeling of the medial wall of the right orbit (long arrow) and anterior wall of the sphenoidal sinus (open arrow).

B and C, A defect of the lamina papyracea is seen at the junction of the lacrimal bone and medial wall of the right orbit with granulation tissue containing gas (arrow); a nasal septal perforation is also present (arrowhead).

D, Coronal reformation through the self-induced ethmoidectomy cavity (arrows) shows extent from the floor of the nasal cavity to the inferior margin of the cribriform plate.



inflicted injuries should be considered whenever such findings are encountered.

## References

1. Akhtar S, Hastings BW. Life threatening self mutilation of the nose. *J Clin Psychiatry* 1978;39:676-677
2. Bluestone CD, Stool SE, Kenna MA. *Pediatric Otolaryngology*, 3rd ed. Philadelphia, Pa: Saunders; 1996:782-783
3. Cummings CW, Fredrickson JM, Harker LA, Krause CJ, Schuller DE. *Otolaryngology-Head and Neck Surgery*, 2nd ed. St Louis, Mo: Mosby-Year Book; 1993:726
4. Nelson WE, Behrman RE, Kliegman RM, Arvin AM. *Nelson Textbook of Pediatrics*, 15th ed. Philadelphia, Pa: Saunders; 1996: 1187
5. Rudolph AM, Hoffman JIE, Rudolph CD. *Rudolph's Pediatrics*, 20th ed. Stamford, Conn: Appleton & Lange; 1996:958
6. Jefferson JW, Thompson TD. Rhinotillexomania: psychiatric disorder or habit? *J Clin Psychiatry* 1995;56:56-59
7. Brooker DS, Cinnamon MJ. Young's procedure in the treatment of epistaxis. *J Laryngol Otol* 1991;105:847-848
8. Mina MM, Downar-Zapolski Z. Closure of nasal septal perforations. *J Otolaryngol* 1994;23:165-168
9. McDonald TJ. Nosebleed in children: background and techniques to stop the flow. *Postgrad Med* 1987;81:217-224
10. Gigliotti R, Waring HG. Self-inflicted destruction of nose and palate: report of case. *J Am Dent Assoc* 1968;76:593-596