



**Providing Choice & Value**

Generic CT and MRI Contrast Agents

**FRESENIUS  
KABI**

**CONTACT REP**

**AJNR**

**Cryptic vascular malformations:  
controversies in terminology, diagnosis,  
pathophysiology, and treatment.**

W P Dillon

*AJNR Am J Neuroradiol* 1997, 18 (10) 1839-1846

<http://www.ajnr.org/content/18/10/1839.citation>

This information is current as  
of July 31, 2025.

# Cryptic Vascular Malformations: Controversies in Terminology, Diagnosis, Pathophysiology, and Treatment

William P. Dillon, *University of California, San Francisco*

*The classification of vascular lesions of the brain is a very controversial topic. In the literature, the same type of tumor may be listed by various authors under different names.*

R. C. Schneider and L. Liss, 1958 (1)

Cryptic vascular malformations have intrigued clinicians since the first report of "calcifying epileptogenic hemangiomas" by Penfield and Ward appeared in 1948 (2). Despite many detailed radiologic and pathologic studies on the subject, controversy still exists regarding their underlying pathophysiology, terminology, and treatment. Are cryptic vascular malformations a heterogeneous group of malformations that appear identical on magnetic resonance (MR) images, or are they the manifestation of a common pathophysiological process resulting in a spectrum of pathologic findings? How do cryptic vascular malformations develop and enlarge over time? What is the proper treatment of symptomatic and asymptomatic lesions: surgery, radiation therapy, or observation? In this report, I will address these controversies, relying on the literature as well as on my own observations of these fascinating lesions.

## Terminology

In 1951, Margolis et al (3) brought attention to small vascular angiomas that resulted in acute fatal hematoma. In 1956, Crawford and Russell (4) first coined the term "cryptic" vascular malformation in reference to small, clinically "latent" vascular lesions, some of which were angiographically occult, that resulted in either apoplectic cerebral hemorrhage or signs of a growing mass lesion. These lesions were pathologically diverse, consisting of arteriovenous malformations (AVMs), venous hamartoma, and what would now be called cavernous angiomas. Subsequently, many investigators have reported series of angiographically occult vascular malformations (5–10). The terms *occult* and *cryptic* are now more or less synonymous, and generally refer to vascular malformations that have in common angiographic invisibility and a distinct appearance on MR images (11). Additionally, these lesions are more chronic in nature, unlike the small AVMs that are occasionally seen with acute hematoma. There is not wide agreement on terminology, as there is no consensus on the precise pathology or pathophysiology of

these lesions. Wilson (11) prefers the term *cryptic vascular malformation*, which seems appropriate until a more precise descriptive term is defined and agreed upon.

## Pathologic Classification of Vascular Malformations

In 1963, Russell and Rubinstein (12) classified vascular malformations of the central nervous system into four types: AVMs, cavernous angiomas, capillary telangiectases, and venous angiomas. Clinically, radiologically, and pathologically, these malformations form distinct categories; however, the coexistence of two or more of them within the same patient or even within the same lesion has been well documented (6, 13–17) (D. Rigamonti, P. C. Johnson, B. P. Drayer, R. F. Spetzler, "Cavernous Malformation and Capillary Telangiectases: Two Facets of the same Pathological Entity" (abstract), *J Neuropathol Exp Neurol* 1987;46:401). Several studies of resected cryptic vascular malformations have described combinations of telangiectasis, thrombosed AVM, cavernous malformation, and venous hamartoma (18, 19), suggesting that cryptic vascular malformations actually encompass a group of heterogeneous malformations. Others have suggested that cryptic vascular malformations are entirely venous in origin with a histologic appearance that reflects a spectrum within the same pathologic process. Therefore, it is useful to discuss the radiologic and pathologic criteria by which malformations are classified.

AVMs are composed of collections of arteries and veins that lack an intervening capillary bed, resulting in arteriovenous shunting. Typically, foci of brain tissue are present among the abnormal vessels. While the involved arteries may show alterations in the elastica, fibrosis of the media and thinning of their walls, the venous abnormalities, which are probably related to high pressure from arterial shunting, are most striking. These include deposits of elastic tissue and fibroblastic proliferation in the venous wall. Pseudoaneurysms may occur in approximately 10% of cases, a feature that increases the risk of hemorrhage. Thrombosis is a rare finding in AVMs, in contrast to cavernous angiomas (20). At angiography, AVMs are characterized by arteriovenous shunting at the nidus level. Typically, the AVM is fed by enlarged arteries and drained by early-filling enlarged veins, which have a high prevalence

Address reprint requests to William P. Dillon, MD, Department of Radiology, University of California, San Francisco, Room L-371, Box 0628, San Francisco, CA 94143.

**Index terms:** Arteries, cerebral; Veins, cerebral; Special reports

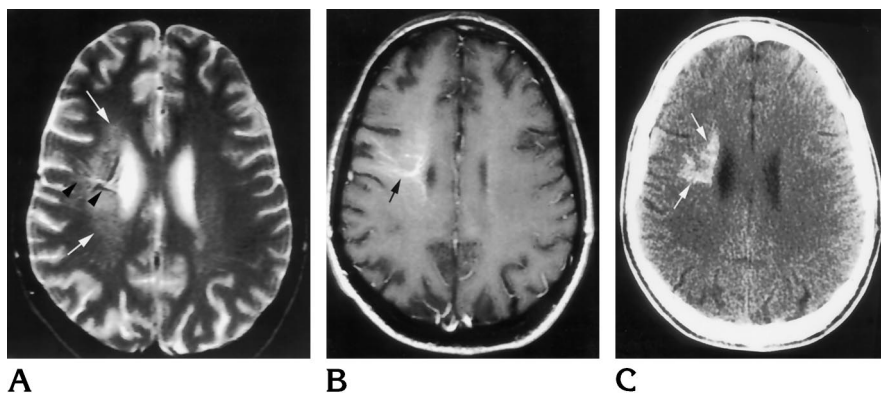
AJNR 18:1839–1846, Nov 1997 0195-6108/97/1810-1839 © American Society of Neuroradiology

Fig 1. Venous malformation with calcification in a 36-year-old patient with AIDS and slowly progressive left hemiparesis.

A, Axial T2-weighted MR image (2800/85/1 [repetition time/echo time/excitations]) shows a poorly defined area of increased signal intensity in the right centrum semiovale (arrows). Several linear vessels of high and low signal intensity typical of a venous malformation are present (arrowheads).

B, Contrast-enhanced T1-weighted image (600/15) reveals a typical venous malformation in the right frontal lobe. Multiple enhancing venous radicles coalesce to a more central vein (arrow), which drains toward the lateral cortex.

C, Axial noncontrast CT scan reveals calcification within the distribution of the venous malformation (arrows). Calcification and ischemia may occur in the region of the brain drained by a venous malformation. This is most likely caused by chronic venous obstructive disease.



of venous restriction at their confluence with the dural sinuses. The majority of AVMs are detected at angiography or MR imaging, unless they are so small as to go unnoticed, are compressed by acute hematoma, or are completely thrombosed (3, 4, 9, 21, 22–25). Spontaneous thrombosis of an AVM has been reported (26–31); however, this event must be exceedingly rare (20). The risk of hemorrhage from an AVM is approximately 2% per year, but is increased in patients with evidence of prior hemorrhage and by certain angioarchitectural features, such as the presence of a nidus pseudoaneurysm, obstruction of venous outflow, and venous drainage to the deep venous system (23, 25, 32).

Venous malformations (also referred to as venous angiomas or developmental venous anomalies) provide anomalous venous drainage of normal brain (33) and are thought to arise from a maldevelopment of fetal cortical venous drainage. They have a characteristic angiographic and MR appearance, which permits easy recognition (34, 35). They are quite common, seen in up to 3% of autopsies, and are typically benign, asymptomatic malformations (5, 36–38). Histologically, venous malformations usually appear as a cluster of normal veins with slightly thickened and hyalinized walls, separated by normal brain parenchyma (39, 40). The small venous radicles empty into a larger central vein, which in turn usually empties into a cortical vein or dural sinus. Venous malformations range from holohemispheric to microscopic in size. Radiologically, they are best appreciated on contrast-enhanced MR images (34, 35, 41–43) on which they have a typical “Medusa head” appearance. Calcification and ischemic changes are rare, but recognized (Fig 1). Senegor et al (40) emphasized the importance of venous malformations to normal venous drainage of the brain and the danger of resecting a large venous malformation, a point also emphasized by Rigamonti and Spetzler (16).

Capillary telangiectases are compact vascular malformations composed of small-diameter vessels, consistent

with capillaries or small venules, separated by intervening brain parenchyma. They are most commonly found in the pons and are usually asymptomatic, although rare reports of acute hemorrhage exist. While occult at angiography, capillary telangiectases can now be identified on contrast-enhanced and gradient-echo MR images (44). Capillary telangiectases differ from venous malformations mainly in their compact nature and the size of the anomalous vessels.

A cavernous angioma (also referred to as a cavernous malformation) is a vascular lesion composed of a dense mass of thin, single-layered blood vessels of varying size that lack the microscopic features of arteries or veins (20). Thrombi of varying age are characteristic and are present within many of the vessels. Hemosiderin, calcification, and surrounding gliosis typify the margins of the lesions. While intervening brain tissue and arteries are not typical pathologic features described in cavernous angiomas, it is not uncommon to see areas of neuropil within the margin of the nidus as well as arterial-like structures at their margins or even within the nidus (13, 14, 16, 20) (A. Bollen, personal communication, 1997) (Rigamonti et al, “Cavernous...”).

An association between venous malformation and cavernous angioma has been recognized by many authors (16, 46–53) (W. Dillon, G. Hieshima, V. Halbach, C. Dowd, “A New Observation on the Association of Venous Angioma, Hemorrhage and ‘Cryptic Vascular Malformations,’” presented at the annual meeting of the American Association of Neuroradiology, Washington, DC, June 1991). Prior to MR imaging, this relationship was assumed to be simply an association of two separate vascular malformations, occurring in 8% of the cases of venous malformation reported by Rigamonti and Spetzler (16). However, contrast-enhanced MR images have clearly shown that cavernous angiomas frequently appear to arise at the distal radicles of venous malformations (Dillon et al, “A New Observation...”).

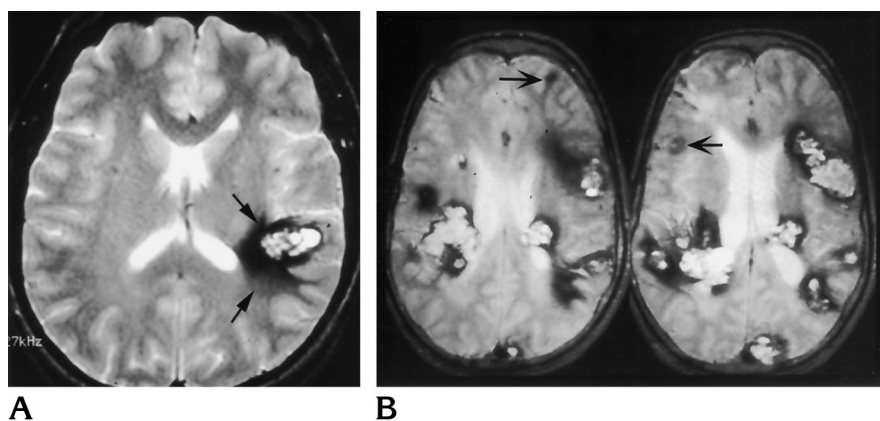


Fig 2. Classic MR appearance of solitary and familial cryptic vascular malformations.

A, Axial T2-weighted image (2800/85/1) in a 35-year-old woman with seizures reveals the typical features of a solitary cryptic vascular malformation in the left frontal lobe. The heterogeneous mass has a rim of low signal intensity, consistent with hemosiderin (arrows), that surrounds a central zone containing material of high and low signal intensity, consistent with thrombus and old blood products. Note that the lesion does not generate vasogenic edema, as it is a slowly progressive process.

B, Multiple cavernous malformations in a Hispanic patient with seizures. Contiguous axial T2-weighted MR images (2800/85/1) reveal multiple cavernous angiomas distributed throughout the white matter, most of which exhibit similar features to the lesion in A. Note, however, that there are also small foci of low-intensity hemosiderin that lack central areas of high signal intensity (arrows). These most likely represent the early developing lesions resulting from petechial hemorrhage. The syndrome of multiple cavernous angiomas has been associated with a mutation of chromosome 7q.

## Radiologic Appearance of Cryptic Vascular Malformations

Before computed tomography (CT), the diagnosis of cryptic vascular malformation was usually made at surgery or autopsy. With the advent of CT it became apparent that cryptic vascular malformations were not simply small AVMs that had hemorrhaged acutely but instead often consisted of chronic, expanding vascular masses that progressively enlarged, were often calcified, and were commonly mistaken for low-grade cerebral neoplasms (54).

MR imaging ushered in a new era in the diagnosis of cryptic vascular malformations (55, 56). They are now easily recognized on MR images and no longer are "occult" to presurgical diagnostic techniques. On high-field MR studies, these malformations typically consist of heterogeneous signal intensity representing accumulations of blood products of varying age. Surrounding the mass is a rim of hemosiderin deposition of varying thickness, represented as reduced signal on T2-weighted sequences (Figs 2–4). This MR appearance, while occasionally simulated by hemorrhagic metastases, such as melanoma (57), is believed by most, myself included, to be diagnostic of cryptic vascular malformation and, specifically, of cavernous angioma (56, 58). Indeed, there are no reports of these lesions without associated hemorrhage, unlike the other categories of vascular malformations. Perhaps these lesions are not actually malformations but rather a response of the brain to an insult.

## Pathology of Cryptic Vascular Malformations

The pathologic descriptions of cryptic vascular malformation have been confusing and, in my opinion, frankly misleading. Many of these reports have attempted to classify this entity without radiologic correlation, leading to a confusing array of terminology. Mixtures of two or more vascular malformations within the same histologic speci-

men, including telangiectasis and cavernous malformation, AVM and venous malformation, and AVM and telangiectasis, have been identified by several authors (13, 17, 59–61). Lobato et al (19) reviewed the literature in 1988 and found 44% of cryptic vascular malformations were pathologically confirmed AVMs, 31% were cavernous angiomas, 10% were venous angiomas, 4% were capillary telangiectases, and 11% were "mixed" or unclassified angiomas. Certain histologic features were common to all lesions, such as a preponderance of small-caliber, often thrombosed vessels, and microhemorrhages in surrounding brain parenchyma. Wilson (11) reported 73 cases of cryptic vascular malformation, which he operated on. He classified these lesions as cavernous angiomas (10%), "cryptic vascular malformation with arterial components or cryptic AVM" (47%), and "unspecified cryptic vascular malformation without arterial components" (40%). It is worthy to note that the pathologic interpretation occurred without the benefit of MR or angiographic correlation. Tomlinson et al (20), in a recent review of the MR appearance and histopathology of 25 cryptic vascular malformations, found that in 24 of the lesions the vascular channels were histologically cavernous in nature; three showed a purely compact or cavernous pattern, 20 a mixed cavernous and racemose pattern, and one a purely racemose pattern. These authors concluded that histologically "cavernous lesions were the commonest form of occult vascular malformation" and suggested that the clinical growth of cavernous angiomas may have its basis in intraluminal thrombosis and subsequent recanalization. They also emphasized that most of the cavernous angiomas contained thrombosis, a feature atypically seen in AVMs. How can we account for these conflicting reports and interpretations?

It seems clear to me that the classically accepted pathologic criteria differentiating cavernous angiomas from AVMs and telangiectases are neither as precise nor as



Fig 3. A 28-year-old patient with progressive cranial neuropathy involving the right sixth and seventh nerves.

A, Preoperative T2-weighted MR image (2800/85/1) shows the typical features of a cryptic vascular malformation located with the dorsal aspect of the pons. The lesion exhibits mass effect upon the fourth ventricle (*white arrows*), a thick rim of hemosiderin (*black arrows*), and areas of high signal intensity within the center, consistent with blood products.

B, Preoperative T1-weighted (600/15) contrast-enhanced MR image shows the high-signal-intensity cryptic vascular malformation. No associated veins are identified.

C, Contrast-enhanced T1-weighted image (600/15) after resection of the cryptic vascular malformation. An underlying venous malformation, which had been compressed by the cryptic vascular malformation, is now visible within the postoperative site (*arrow*). This was presumably compressed by the cryptic vascular malformation, which accounts for it being occult on the preoperative MR studies.

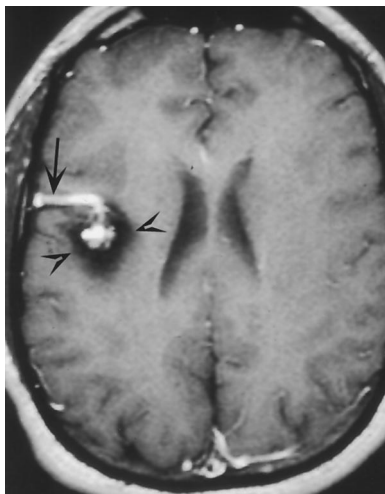
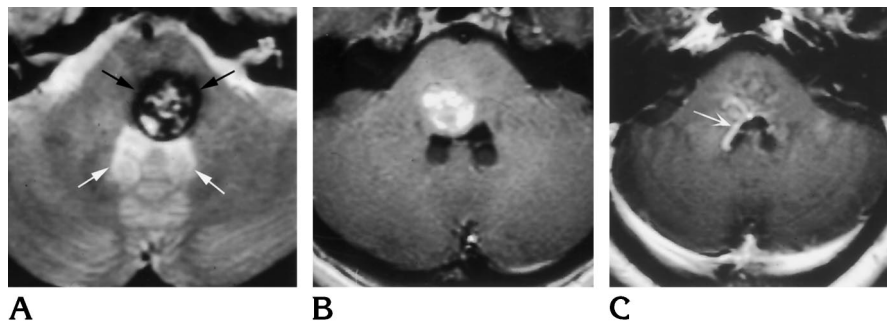


Fig 4. Contrast-enhanced T1-weighted MR image (600/15) in a 24-year-old man with seizures shows a cryptic vascular malformation in the right frontal lobe (*arrowheads*). A venous malformation (*arrow*) intimately contacts the cryptic vascular malformation. On other MR images, the venous malformation was noted to extend along the cortical surface and empty into the sagittal sinus. Angiography revealed a high-grade stenosis at the insertion of the venous malformation into the sagittal sinus (not shown).

accurate as they should be. I suspect that many so-called thrombosed AVMs might in fact actually be cavernous angiomas of venous origin that have associated telangiectases or arteriovenous shunts, the presence of which has led to the classification of these lesions as AVMs. In their defense, pathologists are at somewhat of a disadvantage in attempting to differentiate among these lesions, as they are received as incomplete fragments of tissue and usually lack the benefit of radiologic correlative studies. This, I believe, is one of the primary reasons for the inconsistencies that have characterized pathologic reports of cryptic vascular malformations in the literature.

### Pathogenesis of Cryptic Vascular Malformations

The pathogenesis of cryptic vascular malformation is still unknown. In some families, especially those of Hispanic origin, the occurrence of multiple cavernous angiomas in close relatives indicates a genetic component (62, 63) (Fig 2B). Many of these families appear to have a common ancestral autosomal dominant "founder" mutation on the 7q chromosome, while in others a different genetic defect may be present (64–67). Unfortunately, we do not know whether all cavernous angiomas arise as a result of similar genetic mutations. They may simply share a common initial pathologic event, such as the presence of microscopic venous malformation, venous hypertension, or petechial hemorrhage, which sets in motion a process culminating in a cavernous angioma.

Wilson (11) has proposed that petechial hemorrhage leads to the development of cryptic vascular malformation. While this theory has yet to be proved, it is an attractive one, as the initial MR appearance of the smallest visible cavernous angioma is that of a small hypointense focus of hemosiderin, without evidence of acute hemorrhage. In 1991, we presented a hypothesis suggesting that the development of cryptic vascular malformation was related to elevated venous pressure, occurring within a venous malformation, a telangiectasis, or a minute vascular malformation consequent to venous outflow obstruction (Dillon et al, "A New Observation..."). I believe this concept explains the pathologic diversity that has been reported, as well as the coexistence of multiple vascular malformations in a single specimen. Evidence to support this hypothesis is accumulating.

It has been pointed out by Rigamonti and coworkers (16) (Rigamonti et al, "Cavernous...") that telangiectases as well as venous malformations often coexist with cavernous angiomas. In a review of a series of over 80 consecutive cryptic vascular malformations evaluated at our institution, contrast-enhanced MR imaging revealed that 30% of solitary cryptic vascular malformations were inti-

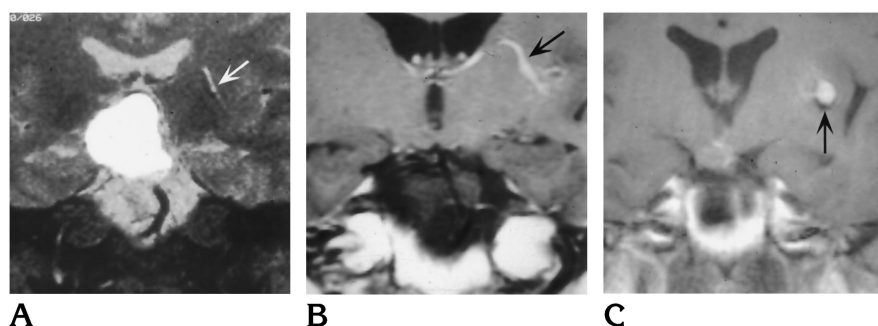


Fig 5. Development of a cavernous malformation from a preexisting venous malformation in a 24-year-old man with a craniopharyngioma who was followed up with multiple MR examinations.

A, Coronal T2-weighted image (2800/85/1) obtained in 1988 shows a high-intensity cystic craniopharyngioma. A venous malformation is present adjacent to the left frontal horn of the lateral ventricle (arrow). No associated blood products or cryptic vascular malformations are present.

B, T1-weighted contrast-enhanced im-

age (600/15) obtained in 1990 after resection of the craniopharyngioma shows a linear enhancing vessel typical of a venous malformation in the left frontal region (arrow). Again, no blood products were seen.

C, T1-weighted contrast-enhanced image (600/15) obtained in 1991 shows the development of a small hemorrhage (arrow) surrounded by a low-density rim of hemosiderin. This was asymptomatic and was thought to be consistent with a cryptic vascular malformation developing at the site of the distal radicles of the preexisting venous malformation.

mately associated with a venous malformation or draining vein, while none of the patients with familial cavernous angiomas or radiation-induced telangiectases had visible draining vessels or a nearby venous malformation (D. Shibata and W. P. Dillon, unpublished data, 1997) (Fig 4). Most cryptic vascular malformations form at a distal radicle of a venous malformation. In one patient, a venous malformation became visible only after an overlying cavernous angioma was resected, perhaps explaining why some of the cavernous angiomas may not have had a venous malformation visible on preoperative MR studies (Fig 3). In one case, the development of a cryptic vascular malformation was documented at a distal radicle of a preexisting venous malformation (Fig 5). In a review of venous malformations associated with cryptic vascular malformations, we found that most venous malformations showed direct or indirect evidence of obstruction of venous outflow from the venous malformation, which was visible only at angiography (Dillon et al, "A New Observation..."). In one patient who had surgery at our institution, elevated venous pressure was documented within a venous malformation that had repeatedly hemorrhaged (Fig 6). Contrast-enhanced MR images have also shown that midbrain and tectal cryptic vascular malformations are usually the result of small preexisting venous malformations of the midbrain or cerebellum (52).

Elevated venous pressure within the territory of a venous malformation may provoke a cascade of events, including ischemia, petechial hemorrhage, and the release of angiogenic factors that may be responsible for the recruitment of new vessels (68). These new vessels may be subjected to additional unknown factors, which ultimately transform them into the arterial vessels noted by pathologists in resected cryptic vascular malformations. Arteriovenous shunting may further increase venous pressure and lead to recurrent small hemorrhages characteristic of cavernous angiomas.

Venous hypertension may also explain the rare occurrences of "mixed" vascular malformations of the brain, such as those characterized by arterial shunting into a

venous malformation visible at angiography (13). While it is possible that two distinct vascular malformations intimately coexist at the same site in the same patient, I believe that elevation of venous pressure within a preexisting venous malformation or capillary telangiectasis promotes arteriovenous shunting at the precapillary level, leading to the apparent angiographic appearance of an AVM. I have encountered three of these cases, and, in each, careful examination of the angiogram and/or MR angiogram has not demonstrated a discrete nidus but rather arteriovenous shunting at the level of several distal radicles of the venous malformation. All venous malformations also had severe venous stenosis of their main draining efferent vessel(s) (Fig 7) and stasis of venous blood within the malformation, consistent with severe outflow restrictive disease. A similar process may also occur in dural sinus fistulas, in which elevated venous pressure within a sinus may stimulate angiogenic factors, allowing arteriovenous shunts to proliferate within the wall of the sinus (69–71).

Why is it that many of the solitary cryptic vascular malformations are not associated with a visible venous malformation at MR imaging or angiography? Small, microscopic venous vascular malformations have been reported by Courville (33). These lesions were of venous origin and showed a reduction of associated capillary networks and focal aneurysmal dilatation occurring at the end of vessels, which he hypothesized were caused by venous obstruction. Perhaps both visible and microscopic venous malformations are responsible for the development of cavernous angioma.

## Treatment Options for Cavernous Angioma

The options for treatment of cavernous angiomas depend in large part on the natural course of the lesion, as well as its location and surgical accessibility. The latter is influenced by the skill of the surgeon and the position of the lesion relative to eloquent areas of the brain. Improvements in stereotactic techniques have made many previ-

Fig 6. A 51-year-old woman with recurrent right frontal hemorrhages.

A, Noncontrast CT scan shows a right frontal hemorrhage (arrows).

B, Two right-sided oblique projections from the middle (right) and delayed (left) venous phase of right internal carotid digital subtraction angiography show a typical venous malformation that empties into the sagittal sinus (arrowheads). A high-grade stenosis is noted at the site of penetration into the sagittal sinus (arrow). Note also the delayed opacification of the venous malformation relative to the sagittal sinus and other surrounding veins, which implies restriction of flow and increased pressure within the venous malformation. Intraoperatively, a 15-mm pressure gradient was documented across the insertion of the venous malformation. No underlying cryptic vascular malformation was found at surgery.

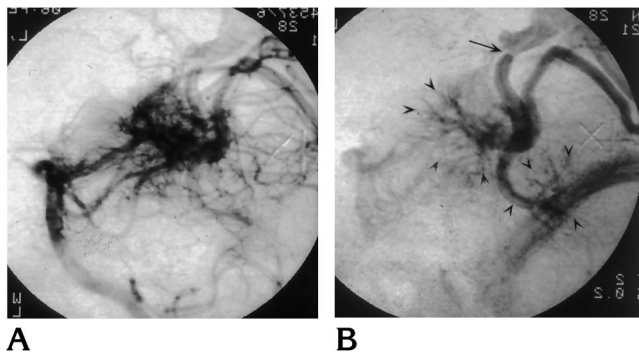
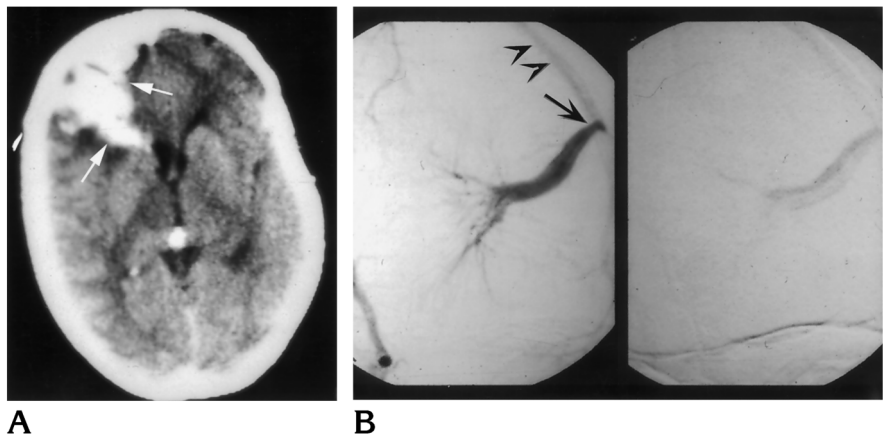


Fig 7. Arterialized venous malformation in a 30-year-old man with a hemorrhage within the occipital lobe. Vertebral arteriogram, lateral projection, during the late arterial (A) and venous (B) phase. Note the accumulation of contrast material within two venous malformations (arrowheads). Arteriovenous shunting is noted at the distal radicles of the more superior of the two venous malformations, which exhibits a high-grade stenosis along its outflow tract (arrow). No shunting is visible into the other inferior venous malformation. We believe that the arteriovenous shunting developed at the distal radicles of the venous malformation, which had obstructed outflow and presumably increased intraluminal pressure. The shunting does not reflect a true arteriovenous malformation in the classic sense, but has probably developed in response to elevated pressure within the venous malformation.

ously unresectable lesions accessible to the surgeon. The natural course of untreated cavernous malformations has been reviewed by several authors. The risk of hemorrhage from a cryptic vascular malformation is between 0.25% and 0.7% per year (58, 72). This appears to be more common in lesions located within the posterior fossa. Kondziolka et al (73) found that in patients with a prior clinical hemorrhage, the annual rate of rehemorrhage rose to 4.5%.

Therapeutic strategies include observation of patients with asymptomatic or inaccessible lesions, surgical excision of symptomatic and accessible lesions, and radiosurgery for progressively symptomatic but surgically inacces-

sible lesions. Surgical resection is generally recommended for cryptic vascular malformations presenting with symptomatic hemorrhage and located in an accessible and noneloquent area of the brain (11, 16, 74). If the lesion is surgically inaccessible or is asymptomatic, the treatment options are less clear. Conservative observation is one option (74). Others have documented a reduction in the risk of recurrent hemorrhage from cavernous angiomas after stereotactic radiation (75–77). However, these results have been contradicted by Seo et al (78). Therefore, until sufficient follow-up of patients is available, primary treatment by radiation therapy for cryptic vascular malformations may not gain widespread acceptance.

## Conclusions

Most, if not all, cryptic vascular malformations are probably cavernous angiomas. Venous hypertension may play a key role in the development of sporadic cavernous angiomas, which probably arise from an acquired disease process of venous origin rather than a true developmental malformation of blood vessels (Dillon et al, "A New Observation...") (48, 79). Observations supporting this theory include their close association with venous malformations, the development of cavernous angiomas from preexisting venous malformation, and the evidence of increased pressure within venous malformations. I believe there is ample evidence to suggest that these factors are important in the development of many cryptic vascular malformations.

The controversial questions posed at the outset of this discussion remain unanswered. Genetic clues revealed by examination of familial cavernous malformations give hope that the basic defect leading to at least some cavernous angiomas will soon be uncovered. The role of petechial hemorrhage and elevation of venous pressure within large and small venous malformations should be explored. Treatment options that address the initial process of venous stenosis, and subsequent angiogenesis, could in the future yield therapeutic successes.



## Acknowledgments

My thanks go to Andrew Bollen and Nancy Fischbein for their diligent manuscript review and to Molly Tellis for manuscript and figure preparation.

## References

- Schneider RC, Liss L. Cavernous hemangiomas of the cerebral hemispheres. *J Neurosurg* 1958;15:392-399
- Penfield W, Ward A. Calcifying epileptogenic lesion: hemangioma calcificans. Report of 9 cases. *Arch Neurol Psychiatry* 1948;60:20-36
- Margolis G, Odom GL, Woodhall B, Bloor BM. The role of small angiomatous malformations in the production of intracerebral hematomas. *J Neurosurg* 1951;8:564-575
- Crawford J, Russell D. Cryptic arteriovenous and venous hamartomas of the brain. *J Neurol Neurosurg Psychiatry* 1956;19:1-11
- McCormick W, Hardman J, Boulter T. Vascular malformations ("angiomas") of the brain, with special reference to those occurring in the posterior fossa. *J Neurosurg* 1968;28:241-251
- Roberson GH, Kase CS, Wolpow ER. Telangiectases and cavernous angiomas of the brain stem: "cryptic" vascular malformations. *Neuroradiology* 1974;8:83-89
- Kamrin RB, Buschsbaum HW. Large vascular malformation of the brain not visualized by serial angiography. *Arch Neurol* 1965;13:413-420
- Kramer R, Wing S. Computed tomography of angiographically occult cerebral vascular malformations. *Radiology* 1977;123:649-652
- Ogilvy C, Heros R, Ojemann R, New P. Angiographically occult arteriovenous malformations. *J Neurosurg* 1988;69:350-355
- Bitoh S, Hasegawa H, Fujiwara M, Sakurai M. Angiographically occult vascular malformations causing intracranial hemorrhage. *Surg Neurol* 1982;17:35-42
- Wilson CB. Cryptic vascular malformations. *Clin Neurosurg* 1992;38:49-84
- Russell DS, Rubinstein LJ. *Pathology of the Nervous System*. 2nd ed. New York, NY: Williams & Wilkins; 1963:345
- Awad I, Robinson J, Mohanty S, Estes M. Mixed vascular malformations of the brain: clinical and pathogenetic considerations. *Neurosurgery* 1993;33:179-188
- Rigamonti D, Johnson PC, Spetzler RF, Hadley MN, Drayer BP. Cavernous malformations and capillary telangiectasia: a spectrum within a single pathological entity. *Neurosurgery* 1991;28:60-64
- Robinson J, Awad I, Masaryk T, Estes M. Pathologic heterogeneity of angiographically occult vascular malformations of the brain. *Neurosurgery* 1993;33:547-554
- Rigamonti D, Spetzler R. The association of venous and cavernous malformations: report of four cases and discussion of the pathophysiological, diagnostic, and therapeutic implications. *Acta Neurochir (Wien)* 1988;92:100-105
- Chang SD, Steinberg GK, Rosario M, Crowley RS, Hevner RF. Mixed arteriovenous and capillary telangiectasia: a rare subset of mixed vascular malformations. *J Neurosurg* 1997;86:699-703
- Russell DS, Rubinstein LJ. *Pathology of Tumours of the Nervous System*. 4th ed. Baltimore, Md: Williams & Wilkins; 1977:116-145
- Lobato RD, Perez C, Rivas JJ, Cordobes F. Clinical, radiological, and pathological spectrum of angiographically occult intracranial vascular malformations: analysis of 21 cases and review of the literature. *J Neurosurg* 1988;68:518-531
- Tomlinson FH, Houser OW, Scheithauer BW, Sundt TM Jr, Okazaki H, Parisi JE. Angiographically occult vascular malformations: a correlative study of features on magnetic resonance imaging and histologic examination [and following discussion]. *Neurosurgery* 1994;34:792-800
- Ebeling JD, Tranner BI, Davis KA, Kindt GW, DeMasters BK. Thrombosed arteriovenous malformations: a type of occult vascular malformation. *Neurosurgery* 1988;23:605-610
- McCormick WF. The pathology of vascular ("arteriovenous") malformations. *J Neurosurg* 1966;24:807-816
- Miyasaka Y, Kurata A, Tokiwa K, Tanaka R, Yada K, Ohwada T. Draining vein pressure increases and hemorrhage in patients with arteriovenous malformation. *Stroke* 1994;25:504-507
- Steinmeier R, Schramm J, Muller HG, Fahlbusch R. Evaluation of prognostic factors in cerebral arteriovenous malformations. *Neurosurgery* 1989;24:193-200
- Willinsky R, Lasjaunias P, Terbrugge K, Pruvost P. Brain arteriovenous malformations: analysis of the angio-architecture in relationship to hemorrhage (based on 152 patients explored and/or treated at the hospital de Bicetre between 1981 and 1986). *J Neuro-radiol* 1988;15:225-237
- Eisenman JI, Alekoubides A, Pribram H. Spontaneous thrombosis of vascular malformations of the brain. *Acta Radiol* 1972;13:77-85
- Kader A, Goodrich JT, Sonstein WJ, Stein BM, Carmel PW, Michelsen WJ. Recurrent cerebral arteriovenous malformations after negative postoperative angiograms. *J Neurosurg* 1996;85:14-18
- Watanabe H, Nakamura H, Matsuo Y, et al. Spontaneous regression of cerebral arterio-venous malformation following major artery thrombosis proximal to dominant feeders: a case report. *No Shinkei Geka* 1995;23:371-376
- Mizutani T, Tanaka H, Aruga T. Total recanalization of a spontaneously thrombosed arteriovenous malformation: case report. *J Neurosurg* 1995;82:506-508
- Guazzo EP, Xuereb JH. Spontaneous thrombosis of an arteriovenous malformation. *J Neurol Neurosurg Psychiatry* 1994;57:1410-1412
- Hamada J, Yonekawa Y. Spontaneous disappearance of a cerebral arteriovenous malformation: case report. *Neurosurgery* 1994;34:171-173
- Norbash AM, Marks MP, Lane B. Correlation of pressure measurements with angiographic characteristics predisposing to hemorrhage and steal in cerebral arteriovenous malformations. *AJNR Am J Neuroradiol* 1994;15:809-813
- Courville CB. Morphology of small vascular malformations of the brain, with particular reference to the mechanism of their drainage. *J Neuropathol Exp Neurol* 1963;22:274-284
- Wilms G, Marchal G, Van Hecke P, Van Fraeyenhoven L, Decrop E, Baert AL. Cerebral venous angiomas: MR imaging at 1.5 Tesla. *Neuroradiology* 1990;32:81-85
- Wilms G, Demaerel P, Marchal G, Baert AL, Plets C. Gadolinium-enhanced MR imaging of cerebral venous angiomas with emphasis on their drainage. *J Comput Assist Tomogr* 1991;15:199-206
- Huang YP, Robbins A, Patel SC, Chaundhary M. Cerebral venous malformations and a new classification of cerebral vascular malformations. In: Kapp JP, Schmidek HH, eds. *The Cerebral Venous System and Its Disorders*. New York, NY: Grune & Stratton; 1984:373-474
- Fujii K, Matsushima T, Inamura T, Fukui M. Natural history and choice of treatment in forty patients with medullary venous malformation (MVM). *Neurosurg Rev* 1992;15:13-20
- Garner TB, Del Curling O Jr, Kelly DL Jr, Laster DW. The natural history of intracranial venous angiomas. *J Neurosurg* 1991;75:715-722



39. Scotti LN, Goldman RL, Rao GR, Heinz ER. Cerebral venous angioma. *Neuroradiology* 1975;9:125-128
40. Senegor M, Dohrmann GJ, Wollmann RL. Venous angiomas of the posterior fossa should be considered as anomalous venous drainage. *Surg Neurol* 1983;19:26-32
41. Cammarata C, Han JS, Haaga JR, Alfidi RJ, Kaufman B. Cerebral venous angiomas imaged by MR. *Radiology* 1985;155:639-643
42. Toro VE, Geyer CA, Sherman JL, Parisi JE, Brantley MJ. Cerebral venous angiomas: MR findings. *J Comput Assist Tomogr* 1988;12:935-940
43. Fontaine S, de la Sayette V, Gianfelice D, Melanson D, Ethier R. CT, MRI, and angiography of venous angiomas: a comparative study. *Can Assoc Radiol J* 1987;38:259-263
44. Barr RM, Dillon WP, Wilson CB. Slow-flow vascular malformations of the pons: capillary telangiectasias? *AJNR Am J Neuroradiol* 1996;17:71-78
45. Deleted in proof
46. Takamiya Y, Takayama H, Kobayashi K, Mine T, Suzuki K. Familial occurrence of multiple vascular malformations of the brain. *Neurol Med Chir (Tokyo)* 1984;24:271-277
47. Ferrito G, Scazzari F, Prosetti D, Nenci R, Quilici N, Marcacci G. Venous angioma associated with cavernous angioma: presentation of three cases. *Riv Neurol* 1990;60:191-193
48. Lasjaunias P, Terbrugge K, Rodesch G, et al. True and false cerebral venous malformations: venous pseudo-angiomas and cavernous hemangiomas. *Neurochirurgie* 1989;35:132-139
49. Yamasaki T, Handa H, Yamashita J, Moritake K, Nagasawa S. Intracranial cavernous angioma angiographically mimicking venous angioma in an infant. *Surg Neurol* 1984;22:461-466
50. Sasaki O, Tanaka R, Koike T, Koide A, Koizumi T, Ogawa H. Excision of cavernous angioma with preservation of coexisting venous angioma: case report. *J Neurosurg* 1991;75:461-464
51. Miyagi Y, Mannoji H, Akaboshi K, Morioka T, Fukui M. Intraventricular cavernous malformation associated with medullary venous malformation [and following discussion]. *Neurosurgery* 1993;32:461-464
52. Latchaw RE, Truwit CL, Heros RC. Venous angioma, cavernous angioma, and hemorrhage. *AJNR Am J Neuroradiol* 1994;15:1255-1257
53. Wilms G, Bleus E, Demaerel P, et al. Simultaneous occurrence of developmental venous anomalies and cavernous angiomas. *AJNR Am J Neuroradiol* 1994;15:1247-1254
54. Pozzati E, Giuliani G, Nuzzo G, Poppi M. The growth of cerebral cavernous angiomas. *Neurosurgery* 1989;25:92-97
55. Gomori J, Grossman R, Goldberg H, et al. Occult cerebral vascular malformations: high-field MR imaging. *Radiology* 1986;158:707-713
56. Rigamonti D, Drayer BP, Johnson PC, Hadley MN, Zabramski J, Spetzler RF. The MRI appearance of cavernous malformations (angiomas). *J Neurosurg* 1987;67:518-524
57. Sze G, Krol G, Olsen WL, et al. Hemorrhagic neoplasms: MR mimics of occult vascular malformations. *AJR Am J Roentgenol* 1987;149:1223-1230
58. Robinson J, Awad IA, Little J. Natural history of the cavernous angioma. *J Neurosurg* 1991;75:709-714
59. Herata Y, Matsukado Y, Nagahiro S, Kuratsu J. Intracerebral venous angioma with arterial blood supply: a mixed angioma. *Surg Neurol* 1986;25:227-232
60. Itoyama Y, Kitano I, Fujioka S, et al. Mixed angioma of the brain: report of two cases. *No Shinkei Geka* 1994;22:465-469
61. Tanohata K, Nagano N, Aoki S, et al. Multiple cerebral venous angiomas associated with mixed pial and dural arteriovenous malformation. *Rinsho Hoshasen* 1989;34:731-734
62. Haymen LA, Evans RA, Ferrel RE, et al. Familial cavernous angiomas: natural history and genetic study over a 5 year period. *Am J Med Genet* 1982;11:147-160
63. Kattapong VJ, Hart BL, Davis LE. Familial cerebral cavernous angiomas: clinical and radiologic studies. *Neurology* 1995;45:492-497
64. Gunel M, Awad IA, Finberg K, et al. A founder mutation as a cause of cerebral cavernous malformation in Hispanic Americans. *N Engl J Med* 1996;334:946-951
65. Gil-Nagel A, Dubovsky J, Wilcox KJ, et al. Familial cerebral cavernous angioma: a gene localized to a 15-cM interval on chromosome 7q. *Ann Neurol* 1996;39:807-810
66. Polymeropoulos MH, Hurko O, Hsu F, et al. Linkage of the locus for cerebral cavernous hemangiomas to human chromosome 7q in four families of Mexican-American descent. *Neurology* 1997;48:752-757
67. Gunel M, Awad IA, Finberg K, et al. Genetic heterogeneity of inherited cerebral cavernous malformation. *Neurosurgery* 1996;38:1265-1271
68. Rothbart D, Awad IA, Lee J, Kim J, Harbaugh R, Criscuolo GR. Expression of angiogenic factors and structural proteins in central nervous system vascular malformations. *Neurosurgery* 1996;38:915-925
69. Herman JM, Spetzler RF, Bederson JB, Kurbat JM, Zabramski JM. Genesis of a dural arteriovenous malformation in a rat model. *J Neurosurg* 1995;83:539-545
70. Terada T, Higashida RT, Halbach VV, et al. Development of acquired arteriovenous fistulas in rats due to venous hypertension. *J Neurosurg* 1994;80:884-889
71. Hamada Y, Goto K, Inoue T, et al. Histopathological aspects of dural arteriovenous fistulas in the transverse-sigmoid sinus region in nine patients. *Neurosurgery* 1997;40:452-457
72. Curling O, Kelly D, Elster A, Craven T. An analysis of the natural history of cavernous angiomas. *J Neurosurg* 1991;75:702-708
73. Kondziolka D, Lunsford LD, Kestle JR. The natural history of cerebral cavernous malformations. *J Neurosurg* 1995;83:820-824
74. Ojemann RG, Crowell RM, Ogilvy CS. Management of cranial and spinal cavernous angiomas (honored guest lecture). *Clin Neurosurg* 1993;40:98-123
75. Kondziolka D, Lunsford LD, Flickinger JC, Kestle JR. Reduction of hemorrhage risk after stereotactic radiosurgery for cavernous malformations [see comments]. *J Neurosurg* 1995;83:825-831
76. Kida Y, Kobayashi T, Tanaka T. Treatment of symptomatic AOVMS with radiosurgery. *Acta Neurochir Suppl* 1995;63:68-72
77. Maraire JN, Awad IA. Intracranial cavernous malformations: lesion behavior and management strategies. *Neurosurgery* 1995;37:591-605
78. Seo Y, Fukuoka S, Takanashi M, et al. Gamma knife surgery for angiographically occult vascular malformation. *Stereotact Funct Neurosurg* 1995;64(Suppl 1):98-109
79. Ciricillo SF, Dillon WP, Fink ME, Edwards MS. Progression of multiple cryptic vascular malformations associated with anomalous venous drainage: case report. *J Neurosurg* 1994;81:477-481