



Discover Generics

Cost-Effective CT & MRI Contrast Agents



WATCH VIDEO

AJNR

Infarcted spinal schwannoma: an unusual MR finding.

D A Shrier, A Rubio, Y Numaguchi and J M Powers

AJNR Am J Neuroradiol 1996, 17 (8) 1566-1568

<http://www.ajnr.org/content/17/8/1566>

This information is current as
of June 17, 2025.

Infarcted Spinal Schwannoma: An Unusual MR Finding

David A. Shrier, Anna Rubio, Yuji Numaguchi, and James M. Powers

Summary: We present a case of infarcted schwannoma of the thoracic spine in a patient with acute cord compression. MR images did not enhance after contrast administration, which is highly atypical for schwannoma, but was in keeping with the pathologic findings in this case.

Index terms: Neuroma; Spinal cord, compression; Spine, neoplasms

Schwannomas are common intradural extramedullary spinal tumors (1) that typically show homogeneous or heterogeneous enhancement and that are variably hyperintense on T2-weighted magnetic resonance (MR) images (2, 3). We report a case of acute cord compression caused by a nonenhancing, infarcted schwannoma of the thoracic spine.

Case Report

A 37-year-old man had a 3-day history of fever, chills, left-sided pleuritic chest pain, left-sided numbness, and bilateral weakness of the lower extremities. On initial neurologic examination, strength in the patient's lower limbs was graded 4 on a scale of 5. Sensation was markedly decreased to light touch and pinprick below the level of T-4.

A complete emergency MR examination of the spine, performed with and without contrast material, revealed multiple intradural, extramedullary masses in the cervical, thoracic, and lumbosacral regions. The largest lesion was at the T3-4 level anteriorly, which caused significant cord compression. This lesion showed heterogeneous signal intensity on T2-weighted images and did not show significant contrast enhancement (Fig 1A-C). The other lesions were uniformly isointense with the cord on T2-weighted images and enhanced homogeneously (Fig 1D).

Acute loss of lower-extremity motor function developed 6 hours after admission and the patient was operated on for decompression of the T3-4 tumor. A T3-7 bilateral laminectomy was performed with removal of the intradural spinal mass.

The cylindrical, 1.8 × 1.2-cm tumor was serially sectioned in a transverse plane. Cross sections revealed congested soft tissue, and the proximal end of a nerve was seen to be compressed by the tumor mass. Microscopically, approximately 60% of the sections showed acute infarction, with edema, coagulation necrosis, arterial thrombosis, and marked venous congestion (Fig 1D and E). Histologically, 80% to 85% of the tumor was composed of compacted spindle cells in a reticulin-rich stroma with an Antoni type A pattern, and the remaining 15% to 20% was formed of a more loose, hypocellular, reticulin-poor Antoni B area. Final pathologic diagnosis was schwannoma with acute infarction.

Discussion

Nerve sheath tumors and meningiomas are the most common intradural extramedullary neoplasms (2, 4). The two main types of nerve sheath tumors found in the spine are schwannomas and neurofibromas. Both tumors are composed primarily of Schwann cells (5). Microscopically, schwannomas may be composed of densely packed spindle cells (Antoni type A) or more loosely textured stroma (Antoni type B). The tumors may undergo cystic degeneration, hemorrhage, or xanthomatous changes (3, 5). Multiple schwannomas are commonly found in patients with neurofibromatosis type II (6).

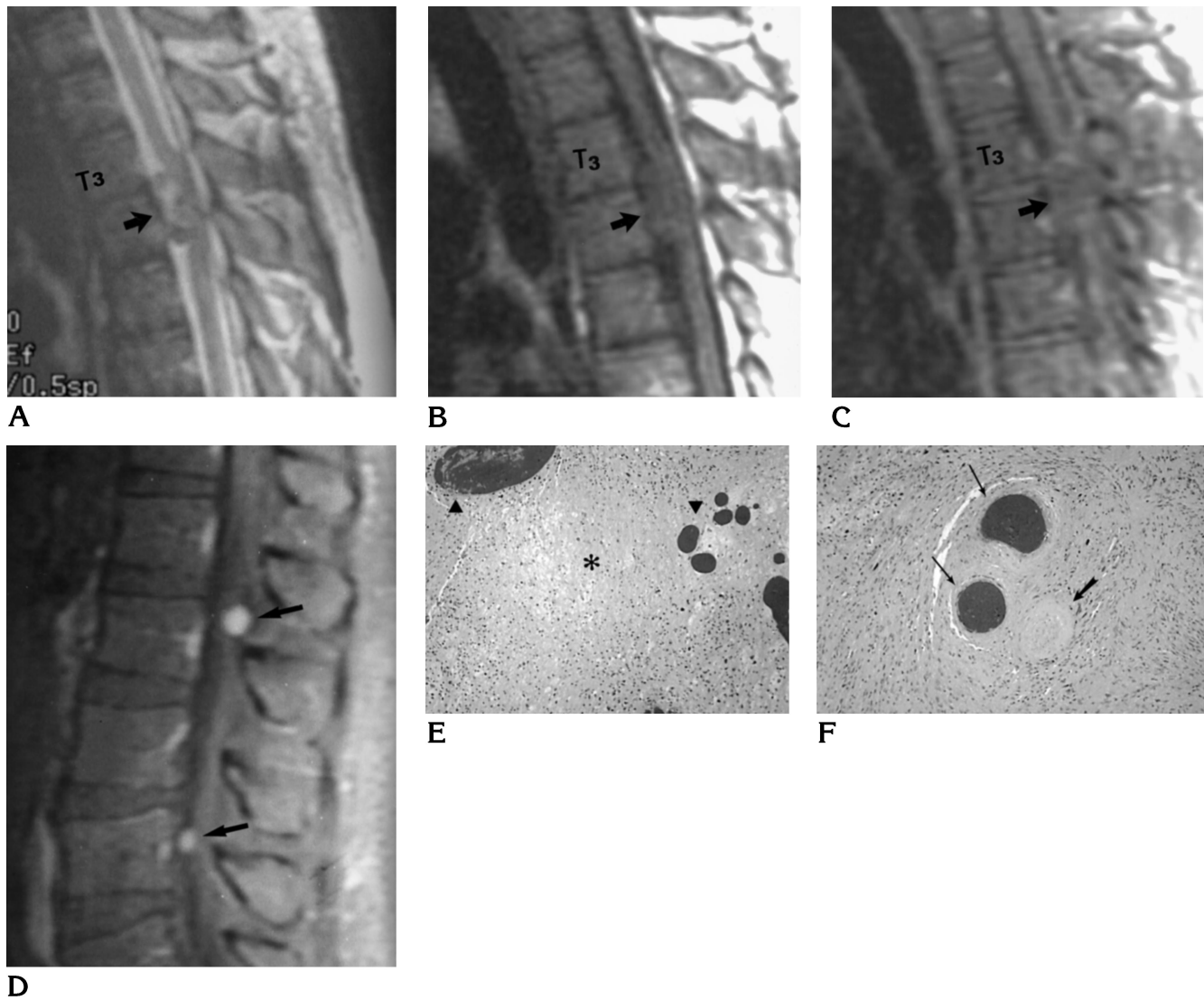
Previous reports have described the MR imaging characteristics of spinal schwannomas. They are typically hypointense relative to the cord on T1-weighted MR images and hyperintense on T2-weighted images (1). They may be inhomogeneous on T2-weighted images with focal areas of hyperintensity and hypointensity corresponding to cyst formation, hemorrhage, dense cellularity, or collagen deposition (3). Varma et al (5) described a target pattern with a peripheral hyperintense rim and central low in-

Received June 15, 1995; accepted after revision December 28.

From the Departments of Radiology (D.A.S., Y.N.) and Neuropathology (A.R., J.M.P.), University of Rochester (NY) Medical Center.

Address reprint requests to David Shrier, MD, Department of Radiology, Box 1648, University of Rochester School of Medicine and Dentistry, Rochester, NY 14642.

AJNR 17:1566-1568, Sep 1996 0195-6108/96/1708-1566 © American Society of Neuroradiology



D Fig 1. Thirty-seven-year-old man with 3-day history of fever, chills, left-sided pleuritic chest pain, left-sided numbness, and bilateral weakness of the lower extremities.

A, Sagittal T2-weighted noncontrast MR image (4000/96/2 [repetition time/echo time/excitations]) shows an intradural, extramedullary, inhomogeneous, oval-shaped mass in anterior spinal canal at the T3-4 level (*arrow*). The cord is compressed and displaced posteriorly.

B, Sagittal T1-weighted noncontrast MR image (600/11/2) shows homogeneous signal intensity within the tumor (*arrow*).

C, Sagittal T1-weighted, fat-suppressed, contrast-enhanced MR image (800/15/2) shows no significant enhancement within the schwannoma (*arrow*).

D, Sagittal T1-weighted, fat-suppressed, contrast-enhanced MR image (800/15/2) through the lumbar spine shows two uniformly enhancing intradural lesions, consistent with schwannomas (*arrows*).

E, Photomicrograph shows coagulation necrosis in the center (*asterisk*) and congested veins at the upper and right edges of the field (*arrowheads*). The rest of the field contains loose neoplastic Schwann cells (Antoni B pattern) with pleomorphic nuclei.

F, Photomicrograph shows a thrombosed artery (*wide arrow*) with organized thrombus occupying the lumen and congested hyalinized veins (*thin arrows*).

tensity corresponding to peripheral myxomatous tissue and central fibrocollagenous tissue.

Virtually all schwannomas enhance after administration of contrast material (2, 7). Friedman et al (3) reviewed seven cases of spinal schwannoma and found heterogeneous enhancement in all cases. Peripheral enhancement was described in five of seven lesions, which, according to the authors, should suggest the diagnosis of schwannoma.

In our case of multiple intradural extramedullary spinal lesions in a young man with symptoms of acute thoracic cord compression, the MR appearance of the pathologically proved thoracic schwannoma was typical on precontrast T1-weighted and T2-weighted MR images. However, contrast-enhanced T1-weighted images were atypical by virtue of the lack of contrast enhancement. We postulate that the lack of enhancement was due to absent perfusion within the acutely infarcted tumor, in conformity with the microscopic findings indicating arterial thrombosis and marked venous congestion. It is

likely that swelling of the lesion as a consequence of infarction resulted in acute compression of the thoracic cord.

References

1. Demachi H, Takashima T, Kadoya M, et al. MR imaging of spinal neurinomas with pathological correlation. *J Comput Assist Tomogr* 1990;14:250-254
2. Osborn AG. *Diagnostic Neuroradiology*. St. Louis: Mosby, 1994: 895-898
3. Friedman DP, Tartaglino LM, Flanders AE. Intradural schwannomas of the spine: MR findings with emphasis on contrast-enhancement characteristics. *AJR Am J Roentgenol* 1992;158: 1347-1350
4. Li MH, Holtås S, Larsson E-M. MR imaging of intradural extramedullary tumors. *Acta Radiol* 1992;33:207-212
5. Varma DGK, Mouloupoulos A, Sara AS, et al. MR imaging of extracranial nerve sheath tumors. *J Comput Assist Tomogr* 1992;16: 448-453
6. Egelhoff JC, Bates DJ, Ross JS, Rothner AD, Cohen BH. Spinal MR findings in neurofibromatosis types 1 and 2. *AJNR Am J Neuroradiol* 1992;13:1071-1077
7. Ishii N, Matsuzawa H, Houkin K, et al. An evaluation of 70 spinal schwannomas using conventional computed tomography and magnetic resonance imaging. *Neuroradiology* 1991;33:542