



Providing Choice & Value

Generic CT and MRI Contrast Agents



**FRESENIUS
KABI**

CONTACT REP

AJNR

Variability of corpus callosal area measurements from midsagittal MR images: effect of subject placement within the scanner.

R A Rauch and J R Jenkins

AJNR Am J Neuroradiol 1996, 17 (1) 27-28

<http://www.ajnr.org/content/17/1/27>

This information is current as of July 31, 2025.

Variability of Corpus Callosal Area Measurements from Midsagittal MR Images: Effect of Subject Placement within the Scanner

Ronald A. Rauch and J. Randy Jinkins

Summary: Variation in corpus callosum area measured from midsagittal MR images was evaluated in 12 healthy subjects who were each imaged four to seven times. Statistically significant differences between measurements of the same subject were found on 47% of the images, with an average difference of 5.9% between images.

Index terms: Brain, measurements; Corpus callosum, anatomy; Magnetic resonance, technique

Quantitative morphologic studies of the brain rely on defining and measuring a structure on an image or photograph. This two-dimensional representations of a three-dimensional object is produced by sectioning the object in some plane. The sectioning process may not be consistent, and this can affect the measurement made. We evaluated the reliability of callosal area measurements made by an observer who used the magnetic resonance (MR) monitor to define the corpus callosum's border on different images of the same subject's brain acquired at different times. The technique simulates techniques previously described to measure callosal size (1–3) from MR images. These data could likely be generalized to other investigations that use photographs of images or tissue (4–8).

Materials and Methods

MR examinations were acquired on a 1.5-T magnet with a T1-weighted (600/20/1 [repetition time/echo time/excitations]) multisection sagittal conventional spin-echo sequence with a 5-mm section thickness, a 1.5-mm gap, and a 256×192 matrix. Twelve healthy adult volunteers underwent four to seven separate MR examinations (mean, 5.8 per subject) within a 1-week period. For each study, the sagittal image closest to the midline was used to measure the callosal area. Each image was recalled from the MR computer's hard disk; brightness and contrast were

set to approximate images used for clinical evaluation, and the border of the corpus callosum was outlined manually by the same neuroradiologist with the trackball (Fig 1). The area of this region of interest was computed with standard MR software. Each image was measured 5 to 11 times (mean, 7.8). The mean of this series was used to compare different images of the same subject.

Results

Mean callosal area for all subjects was 5.7 cm^2 . The average SD for each series of measurements from one image made by one observer was 0.20 cm^2 . With these data, the calculated 95% confidence interval for any one measurement was $\pm 2.5\%$. The average SD for mean callosal areas measured from different images of the same subject was 0.26 cm^2 . With these data, the calculated 95% confidence interval for any one image's measurement was $\pm 3.7\%$. Student *t* tests were used to compare the series of measurements made from one midsagittal image to the measurements made from a different midsagittal image of the same subject. Eighty (47%) of the 169 possible comparisons showed statistically significantly different callosal area measurements ($P < .01$). The average difference between measured callosal areas for different MR images of the same subject was 0.34 cm^2 . This represented 5.9% of mean callosal area.

Discussion

The corpus callosum is the major cerebral commissure connecting the hemispheres. Prior research has evaluated the callosal area, in an attempt to correlate commissural size to inter-hemispheric connection and/or function. It is

Received August 26, 1994; accepted after revision February 13, 1995.

Presented at the 32nd Annual Meeting of the American Society of Neuroradiology, May 1–7, 1994.

From the Department of Radiology, Section of Neuroradiology, University of Texas Health Science Center, San Antonio.

Address reprint requests to Ronald A. Rauch, MD, Department of Radiology, Section of Neuroradiology, University of Texas Health Science Center, 7703 Floyd Curl Dr, San Antonio, TX 78284-7800.

AJNR 17:27–28, Jan 1996 0195-6108/96/1701-0027 © American Society of Neuroradiology

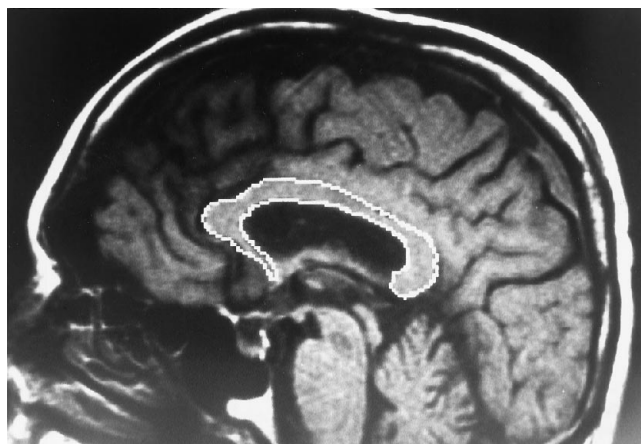


Fig 1. Midsagittal T1-weighted (600/20) image of a healthy subject. The border of the corpus callosum has been outlined by a neuroradiologist who used a trackball and the MR computer to create a region of interest. From this region of interest, the MR computer calculated the area enclosed to provide a measure of the callosal area.

clearly possible to make measurements of the callosal area from midsagittal brain images, but, given the variation in reported results, even for apparently simple questions (eg, whether male or female subjects have larger callosa) (1–8), one should consider the possible impact technical variability might have on these measurements.

To investigate the reliability of callosal measurements, the same observer made multiple measurements of the callosal area using different MR images from the same subject. Intraobserver measurement variation may depend on the observer. In this study a $\pm 2.5\%$ variation was found. Variability in appearance of the callosum, attributable to differences in the orientation of the scan plane used to generate the midsagittal image, resulted in a larger measurement variation ($\pm 3.7\%$) and frequently (47%) produced images of the same subject that yielded significantly different callosal area mea-

surements. Although these differences may diminish in importance in studies of large numbers of subjects, in which random variation might affect each group equally, these data do suggest limits for reproducibility of any single callosal area measurement. Thus for investigations with only a small number of subjects, the measurement technique would seem to limit the ability to detect differences of less than 5% to 10% of total callosal area. Larger differences and/or larger subject groups should improve the reliability of these types of results.

Acknowledgment

We thank Cono Farias for his help with the photographic reproductions used in this manuscript.

References

1. Laissy JP, Patruix B, Duchateau C, et al. Midsagittal MR measurements of the corpus callosum in healthy subjects and diseased patients: a prospective survey. *AJNR Am J Neuroradiol* 1993;14:145–154
2. Rauch RA, Jenkins JR. Analysis of cross-sectional area measurements of the corpus callosum adjusted for brain size in male and female subjects from childhood to adulthood. *Behav Brain Res* 1994;64:65–78
3. Coffey CE, Wilkinson WE, Parashos IA, et al. Quantitative cerebral anatomy of the aging human brain: a cross-sectional study using magnetic resonance imaging. *Neurology* 1992;42:527–536
4. Clarke S, Kraftsik R, Van der Loos H, Innocenti GM. Forms and measures of adult and developing human corpus callosum: is there sexual dimorphism? *J Comp Neurol* 1989;280:213–230
5. Kertesz A, Polk M, Howell J, Black SE. Cerebral dominance, sex, and callosal size in MRI. *Neurology* 1987;37:1385–1388
6. Byne W, Bleier R, Houston L. Variations in human corpus callosum do not predict gender: a study using magnetic resonance imaging. *Behav Neurosci* 1988;102:222–227
7. Allen LS, Richey MF, Chai YM, Gorski RA. Sex differences in the corpus callosum of the living human being. *J Neurosci* 1991;11:933–942
8. Steinmetz H, Jancke L, Kleinschmidt A, Schlaug G, Volkmann J, Huang Y. Sex but no hand difference in the isthmus of the corpus callosum. *Neurology* 1992;42:749–752