



**Providing Choice & Value**

Generic CT and MRI Contrast Agents



**FRESENIUS  
KABI**

**CONTACT REP**

**AJNR**

**Intraventricular cryptococcal cysts.**

J R Vender, D M Miller, T Roth, S Nair and A C Reboli

*AJNR Am J Neuroradiol* 1996, 17 (1) 110-113

<http://www.ajnr.org/content/17/1/110>

This information is current as  
of July 28, 2025.

---

# Intraventricular Cryptococcal Cysts

John R. Vender, David M. Miller, Toni Roth, Somnath Nair, and Annette C. Reboli

**Summary:** The case of a 55-year-old immunocompetent woman with central nervous system cryptococcosis and multiple intraventricular cysts is presented. The cysts did not enhance on MR and had signal characteristics similar to cerebrospinal fluid on T1- and T2-weighted images; their intensity was lower than cerebrospinal fluid on proton density-weighted images.

**Index terms:** Brain, cysts; Nervous system, infection

Central nervous system cryptococcosis is usually made manifest as meningitis or meningoencephalitis (1). Central nervous system cryptococcal infection may present radiographically as meningitis with meningeal enhancement, abscesses, intraventricular or intraparenchymal cryptococcomas, gelatinous pseudocysts, and/or hydrocephalus.

## Case Report

A previously healthy, immunocompetent 55-year-old woman presented with a 4-month history of gait instability, which progressively worsened during the 2 weeks before admission. She described vertigo but had no headache or other neurologic symptoms. On admission, she was afebrile, and her neck was supple. Neurologic examination revealed papilledema, bilateral intention tremor, truncal and gait ataxia, and marked instability on Romberg testing. An admission chest radiograph and a complete blood count were normal. Magnetic resonance (MR) of the brain revealed mild noncommunicating hydrocephalus caused by multiple, nonenhancing, intraventricular cysts of the lateral and third ventricles. The cyst contents had signal characteristics approximating cerebrospinal fluid (CSF) on T1- and T2-weighted sequences and were lower in signal intensity than CSF on proton density-weighted sequences (Fig 1A–F). There was no evidence of calcification in the cystic lesions or in the brain parenchyma on CT. A diagnosis of chronic or postinflammatory intraventricular cysts was proposed. Neoplastic or congenital cysts and neurocysticercosis were suggested in the differential diagnosis.

The patient underwent ventriculoscopic intraventricular exploration and placement of a ventriculoperitoneal shunt. The opening CSF pressure was normal, and multiple intraventricular cysts with thin, clear walls were seen. The cyst fluid was milky white and had a viscosity similar to CSF. CSF collected during surgery had a white blood cell count of 1/mm<sup>3</sup> (it was a lymphocyte) and a red blood cell count of 1443/mm<sup>3</sup> with protein of 62 mg/dL and glucose of 41 mg/dL. India ink, acid-fast smear, cysticercosis and cryptococcal antigens, and routine microscopic examinations were negative. The vertigo and gait ataxia resolved after surgery. MR 1 month after surgery demonstrated decreased ventricular size and some residual cysts (Fig 1G and H). Delayed growth of *Cryptococcus neoformans* was reported from the intraoperative CSF culture 1 month after its collection. A repeat CSF analysis revealed a white blood cell count of 37/mm<sup>3</sup> with 83% lymphocytes; India ink examination of the CSF was positive. CSF cryptococcal antigen was positive at 1:4, and fungal cultures grew scant *C neoformans* in broth only. The patient was treated with a 10-week course of amphotericin B. All subsequent studies have been negative, and the patient remains asymptomatic after 12 months of follow-up.

## Discussion

The radiographic characteristics of cryptococcal infection are protean and frequently minimal. Hydrocephalus, both communicating and noncommunicating, is the most common, although nonspecific, finding (2, 3). Intraparenchymal and intraventricular mass lesions are less common. Cerebrocortical atrophy, noted in human immunodeficiency virus-positive patients, seems to be a sequela of the primary human immunodeficiency virus infection (4).

Gelatinous pseudocysts, which are nonenhancing, low-density lesions on computed tomography (4), are nonenhancing and have CSF intensity on T1- and T2-weighted MR. These pseudocysts represent a proliferation of the

---

Received November 29, 1994; accepted after revision April 5, 1995.

From the Departments of Neurosurgery (J.R.V., S.N.N.), Radiology, Division of Neuroradiology (T.R.), and Medicine, Division of Infectious Diseases (D.M.M., A.C.R.), Hahnemann University Hospital, Philadelphia, Pa.

Address reprint requests to Annette C. Reboli, MD, Cooper Hospital/University Medical Center, Robert Wood Johnson Medical School, Education and Research Building, 401 Haddon Ave, Room 268, Camden, NJ 08103.

AJNR 17:110–113, Jan 1996 0195-6108/96/1701-0110 © American Society of Neuroradiology

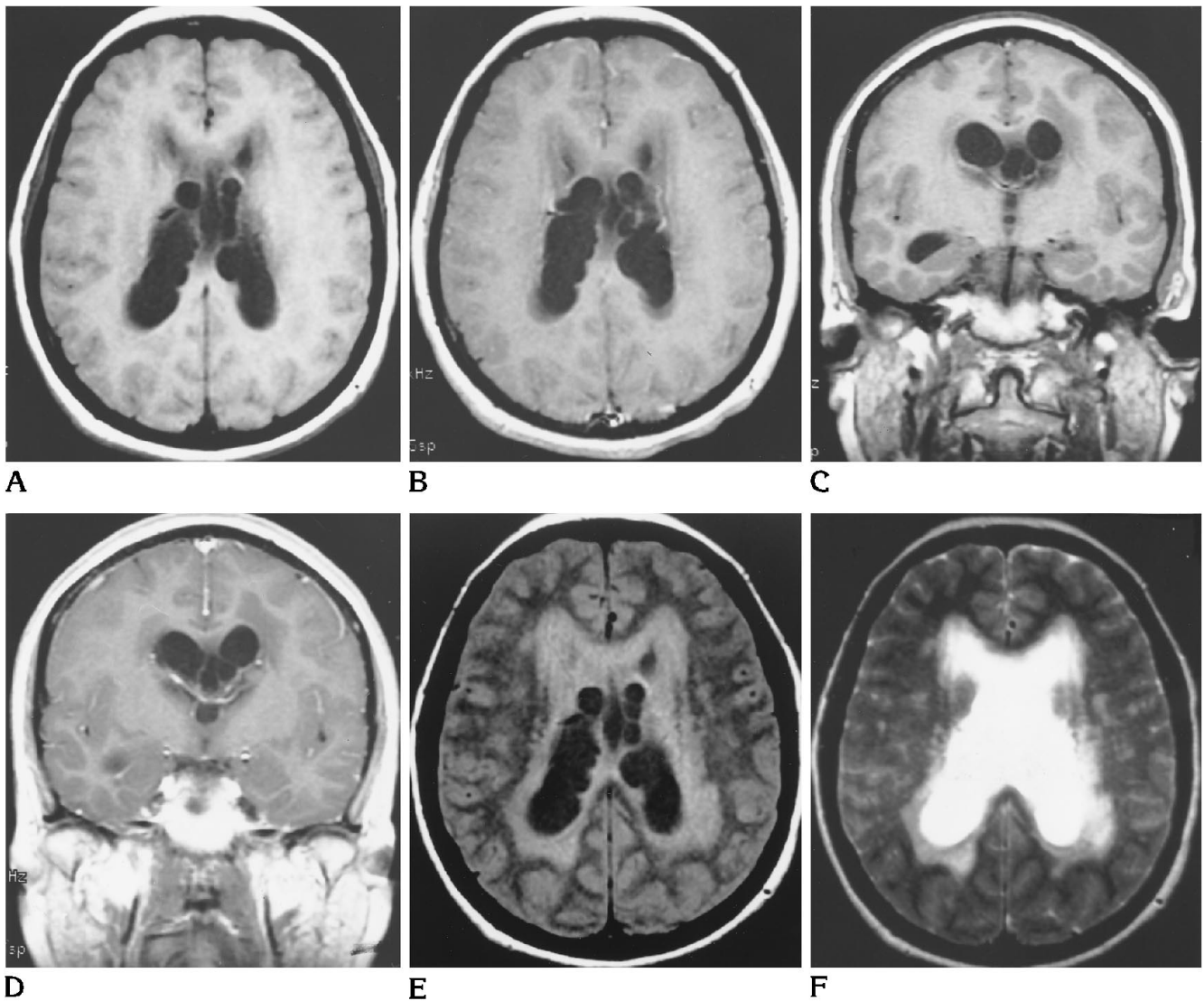


Fig 1. Before surgery, pregadolinium (A) and postgadolinium (B) axial, pregadolinium (C) and postgadolinium (D) coronal T1-weighted, axial proton-density (fast spin-variable echo, echo train 4/8) (E), and T2-weighted (F) MR images demonstrate multiple, nonenhancing intraventricular cysts that follow the signal characteristics of CSF with T1 and T2 weighting. On proton density-weighted images, the cyst contents remain lower in signal intensity than CSF. Cysts involve the lateral and third ventricles. There is no significant solid component associated with the cysts. Moderate dilatation of the lateral and minimal dilatation of the third ventricles, as well as associated periventricular signal changes consistent with transependymal flow of CSF, are noted. Incidentally, regions of high signal on T2-weighted images consistent with underlying small-vessel disease are noted. The subarachnoid space appears normal.

(Figure continues.)

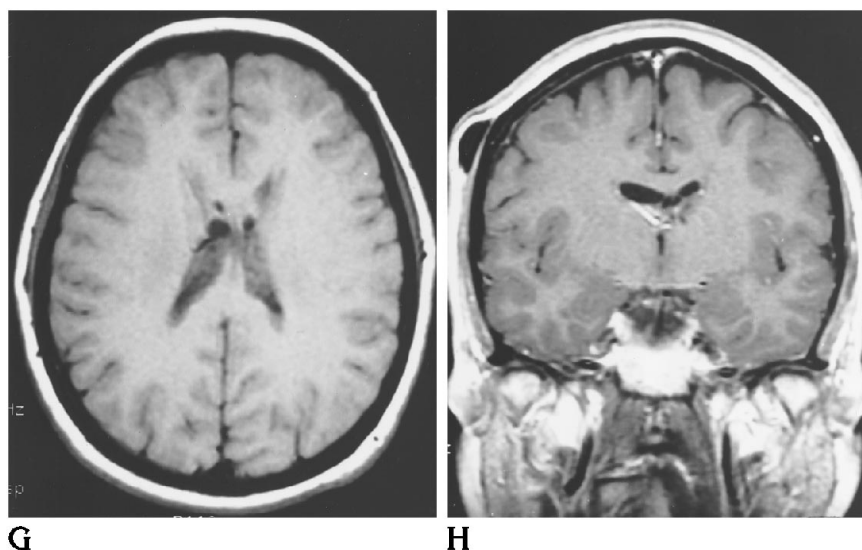
yeast in the Virchow-Robin spaces and are thought to represent an "unreactive" form of meningoencephalitis that has a predilection for the basal ganglia and periventricular regions (5). Pathologically, these lesions are characterized by a collection of yeast in a gelatinous mass without evidence of an immune response. The mucoid material constituting the pseudocyst is produced by the yeast. Occasionally, these lesions extend into the brain parenchyma

adjacent to the perivascular spaces (6). Therefore, the presence of gelatinous pseudocysts suggests an impaired immune status (7, 8).

Miliary lesions and granulomas or cryptococcomas can present as high- (9) or low- (5, 10) density masses on computed tomography and are of low intensity on T1-weighted and high intensity on T2-weighted MR sequences. Immunocompetent patients are more likely to present with cryptococcomas (7, 8). Because

Fig 1, continued.

After surgery, T1-weighted axial (G) and coronal (H) MR images demonstrate decreased ventricular size. The number of cysts and the size of the remaining cysts have decreased. There was no enhancement of the cysts. The ventriculoperitoneal shunt valve is noted in the right subgaleal space on the coronal image. As on the previous study, no abnormalities are present in the brain parenchyma or in the subarachnoid space.



they represent lesions associated with a disruption of the blood-brain barrier, they can enhance with the administration of contrast (7). Occasionally, mass lesions of the parenchyma can extend into the ventricular system (2, 11, 12). Pathologically, these lesions are characterized by a chronic granulomatous reaction including macrophages, lymphocytes, and foreign body-type giant cells. A more acute inflammatory response with neutrophils and supuration is occasionally seen (6). Mass lesions, pseudocysts, and hydrocephalus, followed radiographically, are shown to regress with antifungal therapy in many cases (2, 3, 11).

Although MR is more sensitive than computed tomography, no radiographic signs pathognomonic for cryptococcosis have been identified. The combination of pseudocysts and granulomas of the choroid plexus, however, highly suggest the diagnosis (5). The use of a double dose of contrast, with imaging immediately after the second dose and subsequent imaging after a 40-minute delay, is well tolerated (5, 13) and can demonstrate the presence of minimal disruptions in the blood-brain barrier, thereby reducing the number of false-negative studies (5). Andreula et al (5) presented nine patients with acquired immunodeficiency syndrome and confirmed central nervous system cryptococcal infection. Meningocortical enhancement was noted in five of the eight patients given a single dose (0.1 mmol/kg) of

gadopentetate dimeglumine and in two additional patients after a second dose was administered.

In the case presented, the cyst fluid had a waterlike consistency and defined cyst walls, thus distinguishing these true cysts from gelatinous "pseudocysts." The waterlike cyst fluid had signal characteristics comparable to CSF on T1- and T2-weighted images but remained of low intensity on proton density (Fig 1E), suggesting a different chemical composition from that of CSF. Ofori-Kwakye et al (14) present a patient with computed tomographic evidence of septation of the wall of the lateral ventricle with dilation of the frontal horns and third and fourth ventricles. This was associated, however, with high-density, contrast-enhancing lesions in the bodies of both lateral ventricles (14). The initially minimal inflammatory response in the CSF and the delayed growth of the fungus (present after 1 month) suggest a low inoculum of cryptococcus. This is supported by the initially negative India ink and cryptococcal antigen studies. The presence of a low-grade, indolent inflammatory process may have resulted in septation of the ventricles, thus producing the radiographic and clinical findings seen in this patient. The presence of cryptococcus in the initial culture is not attributable to a contaminant, because the second CSF specimen was clearly abnormal with a positive cryptococcal antigen, a positive India ink result, and growth in culture.

Care must be taken in the evaluation and treatment of patients presenting with headache, nausea and/or vomiting, or personality changes with marginal disease, cysts, or small intraparenchymal or intraventricular mass lesions on radiologic studies. Misdiagnoses, such as a neoplasm, may result in a delay in antifungal therapy and/or the use of steroids, which can result in a poor or fatal outcome.

## Acknowledgment

We acknowledge Christos D. Katsetos, MD, for his critical review of the manuscript.

## References

1. Arrington JA, Murtagh FR, Martinez, CR, et al. CT of intracranial cryptococcoma. *AJNR Am J Neuroradiol* 1984;5:472-473
2. Cornell SH, Jacoby CJ. The varied computed tomographic appearance of intracranial cryptococcosis. *Radiology* 1982;143:703-707
3. Takasu A, Taneda M, Otuki H, et al. Gd-DTPA-enhanced MR imaging of cryptococcal meningoencephalitis. *Neuroradiology* 1991;33:443-446
4. Popovich MJ, Arthur RH, Helmer E. CT of intracranial cryptococcosis. *AJR Am J Roentgenol* 1989;154:603-607
5. Andreula CF, Burdi N, Carella A. CNS cryptococcosis in AIDS: spectrum of MR findings. *J Comput Assist Tomogr* 1993;17:438-441
6. Robbins SL, Cotran R, Kumar V. *Pathologic Basis of Disease*. 3rd ed. Philadelphia: WB Saunders, 1984;355-356
7. Ostrow TD, Hudgins PA. Magnetic resonance imaging of intracranial fungal infections. *Top Magn Reson Imaging* 1994;6:22-31
8. Waterston JA, Gilligan BS. Cryptococcal infections of the central nervous system: a ten year experience. *Clin Exp Neurol* 1987;23:127-137
9. Tan CT, Kuan BB. Cryptococcus meningitis, clinical-CT scan considerations. *Neuroradiology* 1987;29:43-46
10. Tien RD, Chu PK, Hesselink JR, et al. Intracranial cryptococcosis in immunocompromised patients: CT and MR findings in 29 cases. *AJNR Am J Neuroradiol* 1991;12:283-289
11. Fujita NK, Reynard M, Sapico FL, et al. Cryptococcal intracerebral mass lesions. *Ann Intern Med* 1981;94:382-388
12. Aoki N. Intraventricular cryptococcal granulomas: case report. *Neurol Med Chir* 1989;29:251-254
13. Yuh WTC, Fisher DJ, Runge VM, et al. Phase III multicenter trial of high-dose gadoteridol in MR evaluation of brain metastases. *AJNR Am J Neuroradiol* 1994;15:1037-1051
14. Ofori-Kwakye SK, Wang AM, Morris JH, et al. Septation and focal dilatation of ventricles associated with cryptococcal meningoencephalitis. *Surg Neurol* 1986;25:253-260