



Discover Generics

Cost-Effective CT & MRI Contrast Agents



WATCH VIDEO

AJNR

Recurrent parotid adenocarcinoma occurring within the cerebellopontine angle.

S W Stravropoulos, S K Mukherji and A A Mancuso

AJNR Am J Neuroradiol 1995, 16 (7) 1529-1531

<http://www.ajnr.org/content/16/7/1529>

This information is current as
of June 13, 2025.

Recurrent Parotid Adenocarcinoma Occurring within the Cerebellopontine Angle

S. William Stravropoulos, Suresh K. Mukherji, and Anthony A. Mancuso

Summary: A patient presented 3½ years after resection of a malignant parotid tumor with a new cerebellopontine angle mass. The presence of multiple punctate calcifications and loss of T2 signal were helpful in correctly identifying the lesion as mucinous adenocarcinoma.

Index terms: Carcinoma; Cerebellopontine angle, neoplasms; Salivary glands, neoplasms

The purpose of this report is to describe an unusual appearance of perineural recurrence along cranial nerve VII of a previously resected parotid neoplasm.

Case History

The patient is a 69-year-old woman who presented in January 1993 with a 3-month history of progressive hoarseness, dysphagia, facial numbness and weakness, xerostomia, decreased hearing in the right ear, and a 9-kg weight loss. The patient's medical history was significant for a gross total resection of a poorly differentiated adenocarcinoma of the right parotid gland in September 1989. At the time of surgery, cranial nerve VII had been involved with tumor and resected to the level of the stylomastoid foramen. The margins of resection had been negative and the patient treated with radiation therapy to the parotid bed. She was asymptomatic until the time of presentation.

On physical exam, the patient appeared to be thin but in no acute distress. Head and neck exam was significant for a well-healed surgical scar across the right face and neck. The patient had an atrophic right sternocleidomastoid muscle and trapezius muscle, with a right lateral rotation of the neck. Cranial nerve examination was significant for decreased pinprick sensation on the right side of the face and a right peripheral seventh cranial nerve paralysis. There was decreased hearing in the right ear. The palate and uvula deviated to the left. Cerebellar examination revealed normal finger to nose movement and normal rapidly

alternating movements bilaterally. The gait was slightly wide based.

A contrast-enhanced magnetic resonance image demonstrated a large heterogeneously enhancing extraaxial mass arising from the right cerebellopontine angle and extending into the internal auditory canal. The abnormality appeared to involve the anterior genu of the facial nerve (Fig 1A). The tumor extended anteriorly to involve the anterolateral aspect of the pons and cisternal portion of the trigeminal nerve. Inferiorly, the lesion extended to the superior aspect of the jugular foramen. T2-weighted images demonstrated preferential T2 shortening, resulting in diffuse loss of signal throughout the mass (Fig 1B).

Contrast-enhanced computed tomography was performed with contiguous 1-mm sections through the temporal bone to evaluate the extent of bone erosion. Although the mass involved the region of the jugular fossa, the jugular tubercle was not eroded. There was enlargement of the descending facial canal on the ipsilateral side of the tumor. Interestingly, the mass demonstrated diffusely scattered foci of increased attenuation felt to represent calcifications that extended into the internal auditory canal (Fig 1C). Based on these findings, we thought the lesion was a recurrence of the patient's previously resected adenocarcinoma along cranial nerve VII.

The patient underwent a right-sided suboccipital craniotomy and biopsy. No gross involvement of the undersurface of the temporal bone immediately contiguous to the parotid bed was identified. The frozen section specimen from the procedure revealed a poorly differentiated adenocarcinoma with the same histologic appearance as the tumor resected in 1989. Multiple scattered calcifications were seen throughout the lesion on histologic examination. We thought the tumor to be a perineural recurrence along cranial nerve VII of the previously resected parotid adenocarcinoma, now presenting as a cerebellopontine angle mass. The patient underwent a subtotal resection and was treated with palliative radiotherapy.

Received April 14, 1994; accepted after revision October 25.

From the Department of Radiology, University of Florida College of Medicine, Shands Teaching Hospital, Gainesville (S.W.S., A.A.M.), and the Department of Radiology, University of North Carolina School of Medicine, Chapel Hill (S.K.M.).

Address reprint requests to Suresh K. Mukherji, MD, Department of Radiology, University of North Carolina School of Medicine, CB Box #7510, 3rd Floor Infirmary, Chapel Hill, NC 27599-7510

AJNR 16:1529-1531, Aug 1995 0195-6108/95/1607-1529 © American Society of Neuroradiology

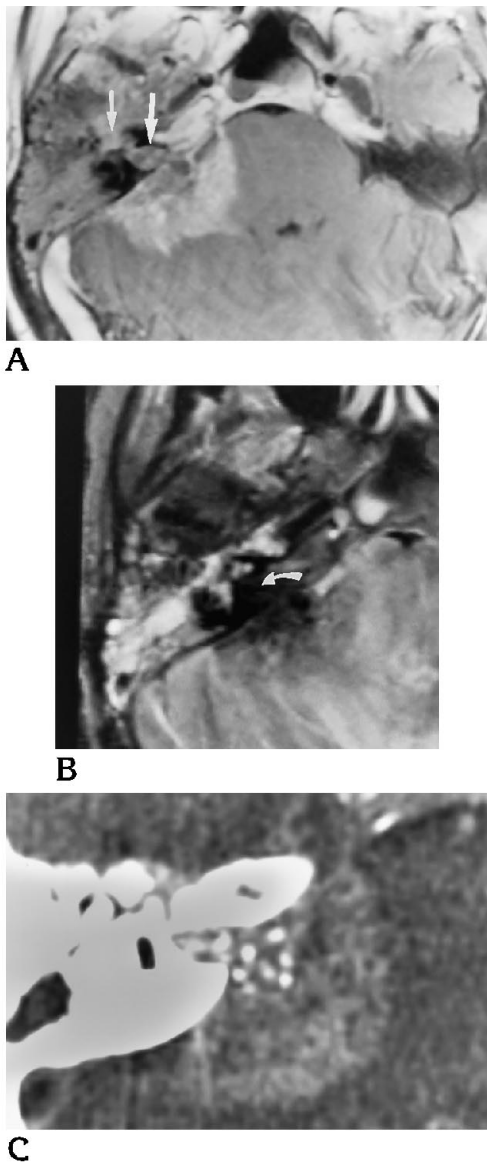


Fig 1. A, Axial T1-weighted contrast-enhanced magnetic resonance study demonstrates a heterogeneously enhancing mass arising within the right cerebellopontine angle extending into the internal auditory canal (*large arrow*) with involvement of the labyrinthine portion of the facial nerve (*small arrow*). The medial margin suggests brain stem invasion, confirmed at surgery.

B, Axial T2-weighted magnetic resonance image shows areas of signal loss within the mass, which may be seen in metastases arising from mucin-producing adenocarcinomas (*arrow*).

C, Axial computed tomography of the temporal bone filmed at wide windows shows scattered punctate foci of increased attenuation throughout the lesion and extending into the internal auditory canal. Radiographically, they were thought to represent calcifications and were helpful in the preoperative diagnosis of recurrent adenocarcinoma within the cerebellopontine angle.

Discussion

A variety of neoplastic and nonneoplastic lesions occur in the cerebellopontine angle. Brackman and Bartels demonstrated that of 1354 cerebellopontine angle tumors, 91.3% were acoustic schwannomas. The remaining cerebellopontine angle masses included meningiomas (3.1%), epidermoids (2.4%), and facial nerve schwannomas (1.2%). Additionally, there were 25 (2%) rare masses reported, which included arachnoid cysts, hemangiomas, hemangioblastoma, astrocytomas, medulloblastomas, metastatic tumors, dermoids, lipomas, malignant teratomas, and chondrosarcomas. Of the 1354 cases, only 3 were metastatic tumors (1, 2).

Malignant parotid tumors make up 20% of all primary parotid neoplasms. Mucoepidermoid carcinoma, adenoid cystic carcinoma, and acinic cell carcinoma are the most commonly seen lesions and together make up more than 60% of primary parotid malignant neoplasms (3). The remainder of parotid malignant neoplasms represent a variety of different tumor types.

Adenocarcinoma of the parotid gland is thought to arise from glandular elements. It comprises 2.8% of all parotid tumors and 15.7% of all parotid malignant neoplasms. The lesion most commonly occurs in adults (20 to 70 years of age) and has no apparent sex predilection. Histologically, the tumor is composed of cylindrical cells of variable height that often are mucin-producing (4). Radiographically, primary adenocarcinoma of the parotid gland cannot be reliably differentiated from other primary parotid neoplasms, benign or malignant. Adenoid cystic carcinoma is a malignant epithelial tumor of salivary gland origin and should not be confused with adenocarcinoma, because these lesions are histologically distinct.

Perineural spread of parotid tumors most commonly occurs in mucoepidermoid carcinoma and adenoid cystic carcinoma (4). Local recurrence of parotid malignant neoplasms occurs most frequently in regional lymph nodes in approximately 30% of cases. Distant metastases occur in approximately 21% of cases (3) and tend to involve distant lymph nodes, skeleton, and lungs (4). Perineural spread of an adenocarcinoma of the parotid gland along cranial nerve VII with extension into the cerebellopontine angle is a less usual mode of failure.

Punctate calcifications may be seen in a variety of mucin-producing adenocarcinomas, especially those lesions arising within the pancreas and colon. Although adenocarcinomas of the parotid gland often are mucin-producing, the finding of multiple radiographically visible calcific foci is unusual in our experience.

Recently, it has been shown that preferential T2 shortening can be seen in intracerebral metastases from adenocarcinoma from the gastrointestinal tract (5). Although the loss of T2 signal in the current case is likely attributable to the dephasing of spins resulting from the multiple calcifications within the mass, the hydration layer effect occurring in a mucin-producing adenocarcinoma (5) also may have contributed to the phenomena.

This case represents an unusual cerebellopontine angle lesion resulting from the perineural spread of a parotid adenocarcinoma along the seventh cranial nerve. Although ade-

nocarcinomas of the parotid gland are mucin-containing, the presence of radiographically visible calcifications is uncommon. The findings of punctate calcifications on computed tomography and typical T2 shortening described in mucin-producing adenocarcinomas were helpful in the preoperative diagnosis of this lesion.

References

1. Brackman DE, Bartels LJ. Rare tumors of the cerebellopontine angle. *Otolaryngol Head Neck Surg* 1980;88:555
2. Lo WM. Tumors of the temporal bone and cerebellopontine angle. In: Som PM, Bergeron RT, ed. *Head and Neck Imaging*. 2nd ed. St Louis: Mosby Year Book, 1991:1046-1102
3. Cummings CW. *Otolaryngology-Head and Neck Surgery*. 2nd ed. St Louis: Mosby Year Book, 1990:1043-1078, 3271-3289
4. Batsakis JG. *Tumors of the Head and Neck*. 2nd ed. Baltimore: Williams & Wilkins, 1979:15-64
5. Egelhoff JC, Ross JS, Modic MT, Masaryk TJ, Estes M. MR imaging of metastatic GI adenocarcinoma in brain. *Am J Neuroradiol* 13: 1221-1224