



## Discover Generics

Cost-Effective CT & MRI Contrast Agents



WATCH VIDEO

# AJNR

## **Intracranial electroencephalographic and evoked-potential recording from intravascular guide wires.**

P Stoeter, L Dieterle, A Meyer and N Prey

*AJNR Am J Neuroradiol* 1995, 16 (6) 1214-1217

<http://www.ajnr.org/content/16/6/1214>

This information is current as  
of June 19, 2025.

---

# Intracranial Electroencephalographic and Evoked-Potential Recording from Intravascular Guide Wires

P. Stoeter, L. Dieterle, A. Meyer, and N. Prey

**Summary:** We describe a technique for recording electroencephalographic and evoked-potential information directly from the cerebral hemispheres and brain stem, via an endovascular approach. Recordings were performed with polytef-insulated guide wires in the course of interventional angiographies in 23 patients. All registrations were compared with simultaneous recordings from extracranial electrodes. This preliminary study raises the possibility that this technique may help to explore the electric activity of deep cerebral structures otherwise accessible only by stereotactic puncture or electrode insertion.

**Index terms:** Electroencephalography; Seizures; Interventional neuroradiology

Intracranial electroencephalographic (EEG) recordings usually are carried out as a preoperative diagnostic procedure in patients with otherwise intractable epileptic seizures. In applying surface electrodes, burr holes, craniotomy, or puncture of the foramen ovale is used (1, 2). For intracerebral recordings, stereotactic brain punctures may be necessary (3).

As an alternative, we did electroencephalographic and evoked-potential recording intracranially during interventional angiographies from specially prepared guide wires.

## Methods

### *Patients and Angiographies*

Recordings were performed in 23 patients from whom informed consent had been obtained. There were 10 women and 13 men with an age range of 29 to 79 years. The angiographic procedures all were carried out superselectively with a Tracker-18 microcatheter (Target Therapeutics, San Jose, Calif) because of intended embolizations of glomus tumors ( $n = 1$ ), meningiomas ( $n = 16$ ), calvarial metastases ( $n = 1$ ), and arteriovenous angiomas ( $n = 5$ ) in the territories of the middle meningeal artery ( $n = 16$ ), basilar artery ( $n = 4$ ), and anterior ( $n = 1$ ) and middle ( $n = 2$ ) cerebral arteries. There were no complica-

tions and no interference with the embolizations, which were carried out immediately after the recordings.

### *EEG and Evoked Potential Recording*

EEGs (15 cases) and evoked potentials (8 cases) were recorded from Seeker-10 guide wires covered continuously with polytef. The noninsulated distal platinum tip was 3 to 60 mm long. It was used as the different intraarterial electrode. The proximal end of the steel shaft was connected to the recording unit (Schwarzer Encephalograph ED 14, Picker, München, Germany, and Tesy II, Fa. Tönnies, Freiburg, Germany). All recordings were performed with the usual parameters without special amplification or filters. The somatosensory evoked potentials were evoked by a series of 512 electric stimuli to the contralateral median nerve and the auditory evoked potentials by a series of 1026 ipsilateral click impulses (brain stem evoked-response audiometry program [4]). In vitro measurements revealed a conductive resistance of the guide wire of 50  $\Omega$  and showed no dependence of the recording properties on the length of its noninsulated tip. In all cases, conventional extracranial EEG and evoked-potential recording was done simultaneously from needle electrodes.

## Results

### *EEG*

In the 11 EEG recordings from the middle meningeal artery, the tip of the guide wire was advanced into the frontoparietal branch and thus placed over the outer surface of the temporal lobe. From this position, frequent groups of slow alpha and theta waves were recorded with potentials 2 to 4 times larger than those from the simultaneous extracranial registrations in 8 of 11 patients (Fig 1). These potentials disappeared when the tip of the electrode and the catheter were retracted below the cranial base.

In the remaining three cases without these special large and slow waves, the tip of the

---

Received June 5, 1992; accepted after revision September 6, 1994.

From the Institut für Neuroradiologie, Universitätsklinikum, Langenbeckstrasse 1, D-55131 Mainz, Germany.

Address reprint requests to Professor P. Stoeter.

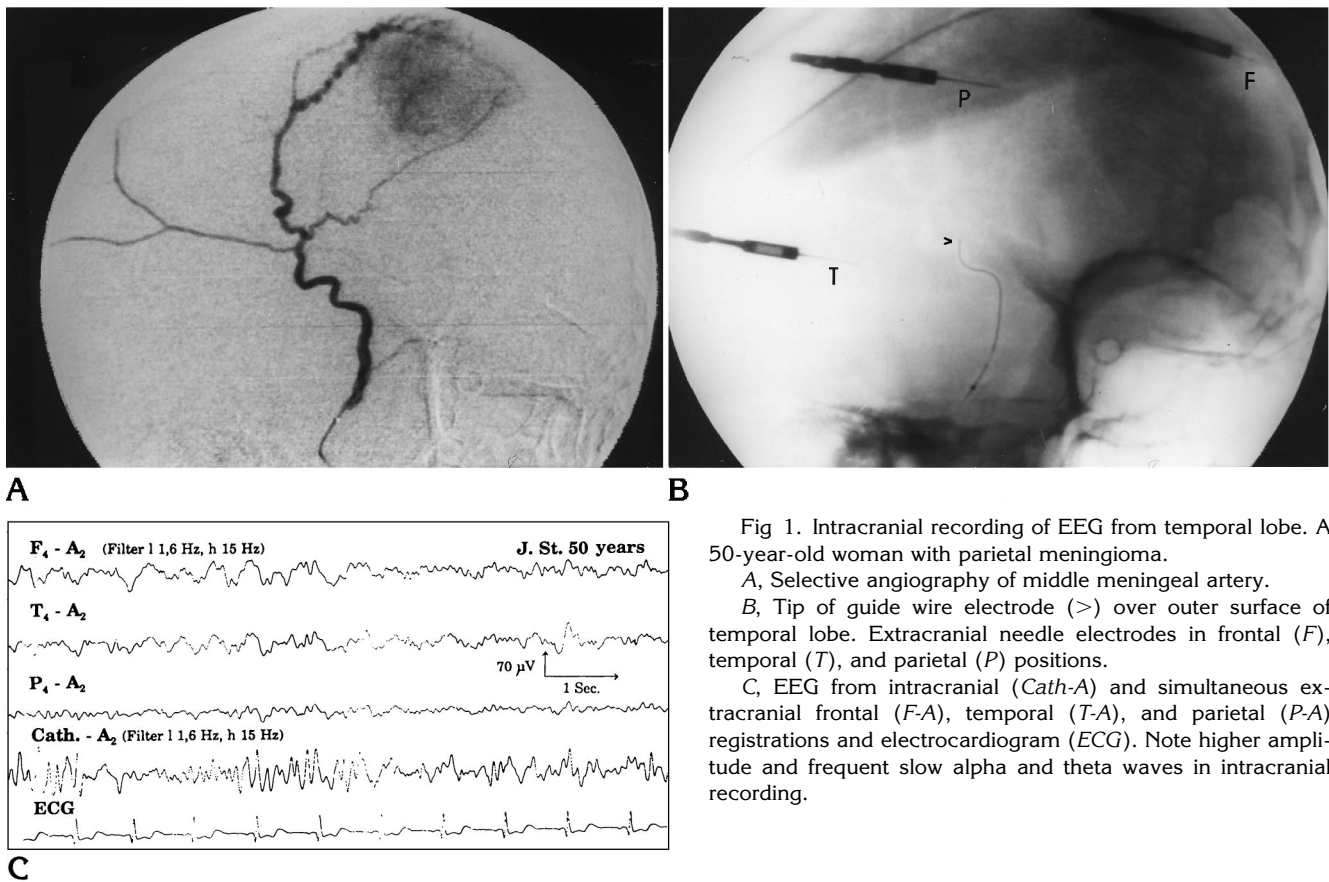


Fig 1. Intracranial recording of EEG from temporal lobe. A 50-year-old woman with parietal meningioma.

A, Selective angiography of middle meningeal artery.

B, Tip of guide wire electrode (>) over outer surface of temporal lobe. Extracranial needle electrodes in frontal (F), temporal (T), and parietal (P) positions.

C, EEG from intracranial (Cath-A) and simultaneous extracranial frontal (F-A), temporal (T-A), and parietal (P-A) registrations and electrocardiogram (ECG). Note higher amplitude and frequent slow alpha and theta waves in intracranial recording.

guide wire was situated not directly over the temporal lobe, but on the outer surface of the meningioma.

In four other patients, EEGs were recorded from the brain stem (basilar artery, one case) and the outer surface of the parietal (middle cerebral artery branches, two cases) and the frontal (callosomarginal artery, one case) lobes. In contrast to the recordings from the temporal lobe, no obvious differences in amplitude and frequency were seen as compared with the extracranial registrations.

#### *Somatosensory Evoked Potentials*

To reach a position near the central sulcus, we recorded these potentials from the petrosquamosal branch of the middle meningeal artery in four cases and from a posterior parietal branch in one case. In all these examinations, the distal noninsulated platinum tip of the guide wire electrode was 3 mm long. The latencies of the evoked potentials registered from the middle meningeal artery were similar to those from the simultaneous extracranial recordings,

whereas the amplitude depended on the position of the tip of the guide wire electrode. In two cases, the amplitude reached the level of the extracranial recordings from the central sulcus (Fig 2), whereas otherwise it decreased with increasing distance from this point.

#### *Auditory Evoked Potentials*

In 3 patients, auditory evoked potentials were registered from guide wire electrodes advanced into the basilar artery. Again, the latencies of the peaks were similar in the intracranial and extracranial recordings. In registrations from a proximal position at the verteobasilar junction, the amplitudes of the early peaks II and III were especially pronounced and higher than in the extracranial registrations (Fig 3).

Recordings from the distal part of the basilar artery and from the peduncular segments of the posterior cerebral arteries showed a larger amplitude of peaks IV and V, and in two cases a sixth and seventh peak could be identified. Retraction of the electrode to the proximal position

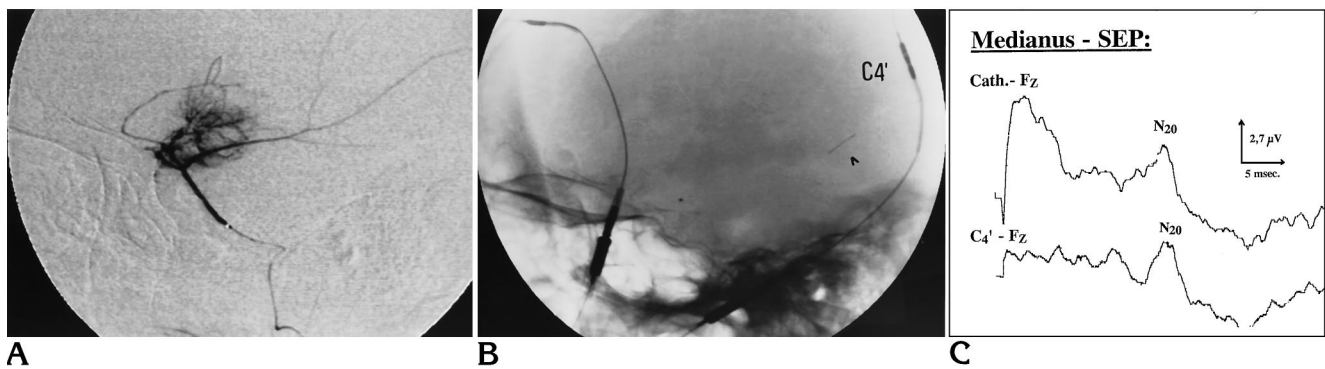


Fig 2. Intracranial recording of somatosensory evoked potential. A 56-year-old man with temporal meningioma. A, Selective angiography of middle meningeal artery.

B, Tip of guide wire electrode (>) over posterior part of temporal lobe. Extracranial needle electrode in parietal position (C4') registration.

C, Somatosensory evoked potential (SEP) ( $N_{20}$ ) from intracranial (Cath) and simultaneous extracranial (C4') registration. Similar latencies and amplitudes in both registrations.

again showed a pronunciation of the early peaks.

## Discussion

Intraarterial registrations of EEG and evoked potentials can be performed by intraarterial guide wire electrodes in the course of selective

angiographies. In the rare cases in which this technique has been used before in animal experiments (5, 6) and in humans (7, 8), the amplitude of the EEG potentials also was higher than in the extracranial recordings. In the baboon (6) and in one patient with a recurrent stroke (8), similar large and slow alpha and theta waves were recorded as in our eight cases

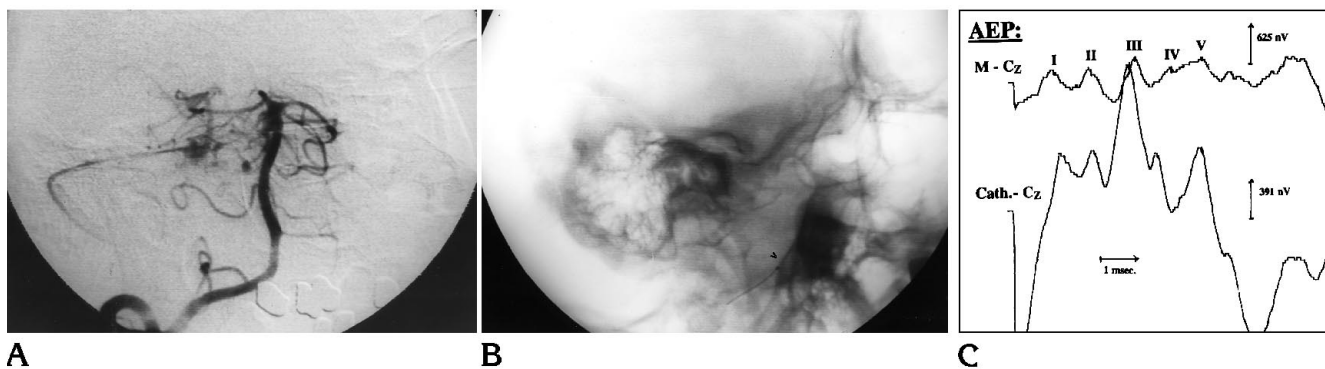
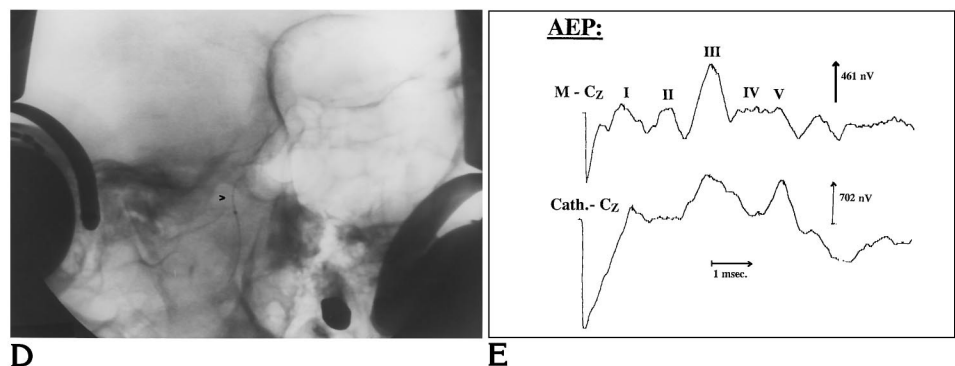


Fig 3. Intracranial recording of auditory evoked potential (AEP). A 52-year-old man with small arteriovenous angioma.

A, Selective angiography of basilar artery.

Tip of guide wire electrode (>) B, at vertebrobasilar junction and D, below basilar tip. Auditory evoked potentials (I-V) from intracranial (Cath) and extracranial mastoid (M) registrations from C, proximal and E, distal position of the intrabasilar electrode. Pronunciation of peak III in intracranial recording from vertebrobasilar junction and increasing peak V in intracranial recording from distal part of basilar artery.



with electrodes over the surface of the temporal lobe. A low-frequency pattern of temporal discharge also was observed in young patients from sphenoidal electrodes (9).

In our cases, these potentials disappeared after retraction of the electrode below the cranial base and similar large and slow potentials were not seen in recordings from other cerebral areas. Nevertheless, a conclusion with regard to the region of generation of these potentials has to be drawn with caution because the relation between the potentials recorded from subcortical, cortical, and scalp electrodes is rather complex (10, 11).

Somatosensory evoked potentials have been reported using intraarterial guide wires in the baboon with good results (6). According to our results, somatosensory evoked potentials can be recorded in the human with similar latency and amplitude as from conventional extracranial registrations if the tip of the guide wire electrode can be advanced to a point near the central sulcus. Better results might be expected from recordings from the postcentral branch of the middle cerebral artery.

The same dependence on the position of the electrode tip applies to the auditory evoked potentials recorded from the basilar artery. In the proximal position, a pronounced second and third peak could be registered, which are supposed to be generated in the auditory nerve and the olivary nucleus (12). The structures are in close vicinity to the vertebrobasilar junction, where the tip of the guide wire electrode was situated. If it was advanced to a more distal position, the later peaks IV and V that probably originate in the upper brain stem (12) were more pronounced, but not as much as the early peaks recorded from the proximal position. This may be because the auditory loop runs to the dorsal part of the pons and mesencephalon, whereas the basilar artery remains on its ventral surface.

Despite the limited time of registration and number of electrodes that can be applied, we regard this intraarterial recording technique as an additional method to register the electric

phenomena of deep cerebral structures otherwise only accessible by direct puncture. If applied in the course of interventional angiography, it carries no undue additional risk and may contribute to the understanding of the generation of these potentials in physiologic and pathologic conditions, as, for example, in combination with a selective Wada test (13, 14).

## References

1. Lüders H, Hahn J, Lesser RP, et al. Basal temporal subdural electrodes in the evaluation of patients with intractable epilepsy. *Epilepsia* 1989;30:131-142
2. Wieser HG, Elger CE, Stodieck SRG. The "foramen ovale electrode": a new recording method for the preoperative evaluation of patients suffering from mesio-basal temporal lobe epilepsy. *Electroenceph Clin Neurophysiol* 1985;61:314-322
3. Maxwell RE, Gates JR, Fiol ME, et al. Clinical evaluation of a depth encephalography electrode. *Neurosurgery* 1983;12:561-564
4. American Electroencephalographic Society. Guidelines for clinical evoked potential studies. *J Clin Neurophysiol* 1984;1:3
5. Penn RD, Hilal SK, Michaelson WJ, Goldensohn ES, Driller J. Intravascular intracranial EEG recording: technical note. *J Neurosurg* 1973;38:239-243
6. Reuter BM, Brassel F, Linke DB, Hartmann A, Kurthen M. Tiefen-EEG und evozierte Potentiale mittels intravaskulärer Katheter-Elektrode beim Pavian. *Z EEG-EMG* 1989;20:81-83
7. Hilal SK, Michaelson WJ, Driller J, Leonhard E. Magnetically guided devices for vascular exploration and treatment: laboratory and clinical investigations. *Radiology* 1974;113:529-540
8. Zeitlhofer J, Feldner G, Heimberger K, Mayr N, Samec P. Transarterielles EEG bei superselektiver zerebraler Angiographie. *Z EEG-EMG* 1990;21:70-72
9. Pampiglione G, Kerridge J. EEG abnormalities from the temporal lobe studied with sphenoidal electrodes. *J Neurol Neurosurg Psychiatry* 1956;19:117-129
10. Cooper R, Winter AL, Crow HJ, Walter WG. Comparison of subcortical, cortical and scalp activity using chronically indwelling electrodes in man. *Electroenceph Clin Neurophysiol* 1965;18:217-228
11. Pfurtscheller G, Cooper R. Frequency dependence of the transmission of the EEG from cortex to scalp. *Electroenceph Clin Neurophysiol* 1975;38:93-96
12. Hashimoto I, Ishiyama Y, Yoshimoto T, Nemoto S. Brain stem auditory evoked potentials recorded directly from human brain stem and thalamus. *Brain* 1981;104:841-859
13. Fox AJ, Pelz DM, Lee DH. Brain AVM embolisation: influence of amytal test and transient deficit on surgical management. *Neuroradiology* 1991;33:187-189
14. Jack CR, Nichols DA, Sharbrough FW, Marsh WR, Petersen RC. Selective posterior cerebral artery amytal test for evaluating memory function before surgery for temporal lobe seizure. *Radiology* 1988;168:787-793