



## Discover Generics

Cost-Effective CT & MRI Contrast Agents



WATCH VIDEO

# AJNR

### **Acute internal jugular vein thrombosis associated with pseudoabscess of the retropharyngeal space.**

L B Poe, J V Manzione, J J Wasenko and R M Kellman

*AJNR Am J Neuroradiol* 1995, 16 (4) 892-896

<http://www.ajnr.org/content/16/4/892>

This information is current as  
of June 21, 2025.

---

# Acute Internal Jugular Vein Thrombosis Associated with Pseudoabscess of the Retropharyngeal Space

Lawrence B. Poe, James V. Manzione, John J. Wasenko, and Robert M. Kellman

**Summary:** We present four patients in whom evidence of edema or a pseudomass in the retropharyngeal space was found on CT scans obtained after thrombosis of the internal jugular vein. The clinical condition of one patient led to surgery, which documented the sterility of the retropharyngeal space despite the CT appearance of an inflammatory process. The CT findings, which are confusing initially, are found to be typical in retrospect.

**Index terms:** Thrombosis, venous; Neck, abscess; Neck, computed tomography

There are many causes of internal jugular vein thrombosis, including placement of an indwelling catheter, caudal extension from the dural sinuses, and reaction to adjacent infection. Regardless of the cause, the computed tomographic (CT) findings are characteristic and have been well described (1–4). These findings include the presence of edema or inflammation in the adjacent soft tissues, typically the adjacent parapharyngeal spaces. A less well known associated finding is the presence of edema or fluid in the retropharyngeal space. This association is not discussed or described in CT-era articles on internal jugular vein thrombosis (1–7). We undertook a study to examine the characteristics of this edema and found four cases of acute internal jugular vein thrombosis in which a pseudomass was created in the retropharyngeal space that could be mistaken for an abscess.

## Methods

Over a 12-month period, a prospective study was conducted at our institution to examine the relationship of internal jugular vein thrombosis to abnormalities in the retropharyngeal space. Four patients were discovered to have CT evidence of acute internal jugular vein occlusion

and widening and decreased density of the retropharyngeal space. All patients were scanned within 72 hours of developing symptoms. Two patients had follow-up studies. One patient underwent exploratory surgery. Not all cases of internal jugular vein thrombosis were included in the study because some patients were initially evaluated with ultrasound.

## Case Reports

### Case 1

A 49-year-old man had a right upper lobectomy for bronchogenic carcinoma leading to thoracic outlet syndrome 10 years previously. For 3 days he had had night sweats, rigors, and neck swelling and a sensation of a foreign body in the back of his throat. He denied having recent pharyngeal trauma. On physical examination, marked cutaneous inflammation and induration of the right anterior cervical and submandibular triangles were seen. He did not have palpable adenopathy. Oral examination revealed posterior pharyngeal swelling without signs of pharyngitis. His white blood cell count was elevated with a left shift. A CT scan of the neck with intravenous contrast administration revealed low density of the lumen of the right internal jugular vein with enhancement of the vasa vasorum consistent with acute internal jugular vein thrombosis. The vessel was occluded from the level of the hyoid bone caudally. Edema was present in the prestyloid and retrostyloid parapharyngeal spaces. The upper retropharyngeal space was widened and of low density (Fig 1). A focal area of fluid density was present prominently in the retropharyngeal space at the level of the oropharynx creating an anteriorly bulging convex margin with a distinctive masslike quality. No classical suppurative adenitis was apparent. A right supraclavicular mass that was thought to be fibrotic was identified. A culture was obtained, and the patient was placed on intravenous antibiotics; pain and swelling increased over the next 24 hours. The patient underwent surgical exploration for a presumptive diagnosis of retropharyngeal abscess. At surgery, no

---

Received June 2, 1993; accepted after revision September 7.

Presented at the 31st Annual Meeting of the American Society of Neuroradiology, May 1993, Vancouver, Canada.

From the Department of Radiology, Division of Neuroradiology (L.B.P., J.V.M., J.J.W.), and Department of Otolaryngology (R.M.K.), State University of New York Health Science Center at Syracuse.

Address reprint requests to John J. Wasenko, MD, Department of Radiology, State University of New York Health Science Center at Syracuse, 750 E Adams St, Syracuse, NY 13210.

AJNR 16:892–896, Apr 1995 0195-6108/95/1604–0892 © American Society of Neuroradiology

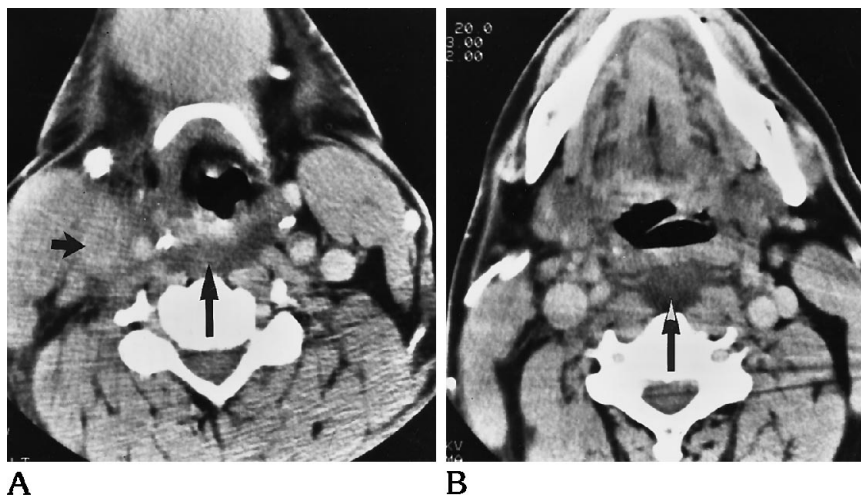


Fig 1. 49-year-old man with fever and neck pain. Axial CT scan (A) at the level of the hyoid displays right internal jugular vein thrombosis (*short arrow*) with edema in the adjacent carotid space. A low-density mass-like appearance is appreciated in the retropharyngeal space (*long arrow*) at this level and higher at the level of the tip of the epiglottis in B.

pus or free fluid was found in the retropharyngeal space, which was simply edematous. This area was cultured. The majority of the thrombosed internal jugular vein was excised because the walls were friable. The thrombus was also cultured. The patient slowly improved and was discharged from the hospital several days later. Various tests and cultures were negative for aerobic and anaerobic bacteria, fungi, and tuberculosis. It was therefore difficult to be absolutely positive that the patient's symptoms were attributable to a deep neck infection.

#### Case 2

A 2½-year-old twin girl with complex congenital heart disease had undergone a thoracotomy for a Glenn procedure 1 month previously. Persistently elevated pressures in the superior vena cava were associated with right ventricular outlet obstruction. She had had fever and swelling of the face for 2 hours. Her white cell count was elevated. Physical examination revealed induration and tenderness over the anterior triangles bilaterally, right greater than left. There was no palpable adenopathy. No pharyngitis was obvious. A CT scan of the neck after intravenous contrast administration showed findings consistent with acute right internal jugular vein thrombosis from the skull base to the thoracic inlet. The fat planes of the prestyloid and retrostyloid parapharyngeal spaces were hazy or obliterated by edema. Fluid density was seen in a widened retropharyngeal space, having a more focal mass effect at the oropharyngeal and hypopharyngeal levels (Fig 2). She was placed on antibiotics and dramatically improved within 12 hours. No anticoagulation was administered. Repeat CT 4 days later showed no change in the occluded internal jugular vein, but edema of the retropharyngeal space was less noticeable. The rapid improvement was thought to be inconsistent with fasciitis.

#### Case 3

A 55-year-old man had had Hodgkin disease for 4 years. Adenocarcinoma of the colon had developed re-

cently, and he was found to have lung and liver metastases. An indwelling venous catheter was placed in the left subclavian vein for chemotherapy access. The patient did not have radiation therapy. Five weeks later, he had acute swelling and pain in the left side of the neck. Physical examination revealed a full but nontender left anterior cervical space. He did not have palpable neck nodes. His oral cavity and oropharynx were unremarkable. He was afebrile and his white blood count was normal. A CT scan of the neck after contrast administration showed that the internal jugular vein was acutely thrombosed from the skull base to the brachiocephalic vein. Edema was found in the retropharyngeal space above the level of the cricoid cartilage. At the level of the hypopharynx, focal widening was present (Fig 3). The patient was treated with anticoagulation (heparin/warfarin), and progressive improvement occurred.

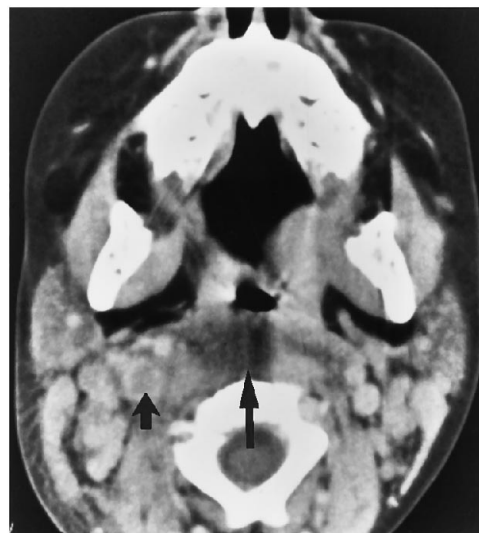


Fig 2. 2½-year-old girl with chronically elevated venous pressures. Prominent masslike edema in the retropharyngeal space is obvious (*long arrow*) at the level of the upper oropharynx. Note right internal jugular vein thrombosis (*short arrow*).

## Case 4

A 60-year-old woman had a 1-month history of adenocarcinoma of the lung. Two weeks earlier, an indwelling catheter ("infusaport") was placed in the right subclavian vein for chemotherapy maintenance. She presented 12 hours after sudden painful swelling of the right side of the neck. Her physical examination was pertinent for lack of fever or pharyngitis. The right anterior cervical triangle and lateral neck were tender and indurated. Her white cell count was normal. A CT scan showed large nodes bilaterally in the supraclavicular fossae with compression of the right internal jugular vein. The right internal jugular vein was occluded superiorly to the mandibular angle. Prominent fluid density in the parapharyngeal region and widening of the retropharyngeal space were similar to our other cases (Fig 4). She was treated with anticoagulation (heparin/warfarin) and 3000 cGy of external beam radiation therapy with steady improvement in physical signs. Repeat CT 2 weeks later failed to corroborate thrombus resolution. However, the abnormality in the retropharyngeal space had resolved. Prominent posterior cervical and anterior epidural veins were now apparent indicating venous collateral recruitment.

## Discussion

The many causes of internal jugular vein thrombosis include complication of surgical procedures, presence of an indwelling venous catheter, tumor invasion, hypercoagulability, caudal extension of sigmoid sinus thrombosis, compression from adjacent tumor or nodes, reaction to an adjacent infectious process, and direct venous injection (1-4).

Since being described by Patel and Brennan (1), the findings in this abnormality have been refined to include the presence of edema or

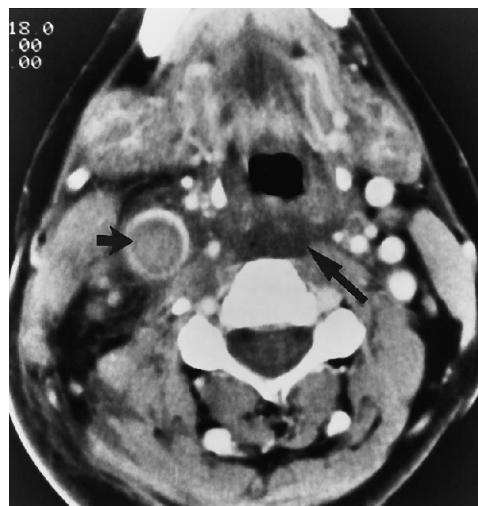

Fig 4. 60-year-old woman who presented with neck swelling 2 weeks after indwelling catheter placement. The right internal jugular vein is thrombosed and enlarged (*short arrow*). Masslike edema is in the retropharyngeal space (*long arrow*). In all patients, edema in the retropharyngeal space was not readily observable below the level of the cricoid cartilage.

inflammation in the soft tissues of the neck, which on CT are manifest most commonly as a haziness in the deep fat of the prestyloid and retrostyloid parapharyngeal spaces to the level of the hyoid bone and the carotid space below the hyoid bone (1-4). We describe four patients with acute internal jugular vein thrombosis who had edema in the retropharyngeal space that created a convex bulge to the anterior border of the space simulating a hypodense mass on CT. The focal edema present within the retropharyngeal space of all four of our patients had a masslike quality that could mimic an abscess (or cellulitis) in the proper clinical setting. This was particularly true in our first case, where clinical worsening precipitated surgery, in which an abscess was not found. It is perplexing that no infection could be definitely documented in this patient, even within the vein thrombus, which should have been theoretically "isolated" from the antibiotics that had just been initiated. Signs of internal jugular vein thrombosis and infection can overlap, especially in children. This is succinctly illustrated in case 2, in which symptoms practically resolved within 12 hours, much too early for resolution of a neck fasciitis.

In their textbook, Mancuso and Hanafée (8) apparently first described the CT findings in a case of edema or fluid within the retropharyngeal space after internal jugular vein thrombosis. The clinicians in this case thought the pa-

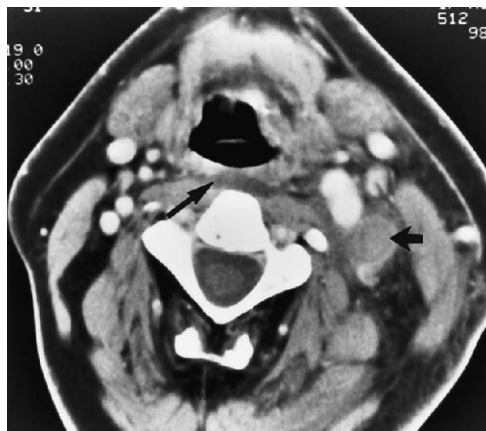

Fig 3. 55-year-old man with Hodgkin disease 5 weeks after placement of deep venous catheter for chemotherapy. Only a small amount of edema is revealed in the retropharyngeal space (*long arrow*). Left internal jugular vein thrombosis (*short arrow*).

tient had an abscess (Mancuso A, personal communication). An unpublished review of retropharyngeal adenitis indicated that suppurative adenitis often can lead to edema in the retropharyngeal space, which may be mistaken for an abscess (Barreda R, Mancuso AA, Stringer S, "Suppurative Retropharyngeal Lymphadenitis: Medical or Surgical Disease?," presented at the 76th Annual Meeting of the Radiologic Society of North America, Chicago, November 1990). In their review of the imaging of the retropharyngeal space, Davis et al (9) mentioned five cases of edema within the retropharyngeal space after internal jugular vein thrombosis. The single case illustrated in their article was very similar to all four of ours. They did not comment on the potential conflict this finding specifically raised in their patient. Diagnostic confusion was created in two of our patients when the possibility of focal infection was raised clinically. To our knowledge, no cases have been previously reported in which the retropharyngeal space has been surgically explored in this situation. Given the number of cases that we confronted in a relatively short period of time, it is probable that fruitless exploration of the retropharyngeal space has been carried out in other institutions to the frustration of our surgical and radiologic colleagues.

The retropharyngeal space lies in the midline of the neck between the pharynx (visceral space) and the prevertebral space (10). (In common usage in radiology, the retropharyngeal space also includes another potential space contained by the deep layer of deep cervical fascia that is called the "danger space" [11]). The alar fascia, which is the anterior and lateral split of the deep layer of deep cervical fascia, is the anterior border of the danger space and contributes to the combined fascial layers making up the carotid sheath (10). Because the completeness of the fascial coverings and thus the relative communication of these spaces with each other and the parapharyngeal space are debatable (9, 10, 12-14), the ability of free fluid to pass among the spaces either directly or along vascular or lymphatic sheaths is debatable. Whether or not fluid (or pus) can freely move among these spaces is not the most important issue in this setting, as we do not believe this "pathologic process" in the retropharyngeal space is created by free-flowing fluid.

What is the origin of the "edema" within the space? Davis et al (9) have postulated that ve-

nous obstruction leads to a transudation of fluid, ostensibly from the prominent posterior pharyngeal venous plexus (15) that drains into the deep jugular system. This is a very appealing concept. However, the findings in our patient who underwent exploratory surgery mitigate against the presence of frank fluid. It is likely that most of this edema is contained in the interstitial spaces. Edema within the retropharyngeal space was not present in any of our patients below the level of the larynx, but tended to track from the level of the nasopharynx through the hypopharynx. The pseudomass created by this edema was most obvious at the oro-hypopharyngeal junction. Even in the patients with a more caudally thrombosed internal jugular vein (cases 1 and 4), edema was not visible within the retropharyngeal space below the level of the cricoid cartilage. The work of Grodinsky and Holyoke (10) in the 1930s suggested that there is a looser, less adherent arrangement of fibrofatty tissue in the supralaryngeal retropharyngeal space as compared with the sublaryngeal retropharyngeal space. The relative narrowing of this space before its termination at the T1-2 level can be substantiated by anatomic dissections today (Benzo C, personal communication). This difference in the "tightness" and amount of areolar tissue between the upper and lower retropharyngeal spaces likely contributes to the location of this edema. Free fluid or pus would not be expected to be limited in its spread within the space. Lymphatic engorgement might also contribute. Although the lymphatics of the retropharyngeal space may considerably fibrose after childhood (12), metastases to this area from squamous cell carcinoma is well documented (16), indicating patency in adults. The lymphatics in the retropharyngeal space are more apparent in the suprahyoid than in the infrahyoid retropharyngeal space (17, 18), and the lack of significant edema below the laryngeal level in all of our patients might suggest that our findings are partly attributable to lymphatic distension acting as an early collateral pathway for transudate.

In summary, we document the presence of a low-attenuation pseudomass in the retropharyngeal space on CT in four patients who had acute internal jugular vein thrombosis that could be mistaken for an infectious process. Three of our patients almost certainly did not have cellulitis or infection. Surgical exploration

in one patient failed to reveal a frank fluid collection. The CT findings, potentially confusing initially, are found to be typical in retrospect. This association of findings has been previously described but is not widely known. Even though our opinion is based on only four cases, we think that if examined carefully, the CT scan will reveal at least a small amount of edema within the retropharyngeal space in most cases of internal jugular vein thrombosis and is to be expected. Because most cases of internal jugular vein thrombosis today are associated with an indwelling venous catheter, one should strongly consider that retropharyngeal (and parapharyngeal) swelling is the result of internal jugular vein thrombosis and not that the internal jugular vein thrombosis is the result of cellulitis or abscess in the retropharyngeal space. Knowledge of the coincidence of these findings can prevent misdiagnosis and misdirection of therapy.

## Acknowledgments

We thank Maria Pembroke for transcription. We also thank Anthony A. Mancuso, MD, and Camillo Benzo, PhD (Distinguished Teaching Professor of Anatomy at State University of New York Health Science Center at Syracuse), for contributions to our understanding of the pathology and anatomy in the neck, which aided the preparation of this manuscript.

## References

1. Patel S, Brennan J. Diagnosis of internal jugular vein thrombosis by computed tomography. *J Comput Assist Tomogr* 1981;5:197-200
2. Fishman EK, Pakter RL, Gayler BW, Wheeler PS, Siegelman SS. Jugular venous thrombosis: diagnosis by computed tomography. *J Comput Assist Tomogr* 1984;8:963-968
3. Cohen JP, Persky MS, Reede DL. Internal jugular vein thrombosis. *Laryngoscope* 1985;95:1478-1482
4. Albertyn LE, Alcock MK. Diagnosis of internal jugular vein thrombosis. *Radiology* 1987;162:505-508
5. Merhar GL, Colley DP, Clark RA, Herwig SR. Computed tomographic demonstration of cervical abscess and jugular vein thrombosis. *Arch Otolaryngol Head Neck Surg* 1981;17:313-315
6. Chowdhury K, Bloom J, Black MJ, Al-Noury K. Spontaneous and nonspontaneous internal jugular vein thrombosis. *Head Neck* 1990;12:168-173
7. Braun IF, Hoffman JC Jr, Malko JA, Pettigrew RI, Dannels W, Davis PC. Jugular venous thrombosis: MR imaging. *Radiology* 1985;157:357-360
8. Mancuso AA, Hanafee WN. *Computed Tomography and Magnetic Resonance Imaging of the Head and Neck*. 2nd ed. Baltimore: Williams and Wilkins, 1985:224
9. Davis WL, Harnsberger HR, Smoker WRK, Watanabe AS. Retropharyngeal space: evaluation of normal anatomy and diseases with CT and MR imaging. *Radiology* 1990;174:59-64
10. Grodinsky M, Holyoke EA. The fasciae and fascial spaces of the head, neck and adjacent regions. *Dev Dyn* 1938;63:367-408
11. Harnsberger HR. The retropharyngeal space and the prevertebral space of the suprahyoid neck. In: Harnsberger HR, ed. *Handbook in Radiology: Head and Neck Imaging*. Chicago: Mosby-Year Book, 1990:89-111
12. Paonessa D, Goldstein JC. Anatomy and physiology of head and neck infections. *Otolaryngol Clin North Am* 1976;9:561-580
13. Batsakis JG, Sneige N. Parapharyngeal and retropharyngeal space diseases. *Ann Otol Rhinol Laryngol* 1989;98:320-321
14. Silver AJ, Mawad ME, Hilal SK, Sane P, Ganti SR. Computed tomography of the carotid space and related cervical spaces: Part I: Anatomy. *Radiology* 1983;150:723-728
15. Platzer W, ed. *The Cervical Visceral Tract: Pernkopf Anatomy*. Vol. 1, 3rd ed. Baltimore: Urban and Schwarzenberg, 1989
16. Mancuso AA, Harnsberger HR, Muraki AS, Stevens MH. Computed tomography of cervical and retropharyngeal lymph nodes: normal anatomy, variants of normal and applications in staging head and neck cancer. *Radiology* 1983;148:709-714
17. Davis WL, Smoker WRK, Harnsberger HR. The normal and diseased infrahyoid retropharyngeal, danger, and prevertebral spaces. *Semin Ultrasound CT MR* 1991;12:241-256
18. Som PM. Lymph nodes of the neck. *Radiology* 1987;165:593-600