



Discover Generics

Cost-Effective CT & MRI Contrast Agents



FRESENIUS
KABI

WATCH VIDEO

AJNR

Vascular reserve in chronic cerebral ischemia measured by the acetazolamide challenge test: comparison with positron emission tomography.

T Nariai, R Suzuki, K Hirakawa, T Maehara, K Ishii and M Senda

AJNR Am J Neuroradiol 1995, 16 (3) 563-570

<http://www.ajnr.org/content/16/3/563>

This information is current as of June 7, 2025.

Vascular Reserve in Chronic Cerebral Ischemia Measured by the Acetazolamide Challenge Test: Comparison with Positron Emission Tomography

Tadashi Nariai, Ryuta Suzuki, Kimiyoshi Hirakawa, Taketoshi Maehara, Kenji Ishii, and Michio Senda

PURPOSE: To determine the value of the acetazolamide challenge test with stable xenon-enhanced CT (Xe CT) for making therapeutic decisions in patients with chronic cerebrovascular disease. **METHODS:** We compared the Xe CT-measured acetazolamide response with various measures obtained by positron emission tomography. We performed both a positron emission tomographic scan and a Xe CT study in 11 patients with chronic cerebral ischemic diseases within a 1-week interval. An increase of cerebral blood flow after injection of acetazolamide was expressed as Δ AT. Regional cerebral blood flow, cerebral oxygen metabolism, oxygen extraction fraction, and cerebral blood volume were measured with oxygen-15-labeled gases by positron emission tomography. **RESULTS:** In low-cerebral blood flow regions, decreased Δ AT was accompanied by a significant elevation of oxygen extraction fraction and cerebral blood volume, compared with oxygen extraction fraction and cerebral blood volume in regions of normal Δ AT. Plotting of regional data indicated that Δ AT was significantly dependent on oxygen extraction fraction and cerebral blood volume. The area of decreased vascular reserve determined by the Xe CT image corresponded to the area of "misery perfusion" determined by positron emission tomography. **CONCLUSION:** The acetazolamide challenge test with Xe CT may offer an alternative to positron-emission tomography in detecting lesions with elevated oxygen extraction fraction and cerebral blood volume (misery perfusion) that result from chronic hemodynamic stress.

Index terms: Brain, ischemia; Brain, blood supply; Positron emission tomography; Xenon

AJNR Am J Neuroradiol 16:563-570, March 1995

Determining the degree of hemodynamic stress in chronic cerebral ischemic disease is clinically important. Ischemic cerebral tissue in need of increased blood flow (ie, tissue under hemodynamic stress) should be distinguished from tissue with a reduction in blood flow caused by a decrease in metabolic demand, because the former condition can be reversed

by treatment to increase blood flow (1). One of the most reliable indicators of hemodynamic stress is "misery perfusion," which is characterized by an elevated oxygen extraction fraction (2, 3) or an elevated cerebral blood volume (4), as determined by positron emission tomography. However, the limited number of positron-emission tomography facilities has made it difficult to determine these values routinely.

Another way of evaluating hemodynamic stress is to determine the degree of vascular reserve by using a tolerance test, such as the carbon dioxide (5, 6) or acetazolamide response (7-9), in combination with a clinically applicable quantitative measurement of regional cerebral blood flow.

Stable xenon-enhanced computed tomography (Xe CT) is a clinical two-dimensional, quantitative cerebral blood flow measurement method whose reliability has been established (10, 11). The combined use of the acetazol-

Received September 7, 1993; accepted after revision July 27, 1994.

This study was supported by Grants-in-Aid for Scientific Research 04770972 (Dr Nariai) and 04557062 (Dr Hirakawa) from the Ministry of Education, Science, and Culture of Japan and by the Japan Brain Foundation (Dr Suzuki).

From the Department of Neurosurgery, Tokyo Medical and Dental University (T.N., R.S., K.H., T.M.); and Positron Medical Center, Tokyo Metropolitan Institute of Gerontology (K.I., M.S.).

Address reprint requests to Tadashi Nariai, MD, Department of Neurosurgery, Tokyo Medical and Dental University, 1-5-45 Yushima, Bunkyo-ku, Tokyo 113, Japan.

AJNR 16:563-570, Mar 1995 0195-6108/95/1603-0563

© American Society of Neuroradiology

TABLE 1: Characteristics of 11 patients with chronic cerebral ischemic disease

Case	Age, y/ Sex	Diagnosis	Symptom	Cerebral Lesion	Comment
1	10/F	Moyamoya disease	TIA	None	
2	14/F	R ICA occlusion	TIA	None	
3	16/F	Moyamoya disease	TIA	None	Examined before and after surgery
4	20/F	Moyamoya disease	TIA	None	
5	28/F	Moyamoya disease	TIA	None	
6	43/M	Moyamoya disease + AVM	TIA	Parietal AVM	
7	49/M	L MCA occlusion	Hemiparesis	Frontotemporal infarction	Gradual worsening
8	54/F	Moyamoya disease	Hemianopsia	Occipital infarction	Gradual worsening
9	60/M	R cervical ICA occlusion	TIA	Frontal infarction	
10	61/F	R cervical ICA occlusion	TIA	Multiple lacunar infarction	
11	68/F	Bilateral cervical ICA stenosis	TIA	Multiple lacunar infarction	

Note.—TIA indicates transient ischemic attack; ICA, internal carotid artery; MCA, middle cerebral artery; and AVM, arteriovenous malformation.

amide challenge test with Xe CT has proved useful in assessing hemodynamic stress in patients with cerebrovascular disease (12–14). We examined patients with chronic cerebral ischemic disease by both the Xe CT acetazolamide challenge test and positron emission tomography to determine how a positron emission tomography measurement that indicates hemodynamic stress corresponds to a decreased vascular reserve, as defined by the Xe CT acetazolamide challenge test, and whether an abnormal acetazolamide response of ischemic tissue can be quantified and made clinically applicable.

Subjects and Methods

We studied 11 patients with chronic cerebrovascular disease. Their characteristics and diagnoses are presented in Table 1. Nine patients had symptoms of transient ischemic attack; they were examined at least 2 months after the last transient ischemic attack symptoms. Two patients showed clinical deterioration without a clear onset and had cortical infarction, but their symptoms and CT findings had been stable for at least 2 months before examination. We assumed that the cerebral circulation was stable during the (approximately) 1-week examination period. Twelve comparative analyses with Xe CT and positron emission tomography were performed in the 11 patients within a 1-week interval. One of the patients with Moyamoya disease was examined before and after successful bypass surgery.

In the regional cerebral blood flow study with Xe CT we used a 4-minute wash-in and 3-minute wash-out method

with 30% stable Xe gas (15–17). Intraarterial Xe gas concentration was estimated with a scanning expiration tube. Carbon dioxide concentration in the expired gas was also monitored. To prepare the cold Xe gas, commercially distributed pure Xe gas (Xenopure, Teisan, Tokyo, Japan) was mixed with room air by use of an automatic Xe gas inhalator (Xetron-V, Anzai So-Gyo, Tokyo, Japan) to yield a 30% concentration. The acetazolamide challenge test was performed by administering acetazolamide, 20 mg/kg intravenously (Diamox, Lederle Japan, Tokyo, Japan), and the Xe CT measurement of cerebral blood flow was performed 15 minutes later. The regional increase in cerebral blood flow was expressed as ΔAT (milliliters per minute per 100 cm³ of brain).

Our analysis program produces a cerebral blood flow map of two axial sections, usually one that includes the basal nuclei and another that includes the upper margin of the lateral ventricles. Regions of interest were identified on a plain CT image, either in the cortex or in the basal nuclei, based on arterial blood supply (18). These regions of interest were transferred to the cerebral blood flow map to obtain anatomic specificity. When low-density lesions were included by use of this protocol, these regions of interest were excluded from the analysis. Between 7 and 16 regions of interest from each patient were analyzed.

The positron emission tomography study was performed with a Headtome-IV scanner (Shimadzu, Kyoto, Japan). An arterial catheter was inserted into the radial artery for blood sampling. The transmission data were acquired with a rotating germanium-68 rod source for attenuation correction. Measurements of regional cerebral blood flow, cerebral oxygen metabolism, and oxygen extraction fraction were measured with continuous inhalation

of carbon dioxide labeled with oxygen 15 and molecular oxygen labeled with oxygen 15 and continuous measurement of arterial blood and plasma activity and a table-lookup technique (19–21). Regional cerebral blood volume was measured by a 3-minute inhalation of carbon dioxide labeled with oxygen 15 (22, 23). The oxygen extraction fraction and cerebral oxygen metabolism were corrected for cerebral blood volume (24). Regions of interest with close anatomic correspondence to those used in the Xe CT study were transferred from the appropriate positron emission tomography sections of the cerebral blood flow image to the cerebral blood volume, cerebral oxygen metabolism, and oxygen extraction fraction images. To obtain a normal standard for positron emission tomography measurement in our institute, data from nine adults without any lesion on magnetic resonance were analyzed. The positron emission tomography data were analyzed by use of an image analysis software system, Dr. View, working on Stellar GS2000 (Asahi Kasei, Tokyo, Japan).

All data were expressed as mean \pm SD. Data were evaluated statistically by Student's *t* test, analysis of variances, Dunnett's *t* test for multiple comparison (25), and a simple regression analysis. Statistical significance was defined as $P < .05$.

Results

All the regions of interest obtained were grouped into categories according to positron emission tomography–derived cerebral blood flow. Regions with a cerebral blood flow of more than 40 mL/min per 100 cm³ for adults (aged at least 20 years) or 50 mL/min per 100 cm³ for children (aged at least 16 years) were defined as normal cerebral blood flow regions ($n = 64$). Regions with a cerebral blood flow of less than 30 mL/min per 100 cm³ for adults or 40 mL/min per 100 cm³ for children were defined as ischemic regions ($n = 27$). Other regions were called borderline regions ($n = 54$). Ischemic regions and borderline regions were grouped together as low-flow regions ($n = 81$). Different values of cerebral blood flow were used for adults and children, because normal cerebral blood flow values for 10- to 16-year-old children are 20% to 60% greater than those for adults (26).

Normal cerebral blood flow regions had a Δ AT of 18.7 ± 20.0 mL/min per 100 cm³ calculated from 64 regions. This mean value was close to the previously published mean Δ AT observed in healthy volunteers examined with Xe CT under a similar study protocol (14). For the following analysis, the lower margin of the 99% confidence range of the mean (Δ AT = 12.0

TABLE 2: Comparison of positron emission tomography and Xe CT acetazolamide challenge test in low-perfusion regions (cerebral blood flow < 40 mL/min per 100 cm³ for adults; cerebral blood flow < 50 mL/min per 100 cm³ for children)

Xe CT	Positron Emission Tomography	
	Oxygen Extraction Fraction	Cerebral Blood Volume, %
Normal vascular reserve Δ AT ≥ 12 (mL/min per 100 cm ³)	$0.43 \pm 0.05^*$	$4.3 \pm 1.1^\dagger$
Decreased vascular reserve Δ AT < 12 (mL/min per 100 cm ³)	$0.47 \pm 0.05^*$	$5.0 \pm 1.6^\dagger$

Note.—Values are mean \pm SD.

* $P = .002$.

† $P = .02$.

mL/min per 100 g) was used as the threshold to separate decreased vascular reserve from normal vascular reserve.

Low-cerebral blood flow regions were separated into those with a normal and those with a decreased vascular reserve, using Δ AT of 12 as the threshold. The oxygen extraction fraction and cerebral blood volume of regions with decreased vascular reserve (Δ AT < 12) were significantly elevated ($P = .002$ and $.02$, respectively), compared with those of regions with normal vascular reserve (Δ AT ≥ 12) (Table 2). The dependence of Δ AT on the oxygen extraction fraction can be demonstrated clearly because of the small SD of the oxygen extraction fraction. When the ischemic and borderline regions were separated into regions of normal vascular reserve and decreased vascular reserve, using Δ AT of 12 mL/min per 100 cm³ as the threshold, the oxygen extraction fraction of ischemic and borderline regions with decreased vascular reserve were significantly greater than the oxygen extraction fraction of the normal cerebral blood flow regions (analysis of variance and Dunnett's *t* test; Fig 1). However, the oxygen extraction fraction of ischemic and borderline regions with normal vascular reserve was not different from the oxygen extraction fraction of the normal cerebral blood flow regions (analysis of variance; Fig 1).

Correlations between Δ AT and oxygen extraction fraction and between Δ AT and cerebral blood volume were examined for ischemic cerebral blood flow regions (Fig 2). Significant linear correlations between Δ AT and oxygen extraction fraction ($r = -.65$; $P = .001$) and between Δ AT and cerebral blood volume ($r =$




Fig 1. Comparison of regional oxygen extraction fraction (OEF) (mean \pm SD) between regions of decreased vascular reserve ($\Delta AT < 12$ mL/min per 100 cm³) and regions of normal vascular reserve ($\Delta AT \geq 12$ mL/min per 100 cm³). Among regions of decreased vascular reserve, oxygen extraction fraction values of ischemic and borderline cerebral blood flow regions were significantly higher than those of normal cerebral blood flow (CBF) regions. However, among regions of normal vascular reserve, the oxygen extraction fraction was not different among the three groups (normal cerebral blood flow, >40 mL/min per 100 cm³ for adults, >50 mL/min per 100 cm³ for children; ischemic cerebral blood flow, <30 mL/min per 100 cm³ for adults, <40 mL/min per 100 cm³ for children; borderline cerebral blood flow, other regions).

$-.50$; $P = .02$) were observed. Using this plot, we examined the predictive value of regional ΔAT for detecting regions possessing elevated oxygen extraction fraction or cerebral blood volume. The oxygen extraction fraction (mean \pm SD) in nine adults without an intracerebral lesion was 0.44 ± 0.046 (indicated as the




Fig 2. Correlations between ΔAT of ischemic regions (<30 mL/min per 100 cm³ for adults, <40 mL/min per 100 cm³ for children) and oxygen extraction fraction (OEF) (left) and cerebral blood volume (CBV) (right). The result of simple regression analysis is indicated by solid lines. The correlation coefficient between oxygen extraction fraction and ΔAT was $-.65$ and that between cerebral blood volume and ΔAT was $-.50$; both were at a significant level ($P = .001$ and $.02$, respectively). Dotted lines indicate ΔAT of 0 and ΔAT of 10. The shaded area indicates mean \pm SD of normal adults for oxygen extraction fraction and cerebral blood volume.

shaded area in Fig 2, left). Eight of nine regions (89%) with ΔAT of 10 or greater had oxygen extraction fraction less than the mean \pm SD of normal adults. Five of six regions (83%) with ΔAT less than 0 had oxygen extraction fraction more than the mean \pm SD of normal adults (Fig 2, left). The cerebral blood volume (mean \pm SD) obtained from normal adults was $3.3 \pm 1.0\%$. Ten of 12 regions (83%) with ΔAT less than 10 had cerebral blood volume more than the mean \pm SD of normal adults (Fig 2, right). Therefore, the threshold value of ΔAT of 10 may be used to screen for hemodynamic ischemia, and a threshold value of ΔAT of 0 may be useful to detect the region of severe hemodynamic stress.

When we could observe the area of elevated oxygen extraction fraction and cerebral blood volume in positron emission tomography images (misery perfusion) (Fig 3A), it usually corresponded well to the area of decreased vascular reserve detected by the Xe CT acetazolamide challenge test (Fig 3B).

Discussion

In this study, we demonstrated that the degree of decreased vascular response to the intravenous injection of acetazolamide in patients with chronic cerebrovascular disease correlates closely with positron emission tomography measurements that describe misery perfusion. This observation indicates that the use of a combination of acetazolamide challenge and Xe CT may offer an alternative to positron emission tomography for detecting hemodynamic ischemia.

In treating ischemic cerebrovascular disease, it is important to determine to what degree the surviving cerebral tissue is under hemodynamic stress, because it may be possible to protect this tissue against an impending cerebral infarction (27, 28) by increasing cerebral blood flow through use of appropriate medical and surgical treatment (1, 3, 4, 29). A surgical procedure that is based on this premise, extracranial-intracranial bypass surgery, was not superior to medical treatment when candidates for it were chosen based solely on clinical symptoms and angiography, without evidence of hemodynamic stress (30, 31). This issue of candidate selection remains controversial (32); a cooperative study to examine the effects of extracranial-intracranial bypass in patients with evi-




Fig 3. A, The positron emission tomography images of a 28-year-old woman with Moyamoya disease (case 5 in Table 1). The right frontal and parietal areas had abnormally increased oxygen extraction fraction and cerebral blood volume (misery perfusion), indicated as areas between two *arrows* in each axial section.

B, Images of Xe CT acetazolamide challenge test of the same patient as in A. Axial sections corresponding to positron emission tomography images in A were demonstrated. The area between two *arrowheads* in each section had an impaired response to acetazolamide challenge. Part of this area had a ΔAT less than 0 (steal phenomenon). This area corresponds to the area of misery perfusion demonstrated by positron emission tomography images in A.

dence of hemodynamic stress is being conducted in Japan (33). However, in a prospective randomized study, carotid endarterectomy added significant benefit to treatment even without consideration of hemodynamic stress (34–36). Presumably, this procedure not only increases cerebral blood flow but also removes sources of emboli.

In formulating a therapeutic strategy for a patient with chronic cerebrovascular disease, it should be determined whether the ischemic symptoms of patients are hemodynamic in origin, with the brain in need of an increased blood flow (3, 4), or thrombotic in origin (37, 38). It is also essential to determine whether the cerebral tissue already has a decreased metabolism and does not require additional blood flow (1). Our experience suggests that a transient ischemic attack caused by hemodynamic stress, as is often observed in patients with moyamoya disease (39) and in some patients with chronic cerebral ischemia of atherosclerotic origin, can be reversed by performing extracranial-intracranial bypass surgery (39). Therefore, an imaging tool to examine both the resting blood flow and the degree of regional hemodynamic stress should be applied to a large population for whom this procedure is being contemplated.

Although increased oxygen extraction fraction (2, 3) and cerebral blood volume (4), as determined by positron emission tomography, are reliable indicators of the existence of hemodynamic stress, they are not widely available to most clinicians because of the limited number of positron emission tomography facilities. Another way of evaluating hemodynamic stress is to examine the degree of vascular reserve by means of a tolerance test, such as the response to carbon dioxide (5, 6) or to acetazolamide (7–9). Use of such a tolerance test for the prospective evaluation of each patient requires a quantitative, quickly repeated cerebral blood flow measurement. Single-photon emission CT is more accessible than positron emission tomography but may not be useful, because the most popular cerebral blood flow imaging tracers for single-photon emission CT (technetium-99m hexamethyl-propyleneamine oxime and iodine-123 inosine monophosphate) do not give quantitative cerebral blood flow data, and the long half-lives of technetium-99m and iodine-123 make repeated examinations difficult.

However, stable Xe CT is a useful technique, because it uses a diffusion tracer, and the calculation of cerebral blood flow is based on the Kety and Schmidt equation (40) with correc-

tion for the regional partition coefficient of Xe gas (15–17). It seems reasonable, therefore, to assume that the linearity of measured cerebral blood flow in both ischemic and nonischemic cerebral tissues make it possible to examine increases in cerebral blood flow in tolerance quantitatively. A problem that previously discouraged the use of Xe CT in daily clinical practice was the difficulty of obtaining the expensive Xe gas. Xe gas was approved as an ethical drug for use in Japan by the Ministry of Health and Welfare in April 1992, and an 8-L can of Xe gas is available commercially (Xenopure, Teisan). Since then, the number of clinical institutions that can perform Xe CT studies has increased rapidly. In Japan, the Xe CT study has the potential to become the most accessible quantitative method of cerebral blood flow measurement because of the abundance of CT units. Thus, a method for evaluating the degree of hemodynamic stress in ischemic cerebral disease may be within the reach of most clinicians.

Although our analyses demonstrated the feasibility of using the acetazolamide tolerance test, some caution in interpreting the results is indicated. Our studies were performed in patients with chronic disease. Their compensatory mechanisms have presumably reached a stable condition with a maximal dilation of the cerebral vascular beds, leading to a decreased vascular response and increased cerebral blood volume (4). At the same time, their efficiency in using oxygen has already increased (2, 3), leading to an increase in the oxygen extraction fraction. It does not necessarily follow that the decreased vascular reserve detected with acetazolamide and misery perfusion represent the same phenomenon. It is unclear whether this correspondence is present in acute ischemia, in which compensatory mechanisms may work differently. To interpret the result of acetazolamide response in acute ischemic events, some other reference procedure is needed, because comparison between the two techniques described in this study is difficult to make in acute events.

There is also uncertainty about the mechanism by which acetazolamide dilates the cerebral vessels (7, 41), and the reported increases of blood flow in normal cerebral vessels caused by injection of acetazolamide vary (7, 8, 12, 14, 42, 43). Although our analyses indicate that the acetazolamide response rate depends on both

oxygen extraction fraction and cerebral blood volume, the correlation coefficient is small, probably because of the variable acetazolamide response rate and the interpatient variation. Therefore, caution should be used when using the results of the acetazolamide challenge test in clinical decision making. However, it can be used to demonstrate that a certain region is under hemodynamic stress by defining the lower limit of the normal response rate. *We consider regions with a ΔAT of less than 10 mL/min per 100 cm³ to be hemodynamically ischemic and, therefore, in need of further examination.* If we are to use the acetazolamide challenge test alone for making decisions about radical treatment, we use a threshold value of ΔAT of 0. Regions with ΔAT of less than 0 (steal phenomenon) were found to be areas with high stroke rates in a prospective study (44) and areas that improved after indirect extracranial-intracranial bypass surgery (39), so use of this threshold seems justified.

Care should be taken in using the acetazolamide tolerance test with nonquantitative cerebral blood flow measurement methods, because the inconsistency of the acetazolamide response in nonischemic tissue may lead to a false-positive interpretation of the presence of hemodynamic stress in ischemic tissue. *If one is to use the acetazolamide tolerance test as a clinical tool, quantitative cerebral blood flow analysis should also be used.*

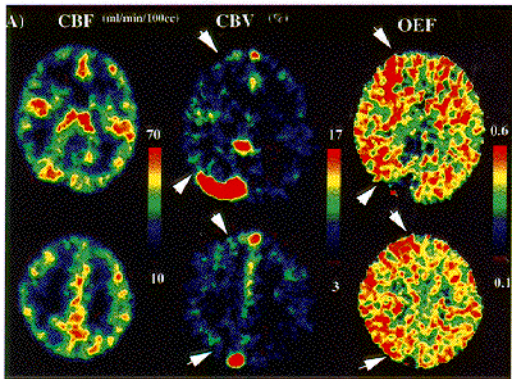
In conclusion, the results of the acetazolamide tolerance test, combined with quantitative cerebral blood flow analysis, can be used to determine whether cerebral tissues suffer from hemodynamic ischemia. Such information can be used to develop the optimal treatment strategy for patients with chronic cerebral ischemic disease. The stable Xe CT technique may present an alternative to positron emission tomography in detecting lesions with elevated oxygen extraction fraction and cerebral blood volume (misery perfusion) that result from chronic hemodynamic stress.

References

1. Ackerman RH, Correia JA, Alpert NM, et al. Positron imaging in ischemic stroke disease using compounds labelled with oxygen 15: initial results of clinicophysiology correlations. *Arch Neurol* 1981;38:537–543

2. Baron J, Bousser M, Comar D, Soussaline F, Castaigne P. Non-invasive tomographic study of cerebral blood flow and oxygen metabolism in vivo. *Eur Neurol* 1981;20:273-284
3. Baron JC, Bousser MG, Rey A, Guillard A, Comar D, Castaigne P. Reversal of focal "misery-perfusion syndrome" by extra-intracranial arterial bypass in hemodynamic cerebral ischemia: a case study with ^{15}O positron emission tomography. *Stroke* 1981;12:454-459
4. Gibbs JM, Wise RJS, Leenders KL, Jones T. Evaluation of cerebral perfusion reserve in patients with carotid-artery occlusion. *Lancet* 1984;i:310-314
5. Herold S, Brown MM, Frackowiak RSJ, Mansfield AO, Thomas DJ, Marshall J. Assessment of cerebral haemodynamic reserve: correlation between PET parameters and CO_2 reactivity measured by intravenous ^{133}Xe injection technique. *J Neurol Neurosurg Psychiatry* 1988;51:1045-1050
6. Norrving B, Nilsson B, Risberg J. rCBF in patients with carotid occlusion: resting and hypercapnic flow related to collateral pattern. *Stroke* 1982;13:155-162
7. Vorstrup S, Henriksen L, Paulson OB. Effect of acetazolamide on cerebral blood flow and cerebral metabolic rate for oxygen. *J Clin Invest* 1984;74:1634-1639
8. Vorstrup S, Brun B, Lassen NA. Evaluation of the cerebral vasodilatory capacity by the acetazolamide test before EC-IC bypass surgery in patients with occlusion of the internal carotid artery. *Stroke* 1986;17:1291-1298
9. Sullivan HG, Kingsbury TB IV, Morgan ME, et al. The rCBF response to Diamox in normal subjects and cerebrovascular disease patients. *J Neurosurg* 1987;67:525-534
10. Yonas H, Darby JM, Marks EC, Durham SR, Maxwell C. CBF measurement by Xe-CT: approach to analysis and normal values. *J Cereb Blood Flow Metab* 1991;11:716-725
11. Johnson DW, Stringer WA, Marks MP, Yonas H, Good WF, Gur D. Stable xenon CT cerebral blood flow imaging: rationale for and role in clinical decision making. *AJNR Am J Neuroradiol* 1991;12:201-213
12. Rogg J, Rutigliano M, Yonas H, Johnson DW, Pentheny S, Latchaw RE. The acetazolamide challenge: imaging techniques designed to evaluate cerebral blood flow reserve. *AJNR Am J Neuroradiol* 1989;10:803-810
13. Tarr RW, Johnson DW, Rutigliano M, et al. Use of acetazolamide-challenge xenon CT in the assessment of cerebral blood flow dynamics in patients with arteriovenous malformations. *AJNR Am J Neuroradiol* 1990;11:441-448
14. Yamashita T, Kashiwagi S, Nakano S, et al. The effect of EC-IC bypass surgery on resting cerebral blood flow and cerebrovascular reserve capacity studied with stable Xe-CT and acetazolamide test. *Neuroradiology* 1991;33:217-222
15. Touho H, Karasawa J, Nakagawara J, et al. Mapping of local cerebral blood flow by computerized tomography with inhalation of stable xenon and the curve-fitting method of analysis. *Radiology* 1988;168:207-212
16. Suzuki R, Hiratsuka H, Matsushima Y, et al. Cerebral blood flow measurement by means of xenon-enhanced CT with brief-xenon-inhalation methods (in Japanese). *Prog Comput Tomogr* 1986;8:139-144
17. Kalender WA, Polacin A, Eidloth H, Kashiwagi S, Yamashita T, Nakano S. Brain perfusion studies by xenon-enhanced CT using washin/washout study protocols. *J Comput Assist Tomogr* 1991;15:816-822
18. Kretschmann H-J, Weinrich W. *Neuroanatomy and Cranial Computed Tomography*. New York: Thieme, 1986
19. Frackowiak RS, Lenzi GL, Jones T, Heather JD. Quantitative measurement of regional cerebral blood flow and oxygen metabolism in man using ^{15}O and positron emission tomography: theory, procedure, and normal values. *J Comput Assist Tomogr* 1980;4:727-736
20. Sadato N, Yonekura Y, Senda M, et al. PET autoradiographic method with continuous inhalation of O-15 gas: theoretical analysis and comparison with conventional steady state method. *J Nucl Med* 1993;34:1672-1680
21. Senda M, Buxton RB, Alpert NM, et al. The ^{15}O steady-state method; correction for variation in arterial concentration. *J Cereb Blood Flow Metab* 1988;8:681-690
22. Eichling JO, Raichle ME, Grubb RL, Larson KB, Ter-Pogossian MM. In vivo determination of cerebral blood volume with radioactive oxygen-15 in the monkey. *Circ Res* 1975;37:707-714
23. Grubb RL, Raichle ME, Higgins CS, Eichling JO. Measurement of regional cerebral blood volume by emission tomography. *Ann Neurol* 1978;4:322-328
24. Lammertsma AA, Jones T, Frackowiak RS, Lenzi GL. Correction for the presence of intravascular oxygen extraction ratio in the brain. *J Cereb Blood Flow Metab* 1983;3:416-424
25. Dunnett C. New tables for multiple comparisons with a control. *Biometrics* 1964;20:482-491
26. Chiron C, Raynaud C, Maziere B, et al. Changes in regional cerebral blood flow during brain maturation in children and adolescents. *J Nucl Med* 1992;33:696-703
27. Yamauchi H, Fukuyama H, Fujimoto N, Nabatame H, Kimura J. Significance of low perfusion with increased oxygen extraction fraction in a case of internal carotid artery stenosis. *Stroke* 1992;23:431-432
28. Heiss WD, Huber M, Fink GR, et al. Progressive derangement of periinfarct viable tissue in ischemic stroke. *J Cereb Blood Flow Metab* 1992;12:193-203
29. Powers WJ, Martin WRW, Herscovitch P, Raichle ME, Grubb RL Jr. Extracranial-intracranial bypass surgery: hemodynamic and metabolic results. *Neurology* 1984;34:1168-1174
30. Peerless SJ. Indications for the extracranial-intracranial arterial bypass in light of the EC-IC bypass study. *Clin Neurosurg* 1986;33:307-326
31. The EC-IC Bypass Study Group. Failure of extracranial-intracranial arterial bypass to reduce the ischemic stroke. *N Engl J Med* 1985;313:1191-1200
32. Sundt T. Was the international randomized trial of EC/IC arterial bypass representative of the population at risk? *N Engl J Med* 1987;316:814-816
33. Yonekawa Y. Research project on effectiveness of the cerebrovascular reconstructive surgery (in Japanese). *Jpn J Stroke* 1991;13:454-457
34. NASCET Collaborators. Beneficial effect of carotid endarterectomy in symptomatic patients with high-grade carotid stenosis. *N Engl J Med* 1991;325:445-453
35. European Carotid Surgery Trialists' Collaborative Group. MRC European surgery trial: interim results for symptomatic patients with severe (70-99%) or with mild (0-29%) carotid stenosis. *Lancet* 1991;337:1235-1243
36. Barnett HJ, Barnes RW, Clagett GP, Ferguson GG, Robertson JT, Walker PM. Symptomatic carotid artery stenosis: a solvable problem. North American Symptomatic Carotid Endarterectomy Trial (editorial). *Stroke* 1992;23:1048-1053
37. Barnett HJM, Peerless SJ, Kaufmann JCE, Path FRC. "Stump" of internal carotid artery: a source for further cerebral embolic ischemia. *Stroke* 1978;9:448-456

38. Barnett HJM. Delayed cerebral ischemic episodes distal to occlusion of major cerebral arteries. *Neurology* 1978;28:769-774
39. Nariai T, Suzuki R, Matsushima Y, et al. Surgically induced angiogenesis to compensate for hemodynamic cerebral ischemia. *Stroke* 1994;25:1014-1021
40. Kety S, Schmidt C. The determination of cerebral blood flow in man by the use of nitrous oxide in low concentrations. *Am J Physiol* 1945;143:53-56
41. Laux BE, Raichle ME. The effect of acetazolamide on cerebral blood flow and oxygen utilization in the rhesus monkey. *J Clin Invest* 1978;62:585-592
42. Bonte FJ, Devous MD Sr, Reisch JS. The effect of acetazolamide on regional cerebral blood flow in normal human subjects as measured by single-photon emission computed tomography. *Invest Radiol* 1988;23:564-568
43. Sorteberg W, Lindgaard K-F, Rootwelt K, et al. Effect of acetazolamide on cerebral artery blood velocity and regional cerebral blood flow in normal subjects. *Acta Neurochir (Wien)* 1989;97:139-145
44. Yonas H, Smith HA, Durham SR, Penhney SL, Johnson DW. Increased stroke risk predicted by compromised cerebral blood flow reactivity. *J Neurosurg* 1993;79:483-489



A

B)

Resting CBF

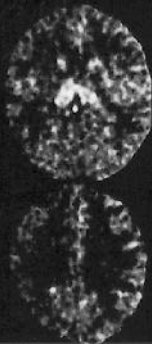
Acetazolamide Challenge

(ml/min/100cc)

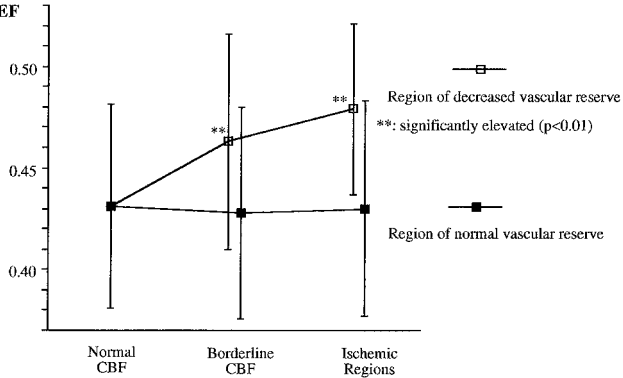
70

0

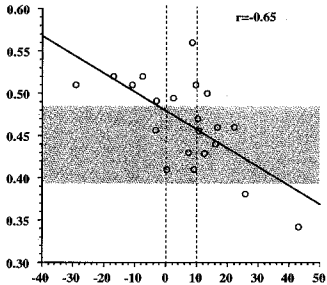
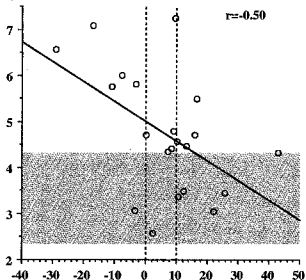
B



OEf



OEF

 ΔAT (ml/min/100 cc)CBV
(%) ΔAT (ml/min/100 cc)