



Clinically unsuspected venous malformations limited to the submandibular triangle: CT findings.

M J Fine, R A Holliday and J T Roland

AJNR Am J Neuroradiol 1995, 16 (3) 491-494
<http://www.ajnr.org/content/16/3/491>

This information is current as of July 23, 2025.

Clinically Unsuspected Venous Malformations Limited to the Submandibular Triangle: CT Findings

Martin J. Fine, Roy A. Holliday, and J. Thomas Roland

PURPOSE: To present the CT characteristics of histologically confirmed venous vascular malformations limited to the submandibular triangle in patients without clinical stigmata of venous vascular malformations. **METHODS:** The clinical records and CT scans of five women with venous vascular malformations limited to the submandibular triangle were reviewed. Patients ranged from 39 to 70 years of age. None of the patients had a history of malignant tumors. All patients presented with a solitary suprahyoid neck mass. None of the patients demonstrated cutaneous manifestations of venous vascular malformation. **RESULTS:** Contrast-enhanced CT scans in all five patients demonstrated a lobulated, heterogeneously enhancing, well-circumscribed solid mass, separable from the submandibular gland. Areas of contrast enhancement within each mass were isodense to the internal jugular vein in four of five cases. Only two of five lesions demonstrated focal calcifications. Excisional biopsy (two patients) demonstrated pathologic features compatible with venous vascular malformation. Fine needle aspirations (three patients) yielded venous blood or blood-tinged fluid. **CONCLUSIONS:** Venous vascular malformations may present as isolated neck masses in adults without typical clinical stigmata. Clues to the CT diagnosis include a lobulated appearance to the mass with intense but heterogeneous contrast enhancement. This appearance, in combination with results of fine needle aspiration, may be sufficiently diagnostic to preclude excisional biopsy.

Index terms: Veins, abnormalities and anomalies; Neck, computed tomography

AJNR Am J Neuroradiol 16:491-494, March 1995

Venous vascular malformations of the head and neck typically present with clinical stigmata, which suggest the diagnosis. These include skin discoloration, dilated subcutaneous vessels, and compressibility. The role of imaging is usually limited to the delineation of these commonly multicompartmental lesions. We present the CT characteristics of venous vascular malformations limited to the submandibular triangle in five adult women without clinical stigmata of venous vascular malformation.

Materials and Methods

The clinical records and contrast-enhanced computed tomographic (CT) scans of five women with venous vascular malformations limited to the submandibular triangle were retrospectively reviewed. Patients ranged from 39 to 70 years of age. None of the patients had a history of malignant tumor. The patients had initially noticed the mass between 1 month and 2 years before seeking medical attention. One patient had a history of recent local trauma and noted that the mass subsequently enlarged. Only one patient had intermittent pain.

All patients presented with a solitary mass in the suprahyoid neck, and two lesions were minimally tender upon physical examination. None of the lesions were either pulsatile or compressible. There were no associated skin changes in any of the patients. Saliva flowed freely from the ipsilateral Wharton's duct in all patients, and no calculi were palpated. Initial clinical diagnoses included reactive nodal mass, submandibular gland neoplasm, and branchial cleft cyst.

All CT scans included of contiguous 3-mm or 5-mm thick axial images through the suprahyoid neck. A total of 200 mL of iodinated contrast (iothalamate meglumine, Conray 43, Malinckrodt, St Louis, Mo) was administered,

Received February 24, 1994; accepted after revision August 12.

This paper was presented at the American Society of Head and Neck Radiology annual meeting, May 16, 1993, Vancouver, British Columbia, Canada.

From the Departments of Radiology (M.J.F., R.A.H.) and Otolaryngology (J.T.R.), New York University Medical Center, New York.

Address reprint requests to Roy A. Holliday, MD, Department of Radiology, New York University Medical Center, 560 First Ave, New York, NY 10016.

AJNR 16:491-494, Mar 1995 0195-6108/95/1603-0491

© American Society of Neuroradiology




Fig 1. Axial contrast-enhanced CT scan demonstrates a well-circumscribed lobulated mass (*arrowhead*) lateral to the left submandibular gland (see "Discussion"). Note the focal areas of intense contrast enhancement. This image is typical of all venous vascular malformations in our series.

either as a 50-mL hand-delivered bolus followed by rapid drip infusion, or via power injector with infusion rates of 2 mL/s for 30 seconds, and 1 mL/s thereafter.

Results

Contrast-enhanced CT scans in all five patients demonstrated a single, heterogeneously enhancing, well-circumscribed solid lobulated mass, separate from the submandibular gland. Areas of contrast enhancement within each mass were isodense to the internal jugular vein in four of five cases (Fig 1); the remaining mass demonstrated less intense enhancement. Only two of five lesions demonstrated focal calcifications (Fig 2).

In one patient, images were obtained both during and 10 minutes after the bolus phase of intravenous contrast administration. In this patient, the areas of intense contrast enhancement observed during contrast injection (Fig 3A) show enhancement on the delayed images, which is hypointense compared with the internal jugular vein (Fig 3B).

Fine needle aspirations, performed in three patients, yielded venous blood or blood-tinged fluid. Surgical excision, performed in two pa-




Fig 2. Axial contrast-enhanced CT scan of venous vascular malformation (*arrowhead*) demonstrates dense central focus of calcium within a lobulated, heterogeneously enhancing mass.

tients, demonstrated "organizing thrombus with features of varix." The three patients who did not undergo surgical excision have been followed for an average of 31 months (range, 28 to 34 months) without progression of symptoms.

Discussion

Venous vascular malformations are part of the spectrum of vascular malformations that includes capillary and cavernous hemangiomas, arterial and capillary malformations, and lymphovascular malformations (6, 9). Lesions are classified as vascular malformations or hemangiomas, depending on the presence of cellular proliferation. Hemangiomas have been shown to incorporate radiolabeled thymidine, indicative of active cellular proliferation. Vascular malformations do not demonstrate active cellular proliferation (6).

Vascular malformations may be characterized as high-flow (arteriovenous malformations) or low-flow (venous, capillary, lymphatic malformations) lesions (9, 6). Venous vascular malformations are composed mainly of dilated veins with a variable capillary component. Venous vascular malformations usually present in children and young adults. Most authors be-




Fig 3. A, Axial contrast-enhanced CT images obtained during the bolus phase of intravenous contrast administration. The venous vascular malformation (*arrowhead*) shows areas of enhancement equivalent to that of the left internal jugular vein (*small arrowhead*).

B, CT images obtained 10 minutes after the bolus phase of contrast administration. The areas of early intense enhancement appear to have "washed out" on the delayed image.

lieve that they are present at birth but may not become apparent until later in life. They may expand as a result of trauma (as in one of our patients), sepsis, hormonal changes, or changes in venous pressure (6, 9). Low-flow vascular malformations have typical clinical stigmata that include skin discoloration, dilated subcutaneous vessels, pulsatility, and compressibility (9, 10). Higher-flow lesions may have an associated bruit (9). Venous vascular malformations have previously been referred to as *noninvoluting cavernous hemangiomas* in both clinical and radiologic literature (6).

The major role of sectional imaging of clinically apparent venous vascular malformation is to define the extent of the lesion (10, 11). Previous reports of CT scanning in venous vascular malformation have noted peripheral or diffuse contrast enhancement approximating that of adjacent large blood vessels (14). Associated similarly enhancing curvilinear structures may also be apparent (14). Rapid wash in and wash out of contrast has been reported using dynamic CT (15). CT may also demonstrate phleboliths in larger lesions (14).

The submandibular triangle normally contains the submandibular gland, lymph nodes, and fat (12, 13). The differential diagnosis of submandibular triangle masses generally includes submandibular gland inflammation or neoplasm, lymph node, and cystic masses including branchial cleft cyst and ranula (10–13). The distinction between inflammatory and neoplastic processes is usually apparent by history and physical exam. In cases of suspected

sialadenitis, the patient may be placed on oral antibiotics and followed up in several weeks (10). Fine needle aspiration may be performed in masses felt to be noninflammatory (11).

Sectional imaging of the suprahyoid neck is performed to determine whether a palpable mass represents an enlarged submandibular gland and whether calculi are present. If the mass is believed to represent an enlarged node clinically, imaging may be performed to search for additional adenopathy and for a primary head and neck tumor.

The magnetic resonance (MR) imaging characteristics of venous vascular malformations reflect the histologic variations in these lesions. Venous vascular malformations are approximately isointense to skeletal muscle on T1-weighted spin-echo images and are characteristically hyperintense on T2-weighted spin-echo images (1, 2, 4, 8). Focal areas of signal inhomogeneity may represent areas of fibrosis, fatty tissue, calcification, or thrombosis (4). Gradient-echo T2*-weighted images demonstrate signal loss when compared with T2-weighted spin echo images (1). Signal voids in regions of more rapid blood flow are a variable feature, as are high signal areas representing slower flow (4). Enhancement within vascular channels has been reported after gadopentate dimeglumine administration (1).

The patients in our series are unusual in that they were all adults who presented without clinical stigmata of venous vascular malformation. The clinical impressions at first presentations

were of submandibular gland neoplasm, nodal mass, and branchial cleft cyst.

All of these lesions in our series demonstrated heterogeneous enhancement after iodinated contrast administration. Portions of each lesion enhanced intensely, approximately isodense to the internal jugular vein. Each of the lesions appeared on CT as solitary, well-circumscribed lobulated masses. Calcifications were noted in only two patients.

The majority of solid extraglandular submandibular triangle masses are nodal in origin. Aspiration of blood, or blood-tinged fluid, from a venous vascular malformation in the submandibular triangle might lead the clinician to suspect occult nodal malignancy. The CT appearance of venous vascular malformations in our series differs from the typical CT appearance of metastatic squamous cell carcinoma. Lobular borders, intense contrast enhancement, and calcifications all would be unusual findings in metastatic squamous cell carcinoma. None of the venous vascular malformations in our series demonstrated central areas of hypodensity commonly identified in metastatic squamous cell carcinoma. Furthermore, the majority of cases of squamous cell carcinoma metastasizing to submandibular triangle lymph nodes arise within the oral cavity, an area easily accessible to clinical examination.

Lobular borders, intense contrast enhancement, and focal calcifications might be identified in a nodal metastases from thyroid carcinoma. The absence of similar-appearing masses in the infrahyoid neck or tracheoesophageal grooves would argue against a diagnosis of metastatic thyroid carcinoma; however, continued clinical monitoring would be necessary to confirm the diagnosis of venous vascular malformation. Continued clinical monitoring also would be necessary to exclude the possibility of tuberculous adenitis, another entity that might mimic the CT appearance of venous vascular malformation.

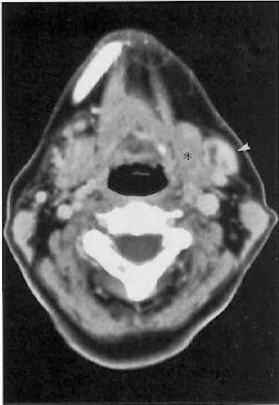Conclusions

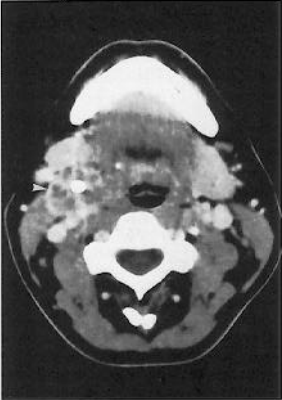Venous vascular malformations may present as isolated neck masses in adults without the

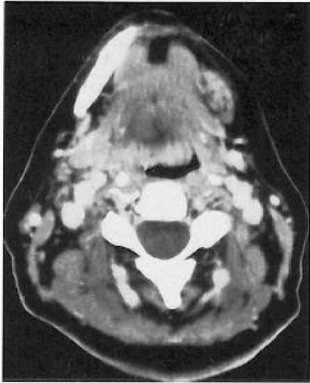
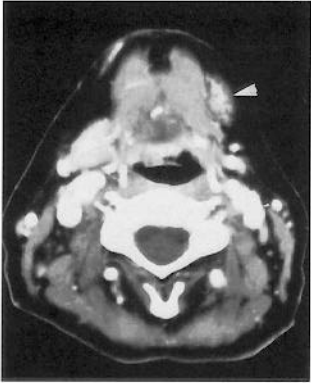clinical findings typically associated with vascular malformations. Clues to the CT diagnosis include lobulated contours, sharp borders, calcifications, and intense, heterogeneous enhancement with rapid contrast administration. The CT appearance of submandibular venous vascular malformations, in combination with results of fine needle aspiration, may be sufficiently diagnostic to defer excisional biopsy, provided close clinical observation is continued.

References

1. Meyer JS, Hoffer FA, Barnes PD, Mulliken JB. Biological classification of soft-tissue vascular anomalies: MR correlation. *AJR Am J Roentgenol* 1991;157:559-564
2. Gelbert F, Riche MC, Reizine D, et al. MR imaging of head and neck vascular malformations. *J Magn Reson Imaging* 1991;1:579-584
3. Itoh K, Nishimura K, Togashi K, et al. MR imaging of cavernous hemangioma of the face and neck. *J Comput Assist Tomogr* 1986;10(5):831-835
4. Kaplan PA, Williams SM. Mucocutaneous and peripheral soft-tissue hemangiomas: MR imaging. *Radiology* 1987;163:163-166
5. Totty WG, Murphy WA, Lee JKT. Soft-tissue tumors: MR imaging. *Radiology* 1986;160:135-141
6. Finn MC, Glowacki J, Mulliken JB. Congenital vascular lesions: clinical applications of a new classification. *J Pediatr Surg* 1983;18(6):894-900
7. Wolf GT, Daniel F, Krause CJ, Kaufman RS. Intramuscular hemangioma of the head and neck. *Laryngoscope* 1985;95:210-213
8. Buetow PC, Kransdorf MJ, Moser RP, Jelinek JS, Berrey BH. Radiologic appearance of intramuscular hemangioma with emphasis on MR imaging. *AJR Am J Roentgenol* 1990;154:563-567
9. Berenstein A, Lasjaunias P. *Surgical Neuroangiography*. Vol. 4. Berlin: Springer Verlag, 1992:387-397
10. Thawley SE, Panje WR, Batsakis JG, Linberg RD. *Comprehensive Management of Head and Neck Tumors*. Philadelphia: WB Saunders, 1987:1352, 1807
11. Paparella MM, Shumrick DA, Gluckman JL, Meyerhoff WL. *Otolaryngology*. Philadelphia: WB Saunders, 1991:25-37
12. Som PM, Bergeron RT. *Head and Neck Imaging*. 2nd ed. St Louis: Mosby, 1991:501-517; 562-563
13. Som PM, Bergeron RT. *Head and Neck Imaging*. 2nd ed. St Louis: Mosby, 1991:562-563
14. Levine E, Wetzel LH, Neff JR. MR imaging and CT of extrahepatic cavernous hemangiomas. *AJR Am J Roentgenol* 1986;147:1299-1304
15. Michael AS, Mafee MF, Valvassori GE, Tan WS. Dynamic computed tomography of the head and neck: differential diagnostic value. *Radiology* 1985;154:413-419







A

B