



## Discover Generics

Cost-Effective CT & MRI Contrast Agents



FRESENIUS  
KABI

WATCH VIDEO

# AJNR

## Magnetization transfer imaging of periventricular hyperintense white matter in the elderly.

K T Wong, R I Grossman, J M Boorstein, F J Lexa and J C McGowan

*AJNR Am J Neuroradiol* 1995, 16 (2) 253-258

<http://www.ajnr.org/content/16/2/253>

This information is current as  
of June 6, 2025.

# Magnetization Transfer Imaging of Periventricular Hyperintense White Matter in the Elderly

Kin T. Wong, Robert I. Grossman, Jeffrey M. Boorstein, Frank J. Lexa, and Joseph C. McGowan

**PURPOSE:** To characterize with magnetization transfer imaging the pathologic substrate of the nonspecific periventricular hyperintense white matter changes seen on T2-weighted images of elderly patients. **METHODS:** Twenty-one elderly patients with periventricular hyperintense white matter on T2-weighted MR images and eleven control subjects were studied using MT technique. Magnetization transfer ratios (MTRs) were calculated for the periventricular hyperintense white matter and normal-appearing white matter. These MTRs were correlated with histopathologic changes that have previously been reported as well as with established MTRs for other lesions. **RESULTS:** The MTRs (mean, 35.2; SD, 1.2) in the periventricular hyperintense white matter are lower than those in the normal white matter of the patient (mean, 40.8; SD, 1.4) and control (mean, 41.3; SD, 1.8) groups. These MTRs are much higher than those of demyelinating lesions but are similar to those of experimental lesions with just edema. **CONCLUSION:** Because MTR may reflect to some extent histopathologic changes and thus provide more specificity than conventional pulse sequences, the main pathologic substrate accounting for the lower MTR in periventricular hyperintense white matter is probably the increased water content in reactive astrocytes.

**Index terms:** White matter, periventricular; Age and aging; Magnetic resonance, tissue characterization

*AJNR Am J Neuroradiol* 16:253-258, February 1995

Periventricular white matter hyperintensity identified on T2-weighted magnetic resonance (MR) imaging is a common finding in routine clinical imaging of older patients. The reported frequency is about 30% in patients more than 60 years old (1). A number of investigators have postulated various explanations for this observation including atrophic perivascular demyelination (2), ischemia (3), and infarction and gliosis (4). The routine spin-echo pulse sequences used in MR imaging are highly sensitive in detecting these periventricular abnormalities, but their specificity is low. On the basis of conventional MR contrast, it is very difficult to differen-

tiate the various possible causes of periventricular hyperintense white matter, whether from destructive parenchymal lesions or just increased water content. Because definitive histopathologic correlation for periventricular hyperintense white matter is difficult to obtain (these findings are usually incidental), and because there is disagreement among the investigators who have pathologic correlations, our study was an attempt to evaluate this periventricular hyperintense white matter from another approach by using the magnetization transfer technique.

Magnetization transfer has recently been shown to be a useful technique that can provide a quantitative index, magnetization transfer ratio, that may reflect the underlying composition of tissue and thus potentially provide increased specificity over conventional spin-echo imaging (5-8). Recent reports have suggested that magnetization transfer may enable differentiation between edema and demyelination in multiple sclerosis patients (7), demonstrate occult white matter abnormalities that cannot be de-

---

Supported in part by a grant from the National Institutes of Health, RO1 NS29029-10A1.

Received April 26, 1994; accepted after revision July 29.

From the Department of Radiology, Hospital of the University of Pennsylvania, Philadelphia.

Address reprint requests to Robert I. Grossman, MD, Hospital of the University of Pennsylvania, Department of Radiology, 3400 Spruce St, Philadelphia, PA 19104.

*AJNR* 16:253-258, Feb 1995 0195-6108/95/1602-0253

© American Society of Neuroradiology

tected with spin-echo MR imaging (5), and provide a sensitive measure of early changes in wallerian degeneration (9). We hypothesize that magnetization transfer techniques may have a useful role in characterizing the pathologic substrate of the nonspecific periventricular white matter hyperintensity encountered in the elderly. In this study we measured the magnetization transfer ratios in these lesions and correlated them with both previously published measurements and with the various published pathologic substrates of these lesions.

## Subjects and Methods

All MR studies were performed with 1.5-T units and with a quadrature transmitter/receiver head coil. Magnetization transfer imaging was performed with a three-dimensional gradient-echo pulse sequence 106/5 (repetition time/echo time) with a flip angle of  $12^\circ$ . These parameters were chosen to minimize T1 and T2 weighting, thereby giving a proton-density contrast in the absence of magnetization transfer saturation pulses (10). The matrix used was  $256 \times 128$  for a total of 28 sections at 5 mm each. The field of view used was 22 cm. Partial saturation of the free water spins was achieved through incorporation of a 19-millisecond radio frequency pulse into each repetition time period. Two consecutive sets of axial images were obtained; the first set with saturation pulse off and the second set with radio frequency saturation on. The radio frequency pulse was in the shape of the sinc function, with an average field intensity equal to  $3.67 \times 10^{-6}$  T, and was applied at a frequency 2 kHz below water resonance (10). The approximate acquisition time for each set of images was 7.3 minutes. The magnetization transfer parameters used in our study are identical to those used by previous studies of multiple sclerosis and experimental allergic encephalomyelitis (7) and intracranial hemorrhage (11).

The amount of magnetization transfer was quantitated by calculation of the magnetic transfer ratio, defined as  $(M_0 - M_s)/M_0 \times 100$  (7).  $M_0$  and  $M_s$  represent the signal intensity of an area with the saturation off and on, respectively. This ratio indicates the percentage loss of signal intensity because of magnetization transfer.  $M_0$  and  $M_s$  values are calculated as the average of pixel intensities contained within  $0.04 \text{ cm}^2$  regions of interest.

The study group consisted of 21 elderly patients (13 men and 8 women) 55 to 84 years of age (mean, 71) who were referred for MR imaging for various reasons ranging from transient ischemic attacks to work-up of dementia. After the routine spin-echo T1-weighted and fast spin-echo T2-weighted images, magnetization transfer imaging was performed if the patient had periventricular white matter high signal abnormalities on the T2-weighted images. The patient was excluded if there was history of intracranial radiation, multiple sclerosis, or other known demyelinating diseases.




Fig 1. Mild periventricular hyperintense white matter. Fast spin-echo T2-weighted image shows patchy foci of high signal near the atria.

The patient group was subdivided into three grades of severity of periventricular hyperintensity: mild ( $n = 10$ ), moderate ( $n = 6$ ), or severe ( $n = 5$ ). *Mild* was defined as patchy foci of high signal along the atria of the lateral ventricles (Fig 1), *moderate* as a thin halo of high signal around the ventricles with confluent areas near the atria (Fig 2), and *severe* as a thicker halo of hyperintensity along the ventricles with diffuse confluent high-signal abnormalities extending from the ventricular lining almost to the corticomedullary junction (Fig 3). Twelve patients in this study group had at least one of the following cerebrovascular risk factors: hypertension, diabetes mellitus, smoking, and hyperlipidemia.




Fig 2. Moderate periventricular hyperintense white matter. Fast spin-echo T2-weighted image shows a thin halo of high signal around the ventricles with confluent areas near the atria.



Fig 3. Severe periventricular hyperintense white matter. Fast spin-echo T2-weighted image shows a thicker halo of high signal along the ventricles with diffuse confluent hyperintensity extending toward the corticomedullary junction.

For each patient, magnetization transfer ratios were calculated for 40 nonoverlapping 0.04-cm<sup>2</sup> regions of interest located in periventricular areas that had high-signal abnormalities on T2-weighted images. Twenty magnetization transfer ratio values were also computed in normal-appearing deep white matter in each patient to serve as internal controls. In addition, imaging was performed in a control group of 11 patients 28 to 77 years of age. Six of these subjects were healthy asymptomatic volunteers; the other 5 subjects were clinical patients with normal MR examinations. Forty magnetization transfer ratio values were calculated in the normal-appearing periventricular and other deep white matter for each control patient.

#### Statistical Analysis

The paired two-tail Student's *t* test was used to compare the magnetization transfer ratio values between the periventricular hyperintense white matter and the normal-appearing deep white matter within the same patients. The unpaired two-tail Student's *t* test was used to compare the magnetization transfer ratio values of the following data: (a) between the normal-appearing deep white matter of the study group and the control group; and (b) between the periventricular hyperintense white matter and the normal white matter of the control group. Both the unpaired two-tail Student's *t* test and the nonparametric Wilcoxon's signed-rank test were used to compare the magnetization transfer ratios between the patients with and those without cerebrovascular risk factors. The nonparametric Kruskal-Wallis test was used to analyze the three subgroups of patients with varying degree of periventricular hyperintensity. A *P* value of less than .05 was used to assign any significant difference.

TABLE 1: Mean magnetization transfer ratio values

	Periventricular Hyperintense White Matter	Normal White Matter
Study Group (n = 21)	35.2% (SD, 1.2)	40.8% (SD, 1.4)
Control Group (n = 11)		41.3% (SD, 1.8)

#### Results

The mean magnetization transfer ratio values for normal-appearing white matter in the elderly group of patients with periventricular hyperintensity and the control group are 40.83% (SD, 1.39; range, 38.9% to 42.8%), and 41.3% (SD, 1.80; range, 39.9% to 43.1%), respectively. These values do not show any statistical difference and are consistent with those values found in previous studies (7, 11).

The mean magnetization transfer ratio for the periventricular hyperintense white matter, among all the patients, is 35.2% (SD, 1.2) with a range from 33.2% to 37.1%; this is statistically lower (*P* = .001) than the magnetization transfer ratio of normal-appearing deep white matter (Table 1). This average magnetization transfer ratio value is approximately 14% less than the magnetization transfer ratio of normal-appearing white matter, but is much higher than values seen in multiple sclerosis lesions (average, 26.3%) (7).

There is no statistical difference of the magnetization transfer ratio values for the periventricular high signal white matter between the patients with cerebrovascular risk factors and the patients without them (*P* = .33 by Student's *t* test, *P* = .59 by Wilcoxon's rank test) (Table 2). In addition, no statistical correlation was found between the severity of the periventricular hyperintensity and the actual numerical magnetization transfer ratio values (*P* = .373) (Table 3).

TABLE 2: Mean magnetization transfer ratios of patients with and without cerebrovascular risk factors

	Periventricular White Matter	Normal White Matter
With risk factors (n = 12)	35.0% (SD, 1.3)	40.4% (SD, 1.5)
Without risk factors (n = 9)	35.5% (SD, 1.1)	41.4% (SD, 1.1)

**TABLE 3: Mean magnetization transfer ratios of patients with various degrees of periventricular hyperintensity**

	Periventricular White Matter	Normal White Matter
Mild (n = 10)	35.6% (SD, 1.1)	41.4% (SD, 1.0)
Moderate (n = 6)	35.0% (SD, 1.0)	40.1% (SD, 1.7)
Severe (n = 5)	34.5% (SD, 1.5)	40.7% (SD, 1.6)

## Discussion

Magnetization transfer imaging was initially demonstrated by Wolff and Balaban in 1989 (6). This technique potentially expands the measured parameters in an MR study beyond proton density, T1, and T2 by exploitation of the interactions between endogenous macromolecular components and components in the aqueous phase (6, 8, 12–15). Specifically, the exchange of protons between water and macromolecules provides a potential additional relaxation mechanism, leading to the characterization of the sample in terms of exchange constants and intrinsic relaxation times for the observed water protons as well as for protons bound to macromolecules. The magnetization transfer effect is induced by applying radio frequency irradiation such that protons bound to macromolecules will preferentially experience saturation, that is, their magnetization will be held at or near zero magnitude. A means of producing this effect is through the application of a series of off-resonance radio frequency pulses, as has been previously demonstrated (10). The magnetization transfer effect can also be demonstrated by continuous-wave off-resonance irradiation (6) or with a net zero-degree radio frequency pulse technique (16, 17). The exchange of partially saturated spins into the water proton "pool" decreases the observed magnetization of water protons, leading to hypointensity on the magnetization transfer image when compared with the equivalent image obtained without radio frequency saturation pulses. The reduction of intensity may be expressed in terms of a magnetization transfer ratio, giving a quantitative measurement. These magnetization transfer ratio values are reproducible but are also dependent upon the specific scanning parameters (18). In cerebral white matter, the cholesterol-containing lipid bilayer of myelin is postulated to be the major

macromolecule responsible for magnetization transfer (19).

Contrast in magnetization transfer imaging is difficult to interpret in that it may represent differences in exchange rates as well as relaxation times and proton densities. The magnetization transfer technique has been applied to several processes in the brain (5, 7, 9, 11) as well as to various parts in the body (16, 20, 21). Because magnetization transfer techniques can provide a numerical value, magnetization transfer ratio, that to some degree may reflect the underlying structural composition, we applied this technique to study the nonspecific periventricular hyperintense white matter.

Nonspecific punctate and confluent periventricular white matter high signal abnormalities have been reported to be present in 30% of patients older than age 60 years (1). A number of different studies have tried to determine the pathologic substrate accounting for this finding. Marshall et al studied postmortem specimens with periventricular high signal on MR. These investigators, on gross and microscopic pathologic examinations, found areas of infarction with necrosis, demyelination, and loss of axons. These infarcted areas were surrounded by reactive astrocytes and isomorphic gliosis, up to several centimeters away (4). Braffman et al correlated seven brain specimens with the MR and found areas of infarctions, gliosis, plaques of demyelination, and few other miscellaneous lesions to account for the hyperintense white matter foci (22). Fazekas et al suggested these periventricular hyperintensities are nonischemic in origin and on pathology represented areas of demyelination with associated subependymal gliosis (17). Meguro et al found patients with severe periventricular hyperintensity had reduced blood flow or ischemia (3).

We studied the magnetization transfer ratio in a cohort of patients with nonspecific high signal abnormalities on T2-weighted images in an attempt to correlate it with changes that have previously been reported. The goal of this work was to increase the specificity by the use of magnetization transfer ratio as well as by correlation of the magnetization transfer ratio with the various postulated pathologic substrates of periventricular hyperintense white matter. White matter is a well-differentiated and organized tissue composed mainly of myelin, neuron, and endothelial cells (23). Our average magnetization transfer ratio values of normal-

appearing white matter for the study and the control groups are 40.83% to 41.3%, respectively. These values are similar to those reported in other studies performed with the same scanning parameters, thus confirming their reproducibility (5, 7, 11). Dousset et al has shown that the magnetization transfer ratio values of normal white matter in guinea pigs are similar to those of humans (7). In addition, Lexa et al demonstrated similar magnetization transfer ratio values in feline white matter (9).

The mean magnetization transfer ratio for the periventricular hyperintense white matter is 35.2% (SD, 1.2%), representing a 14.4% decrease from the magnetization transfer ratio of normal deep white matter. The low standard deviation indicates that the underlying abnormality is similar in these patients. These values can be contrasted with the much lower average magnetization transfer ratio in multiple sclerosis lesions of 26.3% (approximately 38% decrease from baseline normal white matter) with a larger standard deviation of 6.0%, which presumably indicate different severity and age of demyelination, remyelination, and edema in these various lesions (7). In addition, these authors measured the magnetization transfer ratios in an animal model of experimental allergic encephalomyelitis and showed a mean value of about 37% (approximately 12% lower from baseline normal white matter). Histologically, these acute experimental allergic encephalomyelitis lesions have edema and inflammatory components, but no demyelination (7). Because the magnetization transfer imaging parameters used in this study are identical to those used by Dousset's study of multiple sclerosis and experimental allergic encephalomyelitis lesions, a direct comparison of the magnetization transfer ratio values is thus possible. Using Dousset's reported magnetization transfer ratio values as a guideline for these different lesions, we predict that white matter abnormalities with a magnetization transfer ratio around 35% would histologically resemble experimental allergic encephalomyelitis lesions more so than multiple sclerosis lesions, and thus probably have increased water content and only minimal demyelination. We therefore postulate that astrogliosis, which has increased water content, may be the major pathologic substrate in the periventricular hyperintense white matter.

Gliosis is one of the brain's limited responses to injury. This process involves proliferation of

fibrillary astrocytes with the formation of many glial fibers such as vimentin and specific glial fibrillary acidic protein (24). Detection of increased glial fibrillary acidic protein by immunoperoxidase stain (25) indicates that astrocytes are reactive (26). Marshall et al have found swollen glial fibrillary acidic protein-positive astrocytes up to several centimeters away from a smaller central area of infarction (4). These reactive astrocytes are associated with an increased water content, thus appearing hyperintense on T2-weighted images. The increased water content will decrease the amount of magnetization transfer by diluting the number of structural protons per unit volume of tissue, thus lowering the magnetization transfer ratio.

Ischemia without infarction has also been postulated as another explanation for periventricular hyperintensity (3, 4, 27). The deep white matter is particularly susceptible to ischemia because its blood is supplied by long penetrating end-arterial vessels (28–30). Brun and Englund termed these white matter lesions *incomplete infarcts*. These lesions did not have cavitation or necrosis and were characterized by demyelination, loss of axons and oligodendrocytes, and reactive gliosis (27).

Some investigators have shown that cerebrovascular risk factors are related to the severity of periventricular hyperintensity and other white matter lesions (3, 31, 32). We found no statistical difference in the magnetization transfer ratio values between the patients with risk factors and those patients without them. Similarly, there is no statistical correlation in the magnetization transfer ratio values among the three subgroups of patients with different degrees of periventricular hyperintensity. These data suggest that the underlying pathophysiology is similar in these patients, independent of cerebrovascular risk factors and severity of the abnormalities.

In summary, magnetization transfer ratios for white matter are highly reproducible values. The magnetization transfer ratio in periventricular hyperintense white matter of the elderly is lower than that in normal white matter, not as low as that in demyelinating lesions but similar to that in experimentally induced lesions with edema but without demyelination. We speculate that the main pathologic substrate accounting for the lower magnetization transfer ratio is the increased water content in reactive astrocytes, which could be secondary to isomorphic

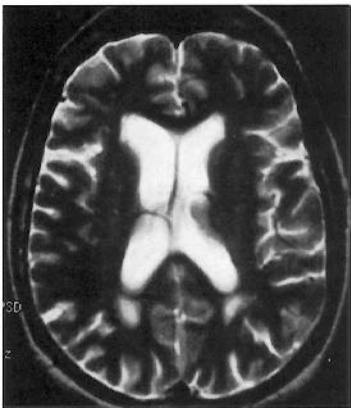
gliosis or ischemia. Demyelination itself probably contributes a smaller role to the decrease in magnetization transfer ratio. We believe that magnetization transfer ratio can reflect the underlying histopathology to a degree and thus provide possible additional specificity to conventional pulse sequences alone.

## Acknowledgment

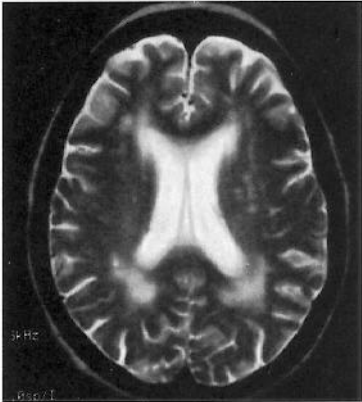
We thank Dr Jim Goins for his assistance in the statistical analysis of the data.

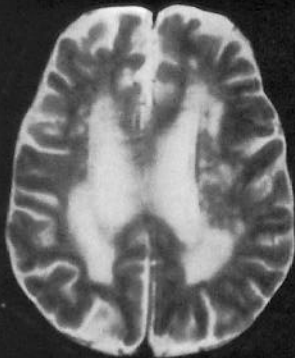## References

- Bradley WG, Waluch V, Brant-Zawadzki M, Yadley RA, Wyckoff RR. Patchy, periventricular white matter lesions in the elderly: a common observation during NMR imaging. *Noninvasive Med Imaging* 1984;1:35-41
- Kirkpatrick JB, Hayman LA. White-matter lesions in MR imaging of clinically healthy brains of elderly subjects: possible pathologic basis. *Radiology* 1987;162:509-511
- Meguro K, Hatazawa J, Yamaguchi T, et al. Cerebral circulation and oxygen metabolism associated with subclinical periventricular hyperintensity as shown by magnetic resonance imaging. *Ann Neurol* 1990;28:378-383
- Marshall VG, Bradley WG, Marshall CE, Bhoopat T, Rhodes RH. Deep white matter infarction: correlation of MR imaging and histopathologic findings. *Radiology* 1988;167:517-522
- Boorstein JM, Wong KT, Grossman RI, Bolinger L, McGowan JC. Metastatic lesions of the brain: imaging with magnetization transfer. *Radiology* 1994;191:799-803
- Wolff SD, Balaban RS. Magnetization transfer contrast (MTC) and tissue water proton relaxation in vivo. *Magn Reson Med* 1989;10:135-144
- Dousset V, Grossman RI, Ramer KN, et al. Experimental allergic encephalomyelitis and multiple sclerosis: lesion characterization with magnetization transfer imaging. *Radiology* 1992;182:483-491
- Balaban RS, Ceckler TL. Magnetization transfer contrast in magnetic resonance imaging. *Magn Reson Q* 1992;8:116-137
- Lexa FJ, Grossman RI, Rosenquist AC. MR of Wallerian degeneration in the feline visual system: characterization by magnetization transfer rate with histopathologic correlation. *AJNR Am J Neuroradiol* 1994;15:201-212
- McGowan JC, Schnall MD, Leigh JS. Magnetization transfer imaging with pulsed off-resonance saturation: variation in contrast with saturation duty cycle. *J Magn Reson Imaging* 1994;4:79-82
- Mittl RL, Gomori JM, Schnall MD, Holland GA, Grossman RI, Atlas SW. Magnetization transfer effects in MR imaging of in vivo intracranial hemorrhage. *AJNR Am J Neuroradiol* 1993;14:881-891
- Sappey-Marini D. High resolution NMR spectroscopy of cerebral white matter in multiple sclerosis. *Magn Reson Med* 1990;15:229-239
- Eng J, Ceckler TL, Balaban RS. Quantitative  $^1\text{H}$  magnetization transfer imaging in vivo. *Magn Reson Med* 1991;17:304-314
- Ceckler TL, Balaban RS. Tritium-proton magnetization transfer as a probe of cross relaxation in aqueous lipid bilayer suspensions. *J Magn Reson Imaging* 1991;93:572-588
- Edzes HT, Samulski RT. Cross-relaxation and spin diffusion in the proton NMR of hydrated collagen. *Nature* 1977;265:521-523
- Pike GB, Hu BS, Glover GH, Enzmann DR. Magnetization transfer time-of-flight magnetic resonance angiography. *Magn Reson Med* 1992;25:373-379
- Fazekas F, Kleinert R, Offenbacher H, et al. Pathologic correlates of incidental MRI white matter signal hyperintensities. *Neurology* 1993;43:1683-1689
- McGowan JC, Schnall MD, Leigh JS. Magnetization transfer imaging with pulsed off-resonance saturation: variation in contrast with saturation duty cycle. *J Magn Reson Imaging* 1994;4:79-82
- Fralix TA, Ceckler TL, Wolff SD, Simon SA, Balaban RS. Lipid bilayer and water proton magnetization transfer: effect of cholesterol. *Magn Reson Med* 1991;18:214-223
- Outwater E, Schnall MD, Braffman LE, Dinsmore BJ, Kressel HY. Magnetization transfer of hepatic lesions: evaluation of a novel contrast technique in the abdomen. *Radiology* 1992;182:535-540
- Morris GA, Freemont AJ. Direct observation of the magnetization exchange dynamics responsible for magnetization transfer contrast in human cartilage in vitro. *Magn Reson Med* 1992;28:97-104
- Braffman BH, Zimmerman RA, Trojanowski JQ, et al. Brain MR; pathologic correlation with gross and histopathology, II: hyperintense white matter foci in the elderly. *AJNR Am J Neuroradiol* 1988;9:629-636
- Raine CS. Demyelination disease. In: Davis RL, Robertson DM, eds. *Textbook of Neuropathology*. 2nd ed. Baltimore: Williams & Wilkins, 1991:535-620.
- Morris JH, Schoene WC. The nervous system. In: Robbins SL, Cotran RS, Kumar V, eds. *Pathologic Basis of Disease*. 3rd ed. Philadelphia: WB Saunders Co, 1984:1370-1274
- Rhodes RH. Diagnostic immunostaining of the nervous system. In: Taylor CT, ed. *Immunomicroscopy: A Diagnostic Tool for the Surgical Pathologist*. Philadelphia: WB Saunders Co, 1986:334-362
- Eng L. Glial fibrillary acidic protein (GFAP): the major protein glial intermediate filaments in differentiated astrocytes. *J Neuroimmunol* 1985;8:203-214
- Brun A, Englund E. A white matter disorder in dementia of the Alzheimer type: a pathoanatomical study. *Ann Neurol* 1986;19:253-262
- Riwbvitan GF, Little E. Circulation in the cerebral hemispheres. *Br J Surg* 1965;52:8-21
- De Reuck J. The cortico-subcortical arterial angio-architecture in the human brain. *Acta Neurol Belg* 1972;72:323-329
- Roman GC. Senile dementia of the Binswanger type: a vascular form of dementia in the elderly. *JAMA* 1987;258:1782-1788
- Awad IA, Spetzler RF, Hodak JA, et al. Incidental subcortical lesions identified on magnetic resonance imaging in the elderly, I: correlation with age and cerebrovascular risk factors. *Stroke* 1986;17:1084-1089
- Lechner H, Schmidt R, Bertha G, et al. Nuclear magnetic resonance imaging white matter lesions and risk factors for stroke in normal individuals. *Stroke* 1988;19:263-265









HZ

500