



## Discover Generics

Cost-Effective CT & MRI Contrast Agents



WATCH VIDEO

# AJNR

### **Quiz. Herniated, migrated disk fragment with extension into the neural foramen.**

D J Quint, G P Colon and W F Chandler

*AJNR Am J Neuroradiol* 1995, 16 (1) 134


<http://www.ajnr.org/content/16/1/134.citation>

This information is current as  
of June 18, 2025.

---

# Q U I Z

Douglas J. Quint, Gary P. Colon, and William F. Chandler



A 52-year-old man presented with a 1.5-year history of progressive lower back pain and a 2-week history of acute right-leg weakness, which began several days after lifting a heavy pile of lumber in his back yard. Symptoms were unresponsive to conservative therapy. Past medical history was remarkable for previous resection of a left carotid space paraganglioma in 1980 and repeat surgery for local recurrence of this tumor in 1992.

A noncontrast lumbosacral spine computed tomographic (CT) scan was performed. Two images at the L3–4 intervertebral disk level from that study are presented (Figs 1A and B). Next, noncontrast sagittal and axial T1-weighted (Figs 2A and D), contrast-enhanced sagittal and axial T1-weighted (Figs 2B and E), and sagittal and axial T2-weighted (Figs 2C and F) magnetic resonance (MR) scans through the lumbosacral region were obtained.

*Diagnosis is on page 156.*

---

Received June 6, 1994; accepted after revision July 29.

From the Departments of Neuroradiology (D.J.Q.) and Surgery (G.P.C., W.F.C.), University of Michigan Hospitals, Ann Arbor.

Address reprint requests to Douglas J. Quint, Neuroradiology, B1D520B, Department of Radiology, Box 30, University of Michigan Hospitals, 1500 E Medical Center Dr, Ann Arbor, MI 48109-0030.

AJNR 16:134, Jan 1995 0195-6108/95/1601-0134 © American Society of Neuroradiology

## Solution to Quiz on page 134.

**Diagnosis:** *Herniated, Migrated Disk Fragment with Extension into the Neural Foramen*

Most patients with radiculopathy are treated conservatively for 6 to 8 weeks before any type of imaging is considered; however, because this patient had *motor* weakness at presentation, immediate imaging was indicated (1).

The lumbosacral CT scan demonstrates abnormal extradural soft tissue in the right posterolateral aspect of the spinal canal barely distinguishable from the ligamentum flava. This soft tissue displaces the thecal sac anterolaterally to the left. Minimal, if any, facet-degenerative changes are present. No mineralization of the lesion or any associated posterior element abnormalities are present.

The MR study demonstrates a peripherally enhancing mass, which is more extensive than suspected from the CT scan. It fills the right posterolateral portion of the spinal canal and extends from the midline into the right L3–4 neural foramen. It is centered superior to the level of the facet joint. It demonstrates low, essentially homogeneous signal on the T1-weighted study and central decreased with peripheral increased signal on the T2-weighted study. Homogeneous peripheral enhancement is seen on the gadopentetate dimeglumine-enhanced scans. No findings consistent with previous hemorrhage are seen.

Surgery was performed 3 weeks after the MR scan. At surgery, after removing the right L-3 lamina and underlying ligamentum flava, an approximately 4 × 2-cm smooth, grayish red epidural mass was seen, which was noted to compress and deform the underlying thecal sac. A small “punch” biopsy of this lesion was obtained, which grossly showed an outer layer of granulation tissue surrounding an inner layer of more fibrous, cartilagelike material, which appeared to be disk material (this was confirmed at histologic section). The mass extended into the right L3–4 neural foramen and compressed the right L-3 nerve root in this region. This foraminal portion of the disk was removed from deep within the neural foramen in several large fragments. The remainder of the spinal canal, including the L2–3 disk region, was smooth to palpation and was without evidence of additional disk bulges or loose disk fragments.

The differential diagnosis for posterior epidural space lesions is extensive (2), including degenerative processes (thickened ligamentum flava, osteophytosis, synovial cysts, and herniated/migrated disk material), neoplastic processes either arising in the epidural space or extending into the epidural space from nearby vertebra (metastatic disease, lymphoma, leukemia, sarcoma, chordoma, myeloma, and hemangioma), infectious processes (bacterial, tuberculous, or parasitic), posttraumatic lesions (fracture fragments, hematoma, foreign bodies, and postoperative scars), and other rare processes, such as epidural lipomatosis, extramedullary hematopoiesis, or extension of a paraspinal process into the spinal canal through a neural foramen.

Herniated disk material, once through the annulus and the posterior longitudinal ligament, can migrate anywhere in the epidural space (3). With time, reactive granulation tissue may form around such disk material. Although disk material is essentially avascular and does not enhance with MR or CT contrast agents, the associated granulation tissue (“scar”) does enhance (4, 5), as is nicely demonstrated in this case.

A synovial cyst was initially high on our differential diagnosis list; however, in view of: (a) the absence of significant facet degenerative changes, (b) the relatively large size of the lesion, (c) the apparent center of the lesion being cephalad to the facet joint, and (d) the relative rarity of such lesions at the L3–4 level (6–8), it was decided that this would be an unusual appearance for such a lesion.

A ligamentous or epidural abscess (9) was another diagnostic consideration. However, because the patient had not previously undergone an instrument procedure (eg, no recent lumbar puncture or history of back surgery), was not at risk for infection (eg, immunocompromised), and did not have any other signs or symptoms of infection (elevated sedimentation rate, fever, etc), an infectious process was considered unlikely.

A resolving hematoma can demonstrate peripheral contrast enhancement. Again, however, the patient did not have any risk factors for spontaneous hemorrhage, had not recently undergone an invasive procedure, and had no known recent trauma, and the intrinsic imaging characteristics of the lesion on the MR scans were not consistent with a resolving hematoma (10).

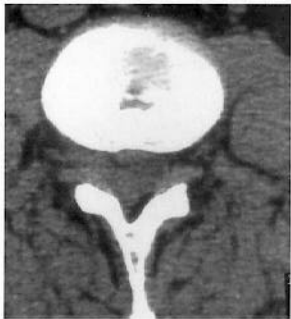A pathologic process (primary or secondary, benign or malignant) arising from the posterior elements of L-3 was considered unlikely, because these bony structures appeared normal on both the CT and MR scans.

A lesion arising in the epidural space without associated vertebral abnormality (eg, sarcoma, lymphoma, or metastatic disease [11]) was of concern in this patient, because a cystic or necrotic mass could have the imaging characteristics demonstrated here. However, processes such as lymphoma, leukemia (chloroma) (12), extramedullary hematopoiesis (13), and many metastatic lesions usually demonstrate more homogeneous contrast enhancement than was demonstrated by this lesion.

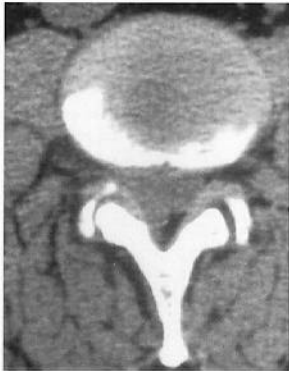Percutaneous biopsy of this lesion could have been performed. However, because the patient had acute radicular symptoms unresponsive to conservative treatment, decompressive surgery was necessary. Therefore, regardless of the results, a biopsy would not have obviated the need for an operation.

## References

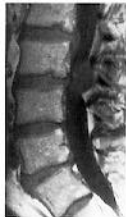1. Hardy RW, Davis CH. Extradural spinal cord and nerve root compression from benign lesions of the lumbar area. In: Youmans JR, ed. *Neurologic Surgery*. Philadelphia: Saunders, 1990:2664–2693
2. Reeder MM. *Reeder and Felson's Gamuts in Radiology*. 3rd ed. New York: Springer-Verlag, 1993:149
3. Williams AL, Houghton VM, Daniels DL, Grogan JD. Differential CT diagnosis of extruded nucleus pulposus. *Radiology* 1983;148:141–148
4. Sotiropoulos S, Chafetz NI, Lang P, et al. Differentiation between post-operative scar and recurrent disk herniation: comparison of MR, CT and contrast-enhanced CT. *AJNR Am J Neuroradiol* 1989;10:639–643
5. Bundschuh CV, Stein L, Slusser JH, Schinco FP, Ladaga LE, Dillon JD. Distinguishing between scar and recurrent herniated disk in post-operative patients: value of contrast-enhanced CT and MR imaging. *AJNR Am J Neuroradiol* 1990;11:949–958
6. Silbergleit R, Gebarski SS, Brunberg JA, et al. Lumbar synovial cysts: correlation of myelographic, CT, MR and pathologic findings. *AJNR Am J Neuroradiol* 1990;11:777–779
7. Patel SC, Sanders WP. Synovial cyst of the cervical spine: case report and review of the literature. *AJNR Am J Neuroradiol* 1988;9:602–603
8. Kiely M. Neuroradiology case of the day: case 1: lumbar synovial cyst. *AJR Am J Roentgenol* 1993;160:1336
9. Numaguchi Y, Rigamonti D, Rothman MI, Sato S, Mihara F, Sadatao N. Spinal epidural abscess: evaluation with gadolinium-enhanced MR imaging. *Radiographics* 1993;13:545–559
10. Mohazab HR, Langer B, Spigos D. Spinal epidural hematoma in a patient with lupus coagulopathy. *AJR Am J Roentgenol* 1993;160:853–854
11. Baker RA. Extradural tumors of the spine and spinal cord. In: Taveras JM, Ferrucci JT, eds. *Radiology*. Vol 3. Philadelphia: Lippincott, 1991:1–12
12. Frohna BJ, Quint DJ. Granulocytic sarcoma (chloroma) causing spinal cord compression. *Neuroradiology* 1993;35:509–511
13. Kalina P, Hillstrom MM. MR of extramedullary hematopoiesis causing cord compression in beta-thalassemia. *AJNR Am J Neuroradiol* 1992;13:1407–1409



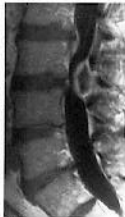1A



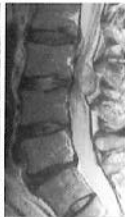1B



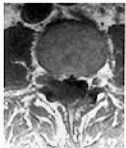2A



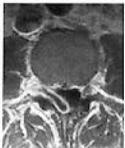2B



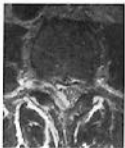2C



2D



2E



2F