



Discover Generics

Cost-Effective CT & MRI Contrast Agents



FRESENIUS
KABI

WATCH VIDEO

AJNR

Anatomy of the junction of the inferior petrosal sinus and the internal jugular vein.

D L Miller, J L Doppman and R Chang

AJNR Am J Neuroradiol 1993, 14 (5) 1075-1083

<http://www.ajnr.org/content/14/5/1075>

This information is current as
of June 5, 2025.

Anatomy of the Junction of the Inferior Petrosal Sinus and the Internal Jugular Vein

Donald L. Miller, John L. Doppman, and Richard Chang

PURPOSE: To evaluate the anatomy of the junction of the inferior petrosal sinus and the internal jugular vein. **METHODS:** Using a previously described classification system, we prospectively classified venous anatomy bilaterally in 135 of 136 persons consecutively undergoing inferior petrosal sinus sampling. **RESULTS:** Type IV anatomy, with no anastomosis between the inferior petrosal sinus and the internal jugular vein, was significantly less frequent in our series than in a previous series (1 versus 7%; $P < .001$). Venous anatomy did not differ significantly between the left and the right junctions or between men and women. Venous anatomy was symmetric in only 65% of subjects (86 of 133). We describe an uncommon variant anatomy, incomplete type IV, found in 4.5% of our subjects (six of 133), that may cause incorrect results of petrosal sinus sampling. **CONCLUSION:** Bilateral sampling of pituitary venous effluent can be accomplished by the methods described, despite the presence of either incomplete or true type IV venous anatomy. Bilateral petrosal sinus sampling is anatomically possible in 99% of persons.

Index terms: Skull, anatomy; Veins, anatomy; Veins, jugular; Foramina, jugular; Dural sinuses; Venography; Catheters and catheterization

AJNR 14:1075–1083, September/October 1993

Petrosal sinus sampling is a relatively new technique used for the differential diagnosis of Cushing syndrome (1, 2). Successful sampling requires catheterization of both inferior petrosal sinuses (IPSs). As with other angiographic procedures, successful catheterization requires detailed knowledge of the relevant anatomy.

In 1968, Shiu et al described the anatomy of the junction of the IPS and the internal jugular vein (IJV) on the basis of their experience with 57 patients (3). They classified the venous anatomy of this region into one of four types and reported the prevalence of each type. However, they analyzed their data by patients and reported only one classification for each patient even if the left and right IPS-IJV junctions were different.

In an earlier article (1), the estimated frequency of Shiu type 4 anatomy was based on a retrospective evaluation of seven catheterization failures in a series of 346 patients undergoing petrosal sinus sampling. The result ($<1\%$) was substantially different from the 7% reported by Shiu et al. The prevalence of the other anatomic types was not determined. We now report the results of a prospective study of the venous anatomy encountered in 135 consecutive subjects undergoing bilateral IPS sampling. None of these subjects has been included in any previous report.

Subjects and Methods

We prospectively evaluated the anatomy of the IPS-IJV region bilaterally in 135 of 136 consecutive subjects who underwent sampling at this institution from September 1990 through April 1992. (One subject, a healthy volunteer, had a vasovagal reaction when the first catheter was placed in the IPS. The study was immediately stopped; no images of the IPSs were obtained.) One hundred twelve of these subjects had Cushing syndrome; 24 were healthy volunteers. None of the subjects described in this report was included in previous publications. All subjects, both healthy volunteers and those with Cushing syndrome, were studied under one or more research protocols approved by our

Received August 19, 1992 and accepted November 11.

¹ Diagnostic Radiology Department, Warren Grant Magnuson Clinical Center, National Institutes of Health, Bethesda, MD 20892, and
² Georgetown University School of Medicine, Washington, DC 20037.

Address reprint requests to: Donald L. Miller, MD, Department of Radiology, SUNY Health Science Center, 750 East Adams St, Syracuse, NY 13210.

AJNR 14:1075–1083, Sept/Oct 1993 0195-6108/93/1405-1075

© American Society of Neuroradiology

institutional review board. All subjects gave written informed consent to the procedure.

With seven exceptions (two 11-year-olds, a 12-year-old, two 13-year-olds, and two 14-year-olds, all of whom had Cushing syndrome), all subjects were adults. There were 43 male and 92 female evaluable subjects.

Petrosal sinus sampling was performed as previously described (1). Briefly, 5 French catheters were introduced into the femoral veins bilaterally. The catheter tips were advanced into the IPSs bilaterally, and blood samples were obtained both before and after the intravenous administration of corticotropin-releasing hormone. Blood samples were also obtained simultaneously from the right femoral vein through a sheath. All blood samples were subsequently assayed to determine adrenocorticotrophic hormone (ACTH) concentrations.

As a routine part of the procedure, 5 to 8 mL of contrast material (iopamidol 300; Squibb, Princeton, NJ) was gently injected by hand through each catheter, one at a time, and digital subtraction retrograde petrosal venograms were obtained in the frontal plane to document the position of the catheter tips during sampling, in case of a question at some point in the future as to whether the catheters were properly positioned. These images were used in this study to evaluate the anatomy of each IPS-IJV junction.

At the conclusion of each procedure, the images that best depicted the relevant anatomy were evaluated and the results were recorded on a worksheet. The classification system was based on a previous study by Shiu et al (3) and is shown schematically in Figure 1. It has been modified to reflect better the difficulties encountered during the catheterization of the IPSs, with less of an emphasis on specifically named veins. A single IPS with a small or no anastomosis to the vertebral venous plexus (VVP) is classified as type I (Fig 2A). The diameter of the 5 French catheter shaft was used as a standard of reference to evaluate qualitatively the size of the anastomosis with the VVP. This anastomosis was considered small if it was equal to or smaller in size than the outer diameter of the 5 French catheter at the point where it entered the IPS. Type II anatomy was a single IPS with the anastomosis with the VVP larger in diameter than the 5 French catheter (Fig 2B). If the IPS consisted of a rete of separate channels, this was classified as type III, regardless of the presence or size of the anastomosis with the VVP (Fig 2C). Type IV anatomy is present when there is no connection between the IJV and the IPS (Fig 2D).

Each IPS was evaluated separately, because IPS anatomy is often not symmetrical. IPS anatomy is often better demonstrated on the contralateral retrograde venogram, so both right and left retrograde venograms were evaluated before classifying either IPS. All anatomic classification was performed by the same radiologist (D.L.M.). Statistical analysis was performed by the use of standard methods (χ^2 with Yates correction).

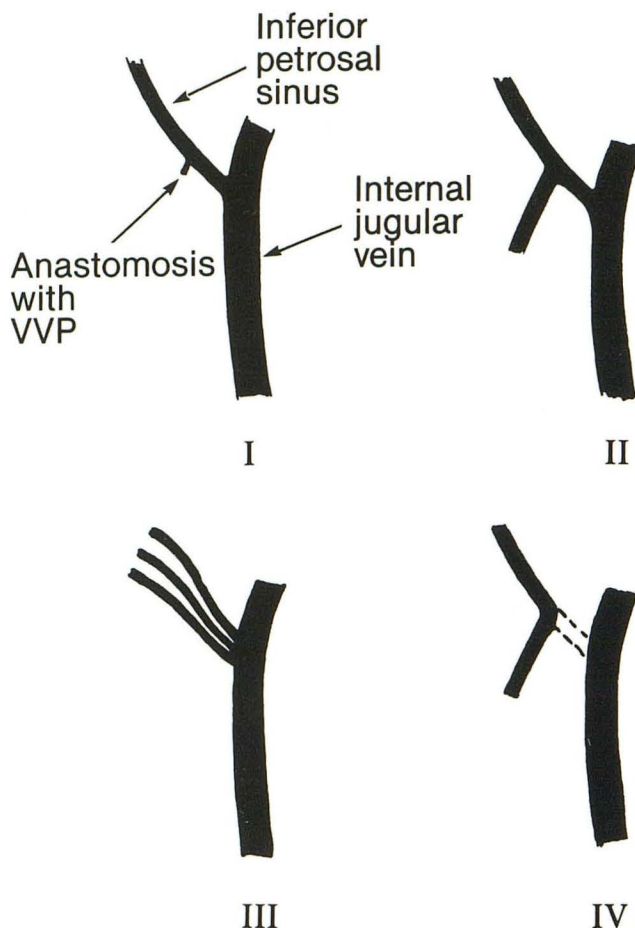


Fig. 1. Classification of IPS-IJV junction anatomy. The left side is shown as viewed from the front, corresponding to the appearance during petrosal sinus sampling. In type I anatomy, the anastomosis from the IPS to the VVP is small; in type II anatomy, it is large. In type III anatomy, the IPS is a network or group of small vessels, and the size of the vertebral plexus anastomosis is not important. In type IV anatomy, there is no connection between the IPS and the IJV.

Results

Both IPSs were successfully catheterized in 132 (99.2%) of 133 patients with patent IJVs bilaterally and type I, II, or III IPS-IJV anatomy. One subject, a healthy volunteer, had successful catheterization of the right IPS. The research protocol under which she and all other healthy volunteers were studied limits the duration of fluoroscopy over the head to 2 minutes. It was not possible to catheterize the left IPS within the time limit, and the study was terminated at that point. Images of the right IPS were obtained in this patient and are included in the data analysis. One subject had an occluded right IJV, presumed secondary to a central venous catheter placed via the IJV 6 years earlier at the time of coronary artery bypass grafting. The left IPS was catheterized in this patient, but retrograde venography was not ade-

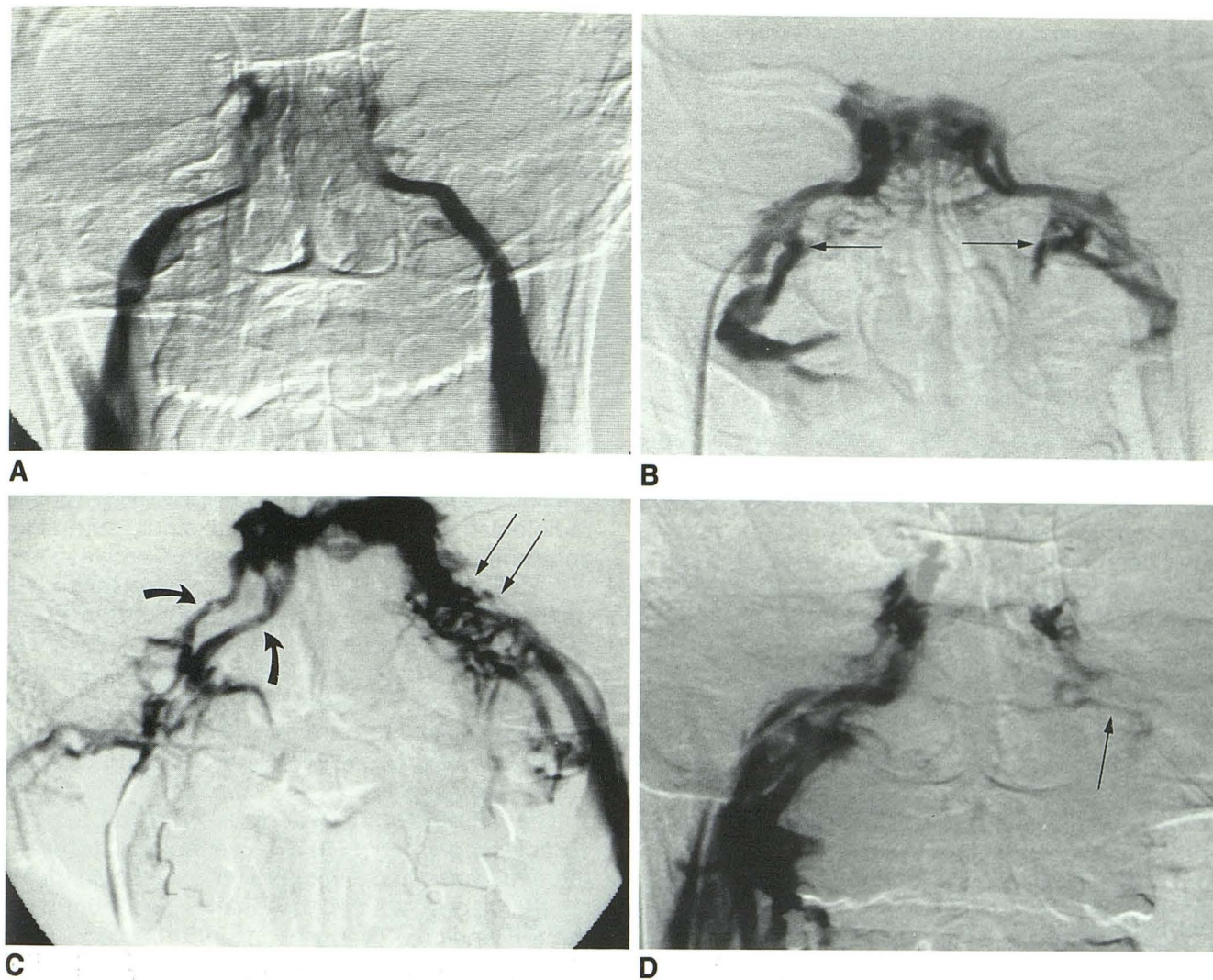


Fig. 2. A, type I IPS-IJV anatomy is present bilaterally on this petrosal sinus venogram. In this patient, no anastomosis with VVP is identified.

B, Bilateral type II anatomy is present in this patient, with large collateral veins (arrows) connecting the IPSs to the VVP, which is not opacified on this image.

C, This venogram demonstrates bilateral type III anatomy, with a network of vessels on the left instead of the usual IPS (arrows) and two discrete vessels on the right side (curved arrows).

D, True type IV anatomy is present on the left. The small venous channel identified on retrograde right petrosal venography (arrow) does not connect with the left IJV.

quate to permit evaluation of right-sided IPS-IJV anatomy. One subject had type IV anatomy.

The frequency with which each anatomic type was encountered is shown in Table 1 for all IPS-IJV junctions, for left and right IPS-IJV junctions, and for left and right IPS-IJV junctions in male and female subjects. There were no significant differences in the frequency of occurrence of the various anatomic types between left and right petrosal sinuses or between male and female subjects (χ^2 analysis). Type IV anatomy was seen in only one IPS-IJV junction in one subject (Fig 2D).

IPS-IJV anatomy was symmetrical in 86 (65%) of the 133 subjects in whom both IPS-IJV junctions could be evaluated: 11 subjects (8%) had type I anatomy bilaterally, 38 subjects (29%) had type II anatomy bilaterally, and 27 subjects (20%) had type III anatomy bilaterally. (In our experience with nearly 500 subjects, we have never encountered a person with bilateral type IV IPS-IJV anatomy.) The remaining 47 subjects (35%) had discordant IPS-IJV anatomy on the left and right sides.

We encountered a variant of type II and type III anatomy, which we term incomplete type IV

TABLE 1: Anatomy of the inferior petrosal sinus-internal jugular vein junction

Anatomic Type	All Subjects (n = 135) ^a			Male Subjects (n = 43)			Female Subjects (n = 92)		
	Right IPS-IJV	Left IPS-IJV	Both IPS-IJV	Right IPS-IJV	Left IPS-IJV	Both IPS-IJV	Right IPS-IJV	Left IPS-IJV	Both IPS-IJV
Type I ^b	33 (24.6) ^c	20 (14.9)	53 (9.8)	10 (24)	6 (14)	16 (19)	23 (25)	14 (15)	37 (20)
Type II	61 (45.5)	63 (47.0)	124 (46.3)	23 (55)	21 (49)	44 (52)	38 (41)	42 (46)	80 (44)
Type III	40 (29.9)	50 (37.3)	90 (33.6)	9 (21)	16 (37)	25 (29)	31 (34)	34 (37)	65 (36)
Type IV	0 (0)	1 (0.7)	1 (0.4)	0 (0)	0 (0)	0 (0)	0 (0)	1 (1)	1 (1)
Total	134	134	268	42	43	85	92	91	183

^a Includes one male subject in whom only the left IPS-IJV was evaluable and one female subject in whom only the right IPS-IJV was evaluable.

^b See text for a complete description of the classification system.

^c Number and (percent).

anatomy, in seven (2.6%) of 268 evaluable IPSs (six left, one right) in six subjects (Fig 3). This variant has been described in the anatomic literature on IPS and VVP anatomy (4, 5), but we have been unable to find a description of it in the radiologic literature. Incomplete type IV anatomy is characterized by an extremely small channel from the IJV to the point at which the IPS anastomoses with the VVP. There is a normal-caliber IPS from that point to its junction with the cavernous sinus. The small channel may be a very narrow IPS or a collateral vessel of some sort, and the IPS may otherwise exhibit either type II (five IPSs) or type III (two IPSs) anatomy. In patients with this anatomic variant, the majority of IPS blood flow is directed into the VVP, rather than the IJV (5). It is technically possible to catheterize the orifice of the IPS and obtain samples, despite the presence of this anatomic variant, and therefore, we do not classify it as type IV anatomy. When true type IV anatomy is present, with no connection between the IPS and the IJV, the IPS cannot be catheterized via the ipsilateral IJV.

The IPS courses medial-lateral, anterior-posterior, and rostral-caudal simultaneously. Because of the varying magnification factor on the frontal view that results from this anatomy, it is very difficult to measure IPS diameter accurately on digital subtraction studies. We made no attempt to quantify or tabulate these data. However, the diameter of the IPS varies considerably from subject to subject, although it tends to be very similar from one side to the other in any given individual (Figs 3D and 4).

Discussion

Anatomists have shown that the IPSs demonstrate marked anatomic variation, not only with regard to their size and anastomoses, but also

with regard to their relationship with the cranial nerves entering the jugular foramen and with the jugular foramen itself (1, 5, 6). However, for the radiologist attempting petrosal sinus sampling, anatomic variations in the junction between the IJV and the IPS are of primary importance. As Schild et al have noted, the anatomy of this region corresponds with classic descriptions in fewer than half of all patients (7, 8). The classification system used in this report was designed to reflect the variations that are of the greatest clinical importance to the radiologist attempting to catheterize these vessels.

The classification system is based on a more complex conception of the venous anatomy of the skull base than was used in previous studies (1, 3). In one article, the anastomosis between the IPS and the VVP was described as occurring via the anterior condylar vein. Different anatomic types were described, on the basis of the size of the anterior condylar vein. This is an oversimplification (4, 9, 10). The anterior condylar vein is an important anastomotic pathway (4, 10, 11), but other named and unnamed anastomotic channels may also connect the IPS to the VVP (10) and the IPS may also communicate with the epidural venous plexus (Fig 5) (12). There are numerous anastomotic channels between the IPS, the basilar venous plexus, the VVP, and the epidural venous plexus, and one or more of these may be dominant in any given patient (5).

In this report, anatomic variations are classified in the same fashion as in a previous study (1), but we have revised the terminology to reflect better the multiplicity of anastomotic channels between the IPS and the venous outflow pathways in the neck. Also, for the purpose of simplicity, the epidural venous plexus and the VVP are collectively referred to in this report as the VVP; for IPS catheterization, the distinction between the two plexi is not important.

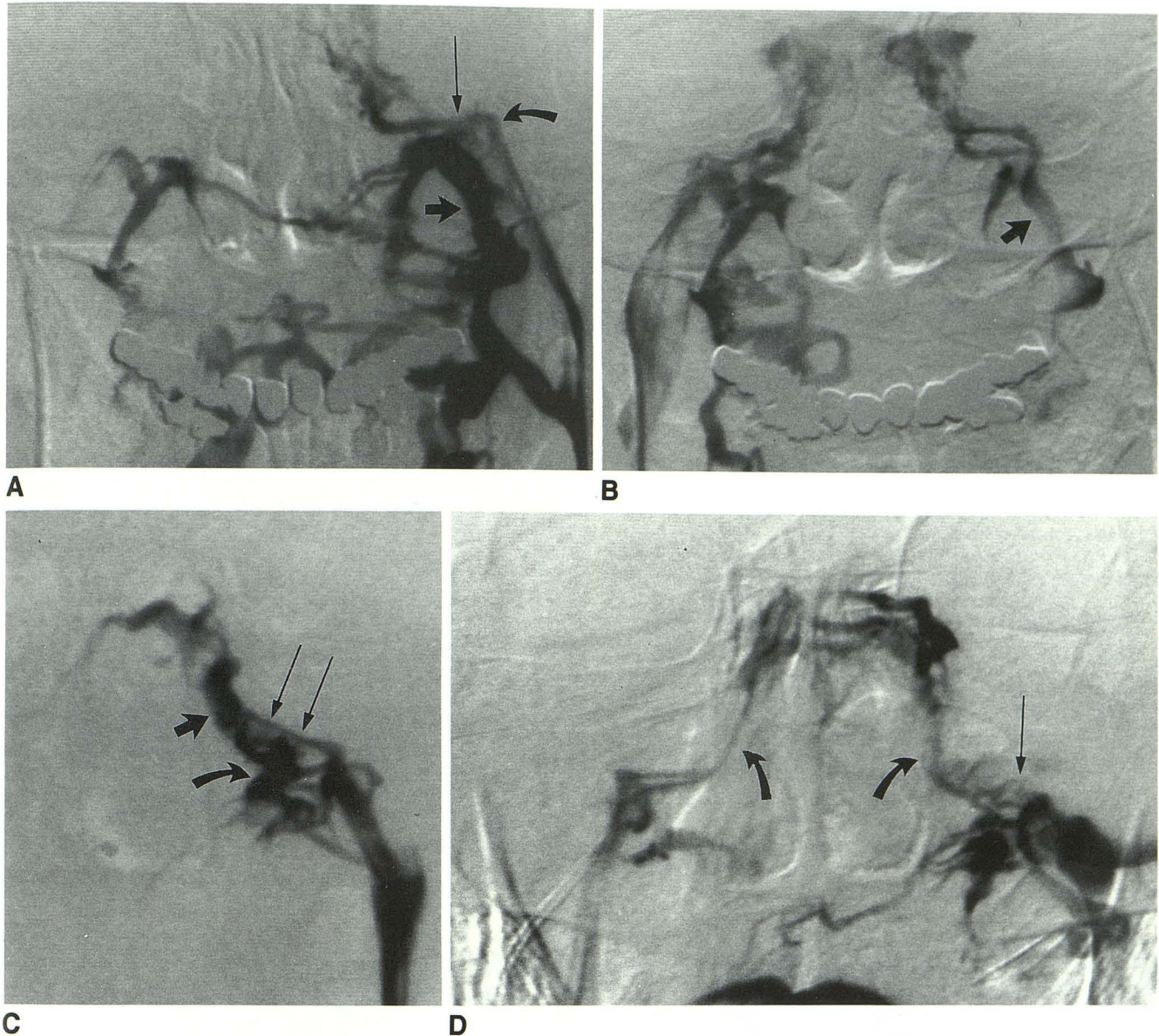


Fig. 3. Incomplete type IV anatomy in three subjects.

A, Left petrosal venogram demonstrates a small channel (*curved arrow*) extending from the IJV to the point at which the IPS anastomoses with the VVP (*long arrow*). Note the large size of the VVP (*short arrow*).

B, A right petrosal venogram in the same subject demonstrates left-sided type III anatomy and preferential drainage via the VVP (*arrow*), with no opacification of the IJV.

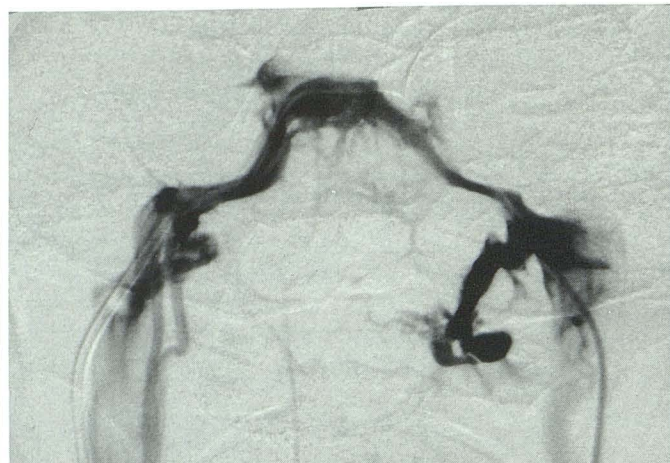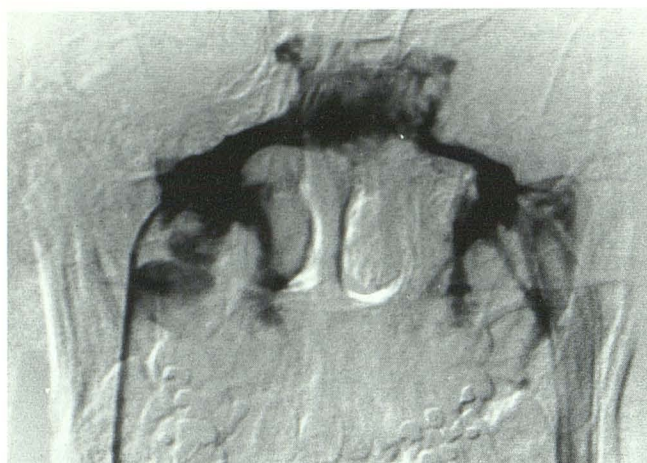C, Left-sided incomplete type IV anatomy in another subject. The segment of the IPS between the IJV and the anastomosis with the VVP (*long arrows*) is very narrow, as compared with both the medial portion of the IPS (*short arrow*) and the anastomosis between the IPS and the VVP (*curved arrow*).

D, The IPS anastomoses with the left IJV only via a small collateral vessel (*long arrow*), which has been selectively catheterized and injected on this left petrosal venogram. Note also the very small IPSs bilaterally (*curved arrows*).

Both neuroradiologists (3, 10) and anatomists (4, 5) have described examples of the IPS ending in the anterior condylar vein, which then communicates with the IJV, the VVP, or both. We have not considered this as a separate variant, because these variants can be classified as types I, II, or IV by our existing classification. Further, catheterization of the IPS is technically similar

regardless of whether the lateral portion is termed the IPS or the anterior condylar vein.

Shiu et al reported a 7% incidence of type IV anatomy (3). Bošković et al, in an anatomic study of 400 skulls, found this anatomy in 13 (3.25%) (5). In these specimens, and usually on the right side, the IPS terminated 5 to 8 mm proximal to the anterior margin of the jugular foramen. We

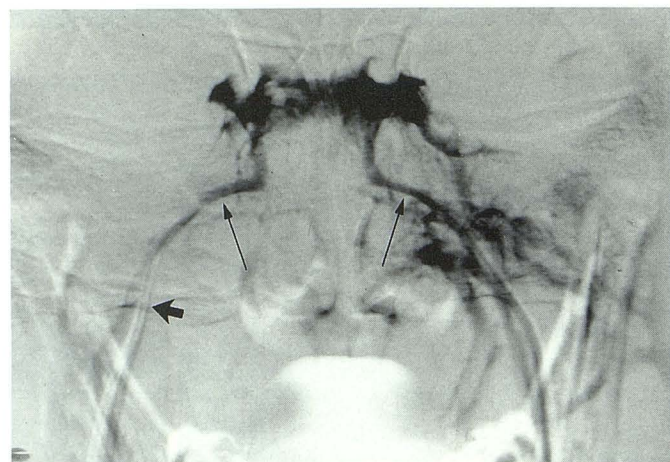


A Fig. 4. Variations in size of the IPSs in three subjects. (Compare with Figs 2 and 3.)

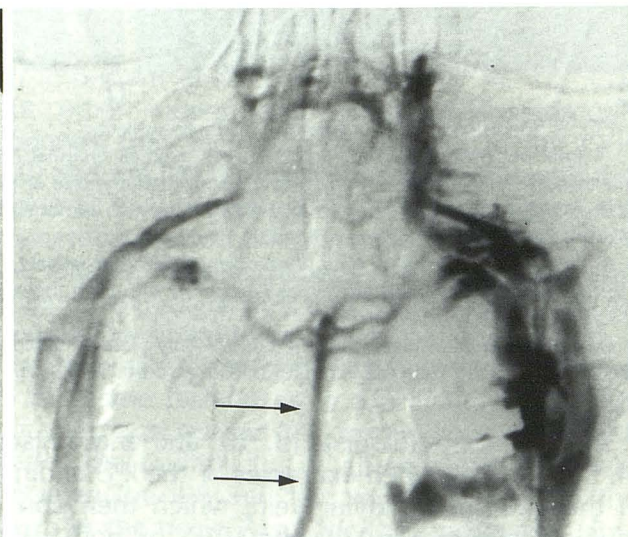
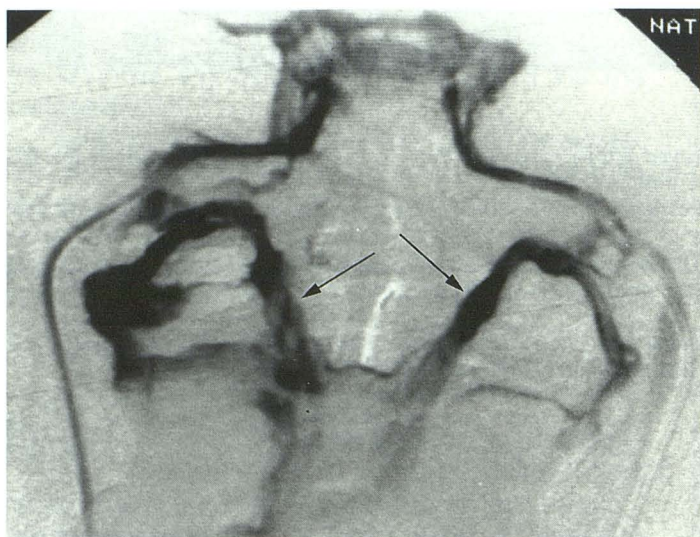
A and B, Two subjects with large, right-sided IPSs and relatively normal-diameter left IPSs.

C, Small IPSs bilaterally (*long arrows*), roughly comparable in diameter to the 5 French catheters (*short arrow*).

B



C



A

B

Fig. 5. Uncommon anastomoses between the IPS and portions of the VVP.

A, Right petrosal venogram demonstrates predominant drainage of the IPSs into the VVP bilaterally (*arrows*).

B, Left petrosal venogram in another subject demonstrates opacification of a spinal vein (*arrows*).

encountered this anatomic variant in only one of the 133 subjects in our series in whom both IPS-IJV junctions were evaluable (Fig 2D), and it was present in only 4 of the 346 patients described in a previous retrospective review (1), for an overall incidence of 1.0% (five of 479) in the combined group of patients. This is significantly different from the prevalence observed by Shiu et al ($\chi^2 = 11.675$; $P < .001$; χ^2 test with Yates correction). The difference may be because of the classification of incomplete type IV anatomy as either type II or III instead of type IV, because we reserve the type IV classification (as did Shiu et al) for those patients in whom vascular anatomy makes catheterization of the IPS impossible. The study of Shiu et al (3) was published more than 20 years ago; advances in catheter and guidewire design since then have made it possible to catheterize vessels that were technically unapproachable in the 1960s.

We found incomplete type IV anatomy in seven IPSs in six patients, with an overall prevalence of 4.5% (six of 133) in our series. The combined prevalence of incomplete and true type IV anatomy in our series is 5.5%, not significantly different from the 7% prevalence reported in the article by Shiu et al (χ^2 with Yates correction).

Incomplete type IV anatomy may cause venous drainage from the cavernous sinus to follow different pathways than those expected. In one patient with unilateral incomplete type IV anatomy, samples from the ipsilateral IPS yielded ACTH levels compatible with the ectopic ACTH syndrome. However, the majority of the venous drainage on the side of the incomplete type IV anatomy was into the external jugular vein (Fig. 6). When petrosal sinus sampling was repeated with sampling of the external jugular vein, the correct diagnosis of Cushing disease was made on the basis of elevated levels of ACTH in the external jugular vein. If sampling of the IPSs yields results compatible with ectopic ACTH production but all laboratory studies indicate Cushing disease in patients with this anatomic variant, then a second procedure with sampling of the other drainage pathway is advisable.

It must be remembered that petrosal sinus sampling is technically successful in virtually all patients with incomplete type IV anatomy, and even true type IV anatomy is not an insuperable obstacle when modern catheters and guidewires are used. In one patient studied before this series commenced, bilateral sampling was performed despite the presence of type IV anatomy. The patient had type IV anatomy on the left and type

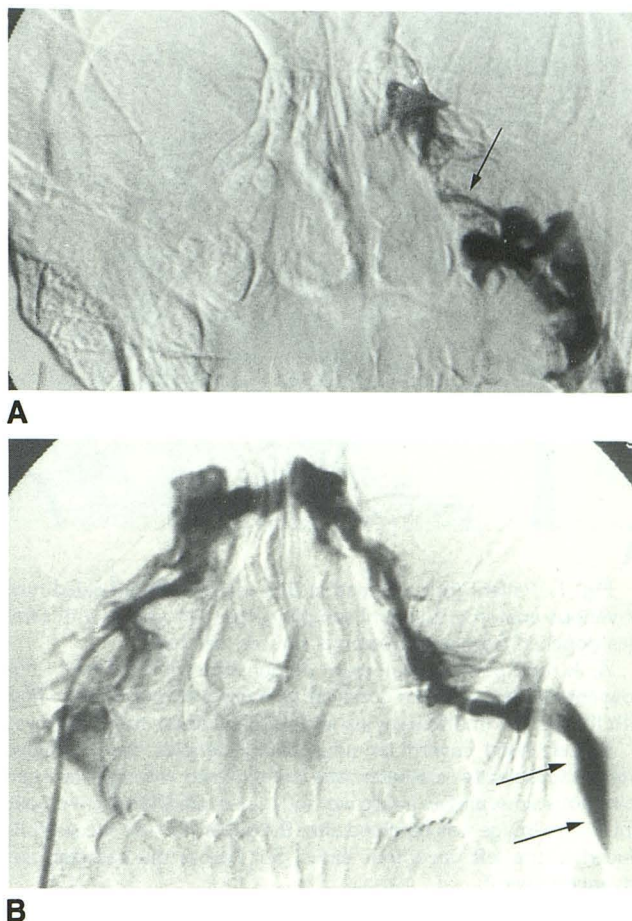


Fig. 6. Incomplete type IV anatomy with aberrant drainage into the external jugular vein.

A, Left petrosal venogram (with the catheter entering from the left IJV) demonstrates a very small IPS (arrow). The results of petrosal sinus sampling, performed with the catheter in this position, were consistent with an ectopic source of ACTH.

B, Right petrosal venogram in the same patient demonstrates that the majority of left cavernous sinus blood drains into the left external jugular vein (arrows). When petrosal sinus sampling was repeated with the left-sided catheter introduced via the left external jugular vein, the results were consistent with a left-sided pituitary source of ACTH.

II anatomy on the right (Fig 7). A coaxial super-selective catheter (Tracker-18; Target Therapeutics Inc, San Jose, CA) was introduced into the IPS on the right side and advanced into the ipsilateral cavernous sinus. Simultaneous right cavernous sinus and peripheral venous samples were obtained. The catheter was then gently manipulated through an intercavernous sinus and into the contralateral cavernous sinus. Similar samples were obtained. Corticotropin-releasing hormone was then administered, and 3-minute post-corticotropin-releasing hormone samples were obtained from the left cavernous sinus and a peripheral vein. The catheter was withdrawn

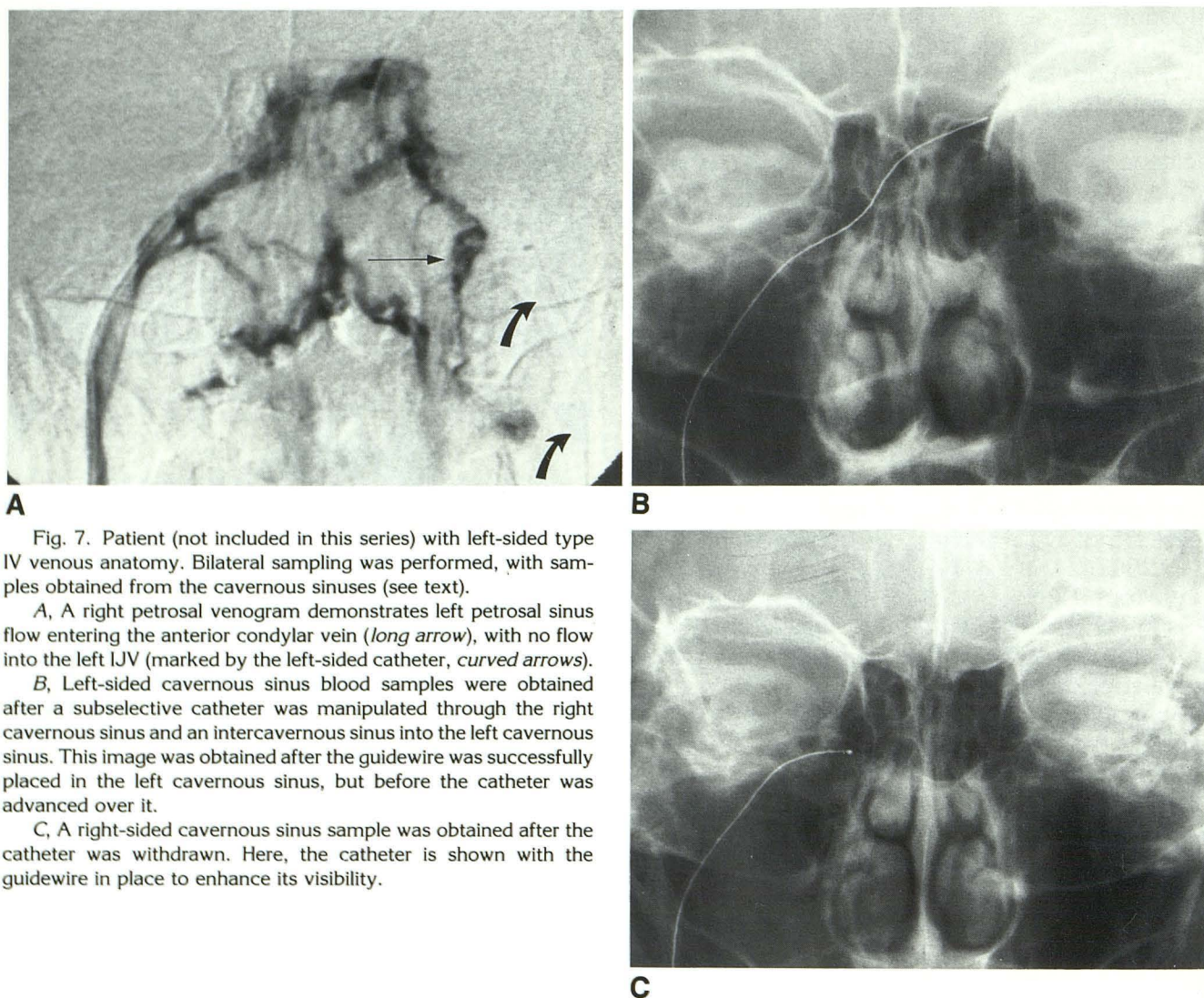


Fig. 7. Patient (not included in this series) with left-sided type IV venous anatomy. Bilateral sampling was performed, with samples obtained from the cavernous sinuses (see text).

A, A right petrosal venogram demonstrates left petrosal sinus flow entering the anterior condylar vein (long arrow), with no flow into the left IJV (marked by the left-sided catheter, curved arrows).

B, Left-sided cavernous sinus blood samples were obtained after a subselective catheter was manipulated through the right cavernous sinus and an intercavernous sinus into the left cavernous sinus. This image was obtained after the guidewire was successfully placed in the left cavernous sinus, but before the catheter was advanced over it.

C, A right-sided cavernous sinus sample was obtained after the catheter was withdrawn. Here, the catheter is shown with the guidewire in place to enhance its visibility.

into the ipsilateral cavernous sinus and 5-minute post-corticotropin-releasing hormone samples were obtained from the right cavernous sinus and a peripheral vein. This technique does not permit either simultaneous bilateral IPS sampling or collection of timed samples (because of the small size of the catheter lumen and the long time period required to aspirate a 10-mL blood sample), but it is the only method that permits bilateral sampling in these patients. However, the risk of injury to the IPS and cavernous sinus is increased because of the extensive catheter and guidewire manipulation. This procedure is recommended only if the required information is critical to the patient's management and can be gained in no other way. The study should be done by an experienced angiographer.

References

1. Miller DL, Doppman JL. Petrosal sinus sampling: technique and rationale. *Radiology* 1991;178:37-47
2. Oldfield EH, Doppman JL, Nieman LK, et al. Petrosal sinus sampling with and without corticotropin-releasing hormone for the differential diagnosis of Cushing's syndrome. *N Engl J Med* 1991;325:897-905
3. Shiu PC, Hanafee WN, Wilson GH, Rand RW. Cavernous sinus venography. *AJR: Am J Roentgenol* 1968;104:57-62
4. Stolic E, Mrvaljevic D. Les origines des veines vertébrales. *C R Assoc Anat* 1970;149:1027-1036
5. Bošković M, Savić V, Josifov J. Über die sinus petrosi und ihre Zuflüsse. *Gegenbaurs Morphol Verb* 1963;104:420-429
6. Rhoton AL Jr, Buza R. Microsurgical anatomy of the jugular foramen. *J Neurosurg* 1975;42:541-550
7. Schild H, Strack T, Günther R, et al. Selektive Blutentnahme aus dem Sinus petrosus inferior mit digitaler Subtraktionsangiographie. *Fortschr Röntgenstr* 1986;144:627-635

8. Schild HH, Strack TR. Selective simultaneous bilateral sampling from the inferior petrosal sinuses. In: Uflacker R, Sörensen R, eds. Percutaneous venous blood sampling in endocrine diseases. New York: Springer-Verlag, 1992:48-74.
9. Wackenheim A, Braun JP. The veins of the posterior fossa: normal and pathologic findings. Berlin: Springer-Verlag, 1978:69-71
10. Braun JP, Tournade A. Venous drainage in the craniocervical region. *Neuroradiology* 1977;13:155-158
11. Théron J, Moret J. Spinal phlebography: lumbar and cervical techniques. Berlin: Springer-Verlag, 1978:122-123
12. de Oliveira E, Rhoton AL Jr, Peace D. Microsurgical anatomy of the foramen magnum. *Surg Neurol* 1985;24:293-352