



Discover Generics

Cost-Effective CT & MRI Contrast Agents



WATCH VIDEO

AJNR

Can nonenhancing white matter lesions in cancer patients be disregarded?

A D Elster and M Y Chen

AJNR Am J Neuroradiol 1992, 13 (5) 1309-1315

<http://www.ajnr.org/content/13/5/1309>

This information is current as
of June 24, 2025.

Can Nonenhancing White Matter Lesions in Cancer Patients Be Disregarded?

Allen D. Elster and Michael Y. M. Chen

PURPOSE: To assess the risks and implications of assuming that white matter lesions in cancer patients that do not enhance with gadopentetate dimeglumine (Gd-DTPA) can be considered to be benign. **METHODS:** Gd-DTPA was administered prospectively to 131 consecutive patients with biopsy-proved extracranial malignancies referred for cranial MR imaging to exclude cerebral metastases over a 2½-year period. From this initial group, 50 patients were identified who had focal nonenhancing lesions of the white matter on T2-weighted images, but no other findings to suggest metastatic disease. This cohort of 50 patients was then followed for at least 1 year to determine the risk and clinical implications of assuming these nonenhancing white matter lesions were benign. **RESULTS:** Thirty patients (60%) were alive and clinically free of cranial metastatic disease at least 1 year following their initial MR study (median follow-up time, 17 months). Twenty of the 50 patients (40%) died within 1 year of their study (median survival, 4.1 months). Review of clinic notes and hospital charts revealed no evidence for deterioration of neurologic status in any of these patients before death, and the cause of death in each case was ascribed to extracranial complications of their systemic malignancies. Eight of these 20 patients who expired had at least one follow-up cranial CT or MR scan before death showing no new cerebral metastases or change in the nonenhancing white matter lesions previously identified. In a single patient, however, follow-up MR scan revealed conversion of one of her several white matter lesions from nonenhancing to enhancing without appreciable change in its size on T2-weighted images. Unfortunately, this patient died 4 months later from surgical complications without interval change in her neurologic status nor pathologic proof of the nature of this lesion. **CONCLUSIONS:** White matter lesions in cancer patients that do not enhance with Gd-DTPA at the time of the initial MR study have a low probability of representing metastatic disease. Clinical management or final outcome will not likely be altered by assuming such lesions are benign.

Index terms: Brain neoplasms, magnetic resonance; White matter, abnormalities and anomalies

AJNR 13:1309–1315, Sep/Oct 1992

Cerebral metastases occur in up to 30% of patients with systemic malignancy and may account for as many as 40% of all brain neoplasms in adults (1, 2). The detection of even a single brain metastasis in a patient with cancer may dramatically alter his prognosis and therapy (3). Accordingly, a large body of computed tomography (CT) (4–11) and magnetic resonance (MR)

(12–22) literature has arisen concerning the detection and characterization of cerebral metastases. More recently, the use of contrast agents such as gadopentetate dimeglumine (Gd-DTPA) has even further extended the role of MR imaging in the evaluation of such lesions (23–25).

The initial enthusiasm of early investigators for MR imaging in diagnosing metastatic disease has been tempered somewhat by the observation that the brains of many normal patients contain punctate foci of high signal on T2-weighted images that may resemble metastases. It is a generally accepted practice within the radiologic community to assume that lesions of the subcortical, deep, and periventricular white matter are not cerebral metastases if they do not enhance with contrast (15–17). Although this “conventional

Received October 30, 1991; accepted and minor revision requested February 6, 1992; revision received February 26.

Dr Elster was supported in part as a Winthrop Pharmaceuticals/RSNA Scholar.

Both authors: Department of Radiology, Bowman Gray School of Medicine, Wake Forest University, Medical Center Boulevard, Winston-Salem, NC 27157-1022. Address reprint requests to Dr. Elster.

AJNR 13:1309–1315, Sep/Oct 1992 0195-6108/92/1305-1309

© American Society of Neuroradiology

wisdom" may indeed be correct, such an imaging strategy is based totally upon anecdotal experience since this particular issue, to our knowledge, has not been the subject of either a prospective or retrospective scientific study. Furthermore, several cases have now been illustrated in the literature where cerebral metastases have been documented on T2-weighted images but either did not enhance or enhanced so weakly on T1-weighted images that they were undetectable (17, 22).

We therefore designed a study to look prospectively at that subgroup of cancer patients in whom nonenhancing white matter lesions were the only finding encountered on their initial MR examinations. By performing clinical and radiologic follow-up, we sought to determine the risk and implications of assuming such white matter lesions were benign.

Subjects and Methods

The subjects were chosen from a group of 131 consecutive adults with biopsy-proved extracranial malignancies referred for cranial MR imaging over a 2½-year period. Before imaging, the patients or their families completed a detailed medical questionnaire. MR technologists assisted the patients in filling out these forms, which included specific questions about presenting complaint, history of the present illness, past medical history, and prior surgical procedures. Specific questions relating to type of cancer, time since cancer diagnosis, knowledge of other known metastases, and current medications (including chemotherapeutic agents and steroids) were also included on the form. A radiology resident compiled these data from each patient's chart or by interview with the referring physician if the information was not directly attainable from the patient or family.

MR imaging was performed exclusively at high field strength (1.5 T). Precontrast T1-weighted, T2-weighted, and spin-density images were routinely obtained with use of spin-echo protocols. T1-weighted images in axial and sagittal planes were obtained with the following parameters: 600/20/2 (TR/TE/excitations); section thickness, 5 mm; intersection gap, 1.5 mm; field of view, 24 cm; matrix, 256 × 256. Spin-density and T2-weighted images were also obtained before the administration of contrast material, with use of a double-echo variable bandwidth protocol and gradient-moment nulling: 2500/20, 80/1; matrix, 192 × 256; and other parameters similar to those of the T1-weighted images.

After precontrast images were obtained, Gd-DTPA (Magnevist; Berlex Imaging, Cedar Knolls, NJ) was administered to each patient by intravenous infusion at a dose of 0.1 mmol/kg. Following a delay of approximately 5-10 minutes, axial and coronal postcontrast T1-weighted images were obtained in every case using the same param-

eters described for the precontrast portion of the study. In cases of suspected brain stem or posterior fossa pathology, sagittal 5-mm thick T1-weighted images (600/30/2) with gradient-moment nulling were also obtained. This protocol resulted in the last postcontrast imaging sequence being performed at delays ranging between approximately 20-30 minutes following injection of Gd-DTPA.

Immediately following completion of imaging, the MR examination was interpreted by one of four experienced neuroradiologists, all Senior Members of the American Society of Neuroradiology. MR diagnoses were classified into four groups: normal scans (n = 10); scans with unequivocally benign lesions (such as old strokes, arachnoid cysts, etc) that harbored no suspicion for metastatic disease (n = 29); scans with at least one enhancing lesion compatible with a metastasis (n = 42); and scans with one or more discrete white matter lesions, none of which enhanced (n = 50). Patient acquisition for the study was terminated once 50 patients were identified who filled this final category. The range of patient ages, distribution between the sexes, and sites of primary malignancy were similar among the four clinical groups.

The final patient cohort thus comprised a diverse group of 50 adults ranging in age from 23 to 85 years (median, 66.5 years). There were 23 men and 27 women. The main sites of extracranial cancer origin were primarily the lung (32%) and breast (28%), although a wide variety of other neoplasms were also encountered (Table 1). The median time interval from cancer diagnosis to the MR study was 12 months.

At least 1 year after their initial MR studies, clinical follow-up was obtained in all patients. As needed, this follow-up included: clinic chart review, review of subsequent cranial CT or MR scans, review of death certificates, and/or telephone interviews with the patient or his family. Radiologic follow-up by high-dose contrast-enhanced CT or MR was performed in 14 and eight patients, respectively. Actuarial estimates based on "worst-case" scenarios were then made to establish the risk of assuming nonenhancing white matter lesions encountered on initial cranial MR studies in cancer patients are benign.

Results

The main clinical symptoms listed by the patients at the time of their initial MR referral in-

TABLE 1: Extracranial primary neoplasm by site

Site of Primary Neoplasm	No. of Patients
Lung	16
Breast	14
Gastrointestinal tract	5
Urinary tract	4
Reproductive system	4
Lymphoma	4
Head and neck	2
Unknown primary	1

cluded: weakness (12 patients), syncope/dizziness (11 patients), headaches (10 patients), seizures (five patients), neurologic deficits (three patients), and mental status changes (three patients). Six patients were neurologically asymptomatic and the reason for the referral apparently based upon the highly aggressive nature of their primary malignancies with propensity for cerebral metastases. At the time of the MR study, 13 patients (26%) had documented extracranial metastatic disease (not including local recurrence or local extension of their primary neoplasms). Three patients were on steroids at the time of imaging, and three had received prior prophylactic cranial irradiation. Seventeen (34%) were on various forms of chemotherapy at the time of the MR study. Twenty-eight patients (56%) related a history of cardiovascular risk factors (eg, hypertension, diabetes, heart disease) which may be associated with a higher incidence of white matter lesions on a microangiopathic basis.

Thirty of the 50 patients (60%) from the original cohort were alive and without significant neurologic symptoms at least 1 year following their initial MR exam. Two of these patients subsequently died of cardiovascular causes at 13 and 15 months into the study, respectively. The other 28 remain alive and clinically free of cerebral metastatic disease, at intervals ranging from 12–30 months (median, 17 months). Thirteen of these patients also had follow-up CT or MR scans during this period, showing no new abnormalities or change in their previously noted white matter lesions.

Twenty of the 50 patients (40%) died within 1 year of their initial MR study (median survival, 4.1 months). Review of the clinic notes and hospital charts revealed no evidence for deterioration of neurologic status between the time of initial MR scan and death in any of these patients. Furthermore, the cause of death in each case as documented on the hospital chart and death certificate by the treating physician was nonneurologic (respiratory failure, sepsis, pulmonary embolism, etc). Nine of the 20 patients who expired had at least one follow-up CT or MR scan at intervals between 1 and 10 months after their initial MR study. In eight of these cases, there was no evidence for new cerebral metastases or change in the white matter lesions previously identified (Fig. 1).

In a single patient, however, a follow-up MR scan revealed conversion of one of her several white matter lesions from nonenhancing to en-

hancing without appreciable change in its size on T2-weighted images (Fig. 2). This lesion could not be seen on a high-dose delayed contrast-enhanced CT performed at the same time as the second MR study. Unfortunately, this patient died 2½ months later of complications related to thoracic surgery, and no autopsy was performed. Thus, we do not know whether this lesion represented a tiny metastasis, a focal subacute white matter infarction, or some other benign inflammatory or vascular process.

Discussion

The prevalence of cerebral metastatic disease in patients with documented extracranial malignancy varies from 3%–35%, depending on the series chosen (1, 26–30). This wide divergence of quoted figures likely relates to various institutional, diagnostic, and geographic biases that exist among the published reports. Russell and Rubinstein (1) have stated that a reasonable general estimate is that about 5% of all patients with cancer will have cerebral metastases.

In patients with advanced disease who die from their cancers, however, the prevalence of cerebral metastasis is probably much higher than 5%. Perhaps a figure of 25%, close to that calculated by Posner and Chernik (28) from their large autopsy series of 2375 patients dying from systemic malignancy from 1970 to 1976, would be a more accurate estimation in this population. Even higher prevalences (up to 35%) are obtained from surgical studies and in autopsy series originating from terminal care hospitals (1, 26). The detection rate (32%) of presumed cerebral metastases in our series is consistent with our demographics as a teaching hospital, regional oncology center, and tertiary referral site.

Of significance to the present study is the well documented phenomenon of “silent” cerebral metastases. Absence of focal neurologic findings has been reported in 5%–12% of patients with lung carcinoma metastases to the brain identified on CT (4, 7). A similar percentage of silent cerebral metastases has also been reported in clinical autopsy studies of patients dying from breast cancer (29). Thus, it is conceivable that some of our patients with nonenhancing white matter lesions who were asymptomatic or minimally symptomatic did indeed have metastases at presentation. Furthermore, we readily concede the possibility that some of our patients may have

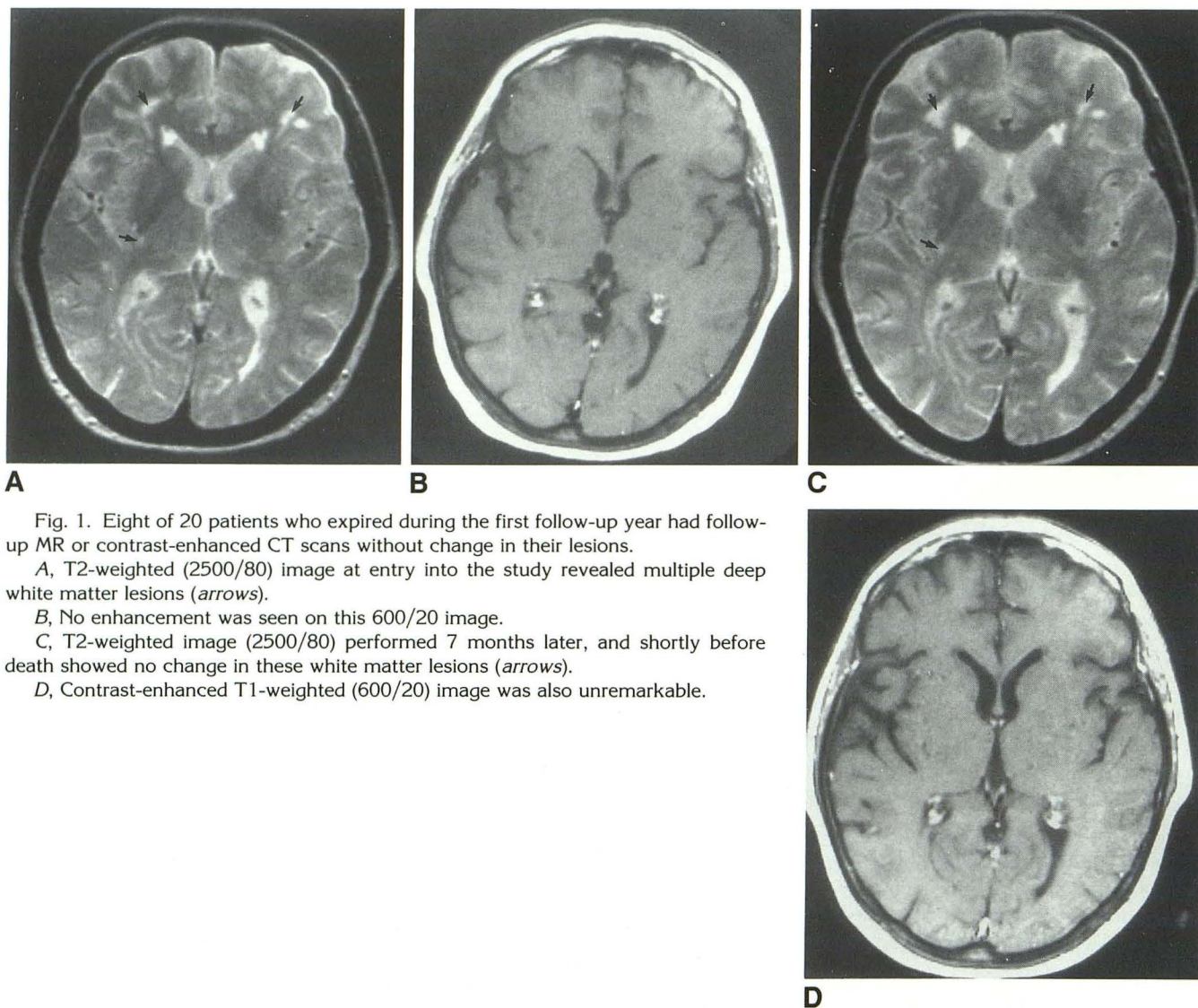


Fig. 1. Eight of 20 patients who expired during the first follow-up year had follow-up MR or contrast-enhanced CT scans without change in their lesions.

A, T2-weighted (2500/80) image at entry into the study revealed multiple deep white matter lesions (*arrows*).

B, No enhancement was seen on this 600/20 image.

C, T2-weighted image (2500/80) performed 7 months later, and shortly before death showed no change in these white matter lesions (*arrows*).

D, Contrast-enhanced T1-weighted (600/20) image was also unremarkable.

subsequently developed cerebral metastases that remained clinically silent at follow-up.

Understanding these potential sources of error, we arbitrarily selected a period of 1 year to represent a reasonable target goal for clinical follow-up. We felt that patients whose neurologic status had not changed for the worse during this long interval most likely had not had cerebral metastases at the time of their initial MR study. As the length of follow-up was extended (to 17 months, median), we felt the probability that these original lesions represented metastases approached zero. We again fully concede that in the rare case, however, a stable or extremely slowly growing metastasis could remain clinically silent even over this long period of time.

Both for the benefit of our subjects and this study, we would certainly have preferred to have encountered fewer deaths in our patient cohort during the first follow-up year. The early loss of these patients without autopsy verification of their brain lesions does impact adversely upon the certainty and ultimate strength of our conclusions. Unfortunately, factors such as early patient death cannot be controlled for in an unbiased manner, or the prospective nature of the entire study would be lost. For example, our survival statistics could have been dramatically improved if we had chosen to enroll only patients with minimal or early cancer into our study. However, the preselection of these patients would have introduced a significant pretest bias into our re-

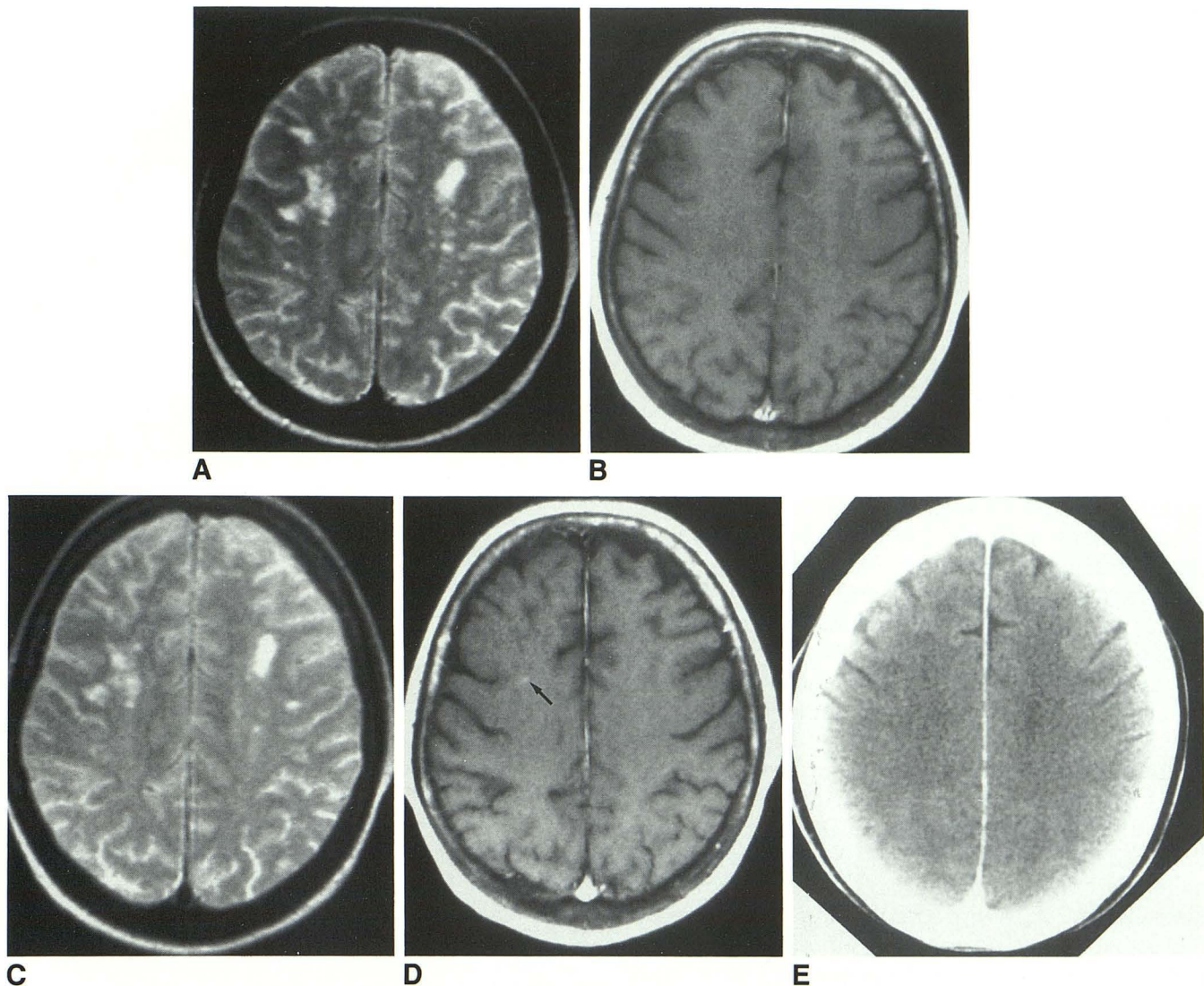


Fig. 2. Conversion from nonenhancement to enhancement occurred in a single lesion in a single patient, this 61-year-old woman with locally recurrent breast cancer.

A, T2-weighted (2500/80) image at time of entry into the study showed multiple tiny nonspecific high-signal lesions in the deep white matter.

B, None of these lesions enhanced on the initial postcontrast T1-weighted (600/20) study.

C, Follow-up examination 2½ months later revealed no change on the T2-weighted images.

D, A single lesion (arrow) was now seen to enhance weakly.

E, High-dose delayed contrast-enhanced CT performed within 1 day of the second MR did not show this enhancing lesion, whose true nature was never established pathologically.

sults; the a priori prevalence of brain metastases in patients with stage I or $T_1N_0M_0$ cancers is naturally very low.

If anything, our study population was slanted somewhat in the opposite direction, toward sick and predominantly hospitalized patients with advanced cancers. Thirteen of our 50 patients (26%) had extracranial metastases at the time of entry into the study, and five more developed extracranial metastases during the follow-up

period. The pretest probability of cerebral metastases in our patient population was thus relatively high. The fact that many of our patients had advanced cancer at the time of entry into our study explains the high first year mortality we encountered.

Although 20 of our 50 patients (40%) died between 1 and 11 months into the study (median, 4.1 months), we take consolation in the fact that there was no clinical evidence for deterioration of

neurologic status in any of these patients before their deaths. Furthermore, eight of the 20 deceased patients had negative follow-up CT or MR studies prior to their demise. Again, we fully concede that some small fraction of these patients could have had clinically silent metastases. However, since these lesions all remained clinically silent even up to the time of death, and the cause of death in each case was ascribed to nonneurologic factors, it is doubtful whether an incorrect MR diagnosis of benign white matter disease would have altered these patients' clinical management or outcome.

Although an accurate statistical analysis of our data is impossible owing to the uncertainties in final diagnosis, we, nevertheless, can construct several "worst-case" scenarios to estimate the potential diagnostic error rates in having assumed these nonenhancing lesions were benign. We begin by making the reasonable assumption that all 30 patients who were alive and well at 1 year or longer had not had cerebral metastasis at the time of entry into the study. Furthermore, we will assume that the single patient whose lesion converted from nonenhancing to enhancing did indeed have a metastasis, and that some fraction of the remaining 19 patients who died during the first follow-up year also had metastases.

In the first scenario, let us assume that this unknown fraction of the 19 patients who may have died with clinically occult cerebral metastases is equal to the percentage of presumed metastases showing contrast enhancement in our entire population (32%). As previously noted, this figure is a reasonable upper limit since it is close to the percentages of central nervous system metastases detected in autopsy series of similar patients (1, 26, 28). Based on these assumptions, the expected total number of patients having cerebral metastases that were nonenhancing on the initial MR study would have been no greater than $1 + (0.32)(19) = 7.1$. This particular scenario thus predicts that the expected maximum error in having diagnosed a nonenhancing white matter lesion to be benign would be 7.1/50, or approximately 14%.

Under a second scenario, let us assume the fraction of the 19 patients who may have died with clinically occult metastases is equal to the highest literature rate (12%) quoted for silent metastases (7). In this situation, the expected maximum number of patients with metastases that were nonenhancing and asymptomatic

would be $1 + (0.12)(19) = 3.3$. The expected maximum error in diagnosing a nonenhancing metastasis to be benign under this scenario would be 3.3/50, or only 6.6%.

In the recent imaging literature, several studies have specifically analyzed the role of contrast-enhanced MR for the detection of cerebral metastases (14–22). There is general agreement from these independent investigations that contrast enhancement with Gd-DTPA increases both the detection rate and diagnostic accuracy for metastases compared to conventional noncontrast T2-weighted imaging. However, the optimal dose of paramagnetic contrast necessary to accomplish this task remains open to debate, since recent clinical trials with the agent Gd-HP-DO3A have produced cases where more cerebral metastases have detected with high dose (0.3 mmol/kg) than conventional dose (0.1 mmol/kg) contrast (31).

It is our perception of the practice of neuroradiology in the United States that when a white matter lesion is encountered in a cancer patient, that lesion is generally not considered to represent a metastasis if it does not enhance with gadolinium. Although such "conventional wisdom" may indeed be correct, this strategy is supported only by anecdotal experience. In fact, careful analysis of the existing literature will provide several vivid counterexamples to this hypothesis. Both Sze et al (11) and Davis et al (22) have illustrated cases where the T2-weighted images demonstrated metastases that were not apparent on the postcontrast T1-weighted sequence.

The goal of the present study was to estimate the risk and assess the implications of assuming nonenhancing white matter lesions in cancer patients are benign. Based on this analysis, we conclude that such lesions have a low (but not necessarily zero) probability of representing metastatic disease. Much larger clinical-pathologic studies in the future will be needed to determine the exact actuarial risk such lesions possess. Until such definitive data is available, however, we do provide support to the general practice that clinical management or final outcome will not likely be altered by assuming that most nonenhancing white-matter lesions in cancer patients are benign. Follow-up imaging studies may be safely limited to that small group of patients whose neurologic status deteriorates, who develop new symptoms, or who are thought to be at very high

risk for cerebral metastases based upon the aggressive nature of their primary neoplasms.

Acknowledgment

The authors wish to express sincere appreciation to Beth Hales for her assistance in the preparation of this manuscript.

References

- Russell DJ, Rubinstein LJ. *Pathology of tumors of the nervous system*. 5th ed. Baltimore: Williams & Wilkins, 1989:825-841
- Patchell RA, Tibbs PA, Walsh JW, et al. A randomized trial of surgery in the treatment of single metastases to the brain. *N Engl J Med* 1990;322:494-500
- Posner JB. Surgery for metastases to the brain. *N Engl J Med* 1990;322:544-545
- Butler AR, Leo JS, Lin JP, Boyd AD, Kricheff II. The value of routine cranial computed tomography in neurologically intact patients with primary carcinoma of the lung. *Radiology* 1979;131:399-401
- Deck MDF, Messina AV, Sackett JF. Computed tomography in metastatic disease of the brain. *Radiology* 1976;119:115-120
- Lee YY, Glass JP, Geoffroy A, Wallace S. Cranial computed tomographic abnormalities in leptomeningeal metastasis. *AJNR* 1984;5:559-563
- Jacobs L, Kinkel WR, Vincent RG. Silent brain metastasis from lung carcinoma determined by computed tomography. *Arch Neurol* 1977;34:690-693
- Potts DG, Abbott GF, Vonsneiden JV. National Cancer Institute Study: Evaluation of computed tomography in the diagnosis of intracranial neoplasms: III. Metastatic tumors. *Radiology* 1980;136:657-664
- Shalen PR, Hayman LA, Wallace S, Handel SF. Protocol for delayed contrast enhancement in computed tomography of cerebral neoplasia. *Radiology* 1981;139:397-401
- Hayman LA, Evans RA, Hinck VC. Delayed high iodine dose contrast computed tomography. *Radiology* 1980;136:677-684
- Davis JM, Davis KR, Newhouse J, Pfister RC. Expanded high iodine dose in computed cranial tomography: a preliminary report. *Radiology* 1979;131:373-380
- Claussen C, Laniado M, Schorner W, et al. Gadolinium-DTPA in MR imaging of glioblastomas and intracranial metastases. *AJNR* 1985;6:669-674
- Schorner W, Laniado M, Niendorf HP, Schubert C, Felix R. Time-dependent changes in image contrast in brain tumors after gadolinium-DTPA. *AJNR* 1986;7:1013-1020
- Healey ME, Hesselink JR, Press GA, Middleton MS. Increased detection of intracranial metastases with intravenous Gd-DTPA. *Radiology* 1987;165:619-624
- Russell EJ, Geremia GK, Johnson CE, et al. Multiple cerebral metastases: detectability with Gd-DTPA-enhanced MR imaging. *Radiology* 1987;165:609-617
- Sze G, Shin J, Drol G, Johnson C, Liu D, Deck MDF. Intracranial brain metastases: MR imaging versus contrast-enhanced CT. *Radiology* 1988;168:187-194
- Sze G, Milano E, Johnson C, Heier L. Detection of brain metastases: comparison of contrast-enhanced MR with unenhanced MR and enhanced CT. *AJNR* 1990;11:785-791
- Woodruff WW, Djang WT, McLendon RE, Heinz ER, Voorhees DR. Intracerebral malignant melanoma: high-field-strength MR imaging. *Radiology* 1987;165:209-213
- Atlas SW, Grossman RI, Gomori JM, et al. Imaging of intracranial metastatic melanoma. *J Comput Assist Tomogr* 1987;11:577-582
- Davis PC, Friedman NC, Fry SM, Malko JA, Hoffman JC, Braun IF. Leptomeningeal metastasis: MR imaging. *Radiology* 1987;163:449-454
- West MS, Russell EJ, Breit R, Sze G, Kim KS. Calvarial and skull base metastases: comparison of nonenhanced and Gd-DTPA-enhanced MR images. *Radiology* 1990;174:85-91
- Davis PC, Hudgins PA, Peterman SB, Hoffman JC Jr. Diagnosis of cerebral metastases: double-dose delayed CT vs contrast-enhanced MR imaging. *AJNR* 1991;12:293-300
- Elster AD, Moody DM, Ball MR, Laster DW. Is Gd-DTPA required for routine cranial MR imaging? *Radiology* 1989;173:231-238
- Russell EJ, Schaible TF, Dillon W, et al. Multicenter double-blind placebo-controlled study of gadopentetate dimeglumine as an MR contrast agent: evaluation in patients with cerebral lesions. *AJNR* 1989;10:53-63
- Runge VM, Schaible TF, Goldstein HA, et al. Gd-DTPA: clinical efficacy. *Radiographics* 1988;8:147-179
- Henson RA, Urich H. *Cancer and the nervous system: the neurological manifestations or systemic malignant disease*. Oxford, England: Blackwell Scientific, 1982:7-15
- Percy AK, Elveback LR, Okazaki H, Kurland LT. Neoplasms of the central nervous system: epidemiologic considerations. *Neurology* 1972;22:40-49
- Posner JB, Chernic NK. Intracranial metastases from systemic cancer. *Adv Neurol* 1978;19:579-567
- Tsukada Y, Fouad A, Pickren JW, Lane WW. Central nervous system metastasis from breast carcinoma: autopsy study. *Cancer* 1983;52:2349-2353
- Russcalle J. Clinical symptomatology and computerized tomography in brain metastases. *Comput Tomogr* 1978;2:69-77
- Runge VM. Clinical applications of magnetic resonance contrast media in the head. *Top Magn Reson Imaging* 1991;3:19-40

Please see the Commentary by Heier and Zimmerman on page 1316 in this issue.