

Generic Contrast Agents

Our portfolio is growing to serve you better. Now you have a *choice*.



FRESENIUS
KABI

[VIEW CATALOG](#)

AJNR

CT and ultrasound imaging of retropharyngeal abscesses in children.

C M Glasier, J E Stark, R F Jacobs, P Mancias, R E Leithiser, Jr, R W Seibert and J J Seibert

AJNR Am J Neuroradiol 1992, 13 (4) 1191-1195

<http://www.ajnr.org/content/13/4/1191>

This information is current as
of May 31, 2025.

CT and Ultrasound Imaging of Retropharyngeal Abscesses in Children

Charles M. Glasier,¹⁻³ James E. Stark,^{1,3} Richard F. Jacobs,² Pedro Mancias,² Richard E. Leithiser, Jr.,¹⁻³ Robert W. Seibert,² and Joanna J. Seibert¹⁻³

Purpose: To show the role of ultrasound (US) in distinguishing retropharyngeal abscess from adenitis in children. **Methods:** Eleven infants and children had clinical symptoms suggestive of retropharyngeal infection. Radiographic evaluation included, lateral neck radiography (11/11), contrast-enhanced neck CT (10/11), contrast-enhanced neck MR (1/11), and real time US (11/11) patients. US was used to characterize masses as solid (adenitis) or complex (abscess) and for guiding intraoperative aspiration and drainage. **Results:** Contrast CT and MR showed findings suspicious for abscess in all 11 cases. Only three children had surgically drainable abscesses. CT numbers within inflammatory masses did not distinguish adenitis from abscess. US was able to correctly diagnose abscess or adenitis in each case. **Conclusion:** Lateral neck radiography and contrast CT identify and localize retropharyngeal inflammatory masses in children. US, but not CT, distinguishes between adenitis and abscess and aids in intraoperative aspiration and drainage.

Index terms: Neck, abscesses; Neck, computed tomography; Neck, ultrasound; Pediatric neuro-radiology

AJNR 13:1191-1195 Jul/Aug 1992

Retropharyngeal abscess is a serious complications of pharyngeal infection usually seen in children under 6 years of age. Prompt diagnosis and surgical drainage are important to prevent airway obstruction, rupture with aspiration, or dissection into the mediastinum, great vessels, or spine. Prior to the advent of computed tomography (CT) and ultrasound (US), radiographic diagnosis of retropharyngeal infection was limited to conventional radiography of the soft tissues of the neck. Although conventional radiography is still an excellent screening examination for retropharyngeal infection, more accurate localization and characterization of inflammatory masses

is necessary prior to surgical therapy. In particular, identification of purulence within an inflammatory mass is useful to the surgeon to avoid surgery on patients with cellulitis or phlegmon without abscess. The purpose of this study is to show the role of real time US in conjunction with contrast CT in accurately localizing and characterizing retropharyngeal inflammatory masses in children.

Patients and Methods

Eleven children with retropharyngeal inflammation were seen at our hospital in 1990 and 1991. Ages ranged from 1 to 11 years. There were seven boys and four girls. Clinical and imaging data are summarized in Table 1. Each patient had clinical signs and symptoms compatible with retropharyngeal inflammation. All patients were initially imaged with lateral neck radiographs. If lateral neck radiography showed a retropharyngeal mass, CT or magnetic resonance (MR) imaging was performed to further localize and characterize the mass. CT was performed in 10 patients. Scans were performed utilizing 5-mm slice thickness after the administration of intravenous contrast. CT numbers in adenitis were compared with CT numbers in surgically proven abscesses using an unpaired Student's *t*-test. CT numbers were measured from the center of the retropharyngeal masses in all patients who had CT. MR was per-

Received July 31, 1991; accepted and revisions requested September 24; revisions received October 30.

Presented at the 29th Annual Meeting of the American Society of Neuroradiology, Washington, DC, June 9-14, 1991.

¹ Department of Radiology, Arkansas Children's Hospital, 800 Marshall Street, Little Rock, AR 72202. Address reprint requests to C. M. Glasier, MD.

² Department of Pediatrics, Arkansas Children's Hospital, 800 Marshall Street, Little Rock, AR 72202.

³ Department of Radiology, University of Arkansas for Medical Sciences, 4301 West Markham Street, Little Rock, AR 72205.

AJNR 13:1191-1195, Jul/Aug 1992 0195-6108/92/1304-1191

© American Society of Neuroradiology

TABLE 1: Retropharyngeal abscess in children: clinical and imaging data

Pt/Age/Sex	CT/MR	Ultrasound	Clinical Course
01/1 yr/F	Right parapharyngeal low attenuation mass with ring enhancement	Mass with fluid center	Abscess drained in OR with US guidance
02/4 yr/F	Prevertebral mass low attenuation center	Mass with fluid center	Abscess drained in OR with US guidance
03/4 yr/M	Low attenuation mass Left RP	Solid mass	Attempted OR drainage: no fluid, improved on IV antibiotics
04/7 yr/M	Right parapharyngeal low attenuation mass	No fluid on serial scans	Improved on IV antibiotics
05/1 yr/F	Right parapharyngeal mass with low attenuation center	Complex mass with sonolucent components	OR drainage under US guidance
06/2 yr/M	Right parapharyngeal low attenuation mass with ring enhancement	Enlarged RP nodes; no fluid	Improved on PO antibiotics
07/11 yr/M	Left parapharyngeal mass with ring enhancement (MR)	Solid mass; no fluid	No fluid on OR aspiration; improved rapidly on IV antibiotics
08/2 yr/F	Low attenuation RP mass	Solid mass; no fluid	Improved on IV antibiotics
09/3 yr/M	Low attenuation RP mass with ring enhancement	Solid mass; no fluid	Improved on IV antibiotics
10/5 yr/M	Left parapharyngeal low attenuation mass	Solid mass; no fluid	Improved on IV antibiotics
11/6 yr/M	Low attenuation RP mass	Solid mass; no fluid	Improved on IV antibiotics

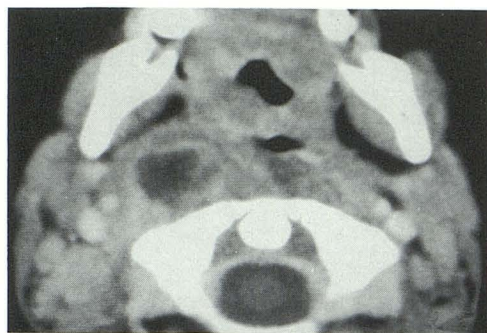
Note.—Pt, patient reference number; RP, retropharyngeal; OR, operating room; PO, postoperative; IV, intravenous.

formed in one patient on a 1.5-T scanner. Sagittal T1-weighted scans, axial and coronal proton density and T2-weighted scans were performed prior to the administration of intravenous contrast and axial and coronal T1-weighted images were performed after the administration of gadopentatate dimeglumine (0.2 mL/kg). The younger patients were sedated for CT or MR with pentobarbital (5–6 mgm/kg intravenously). US was performed in all 11 patients either for characterization of the mass or to aid the surgeon in locating the mass in the operating room for US-guided drainage. All US examinations were real time only, using either 5- or 7-MHz linear transducers. Patients were placed supine with the neck slightly hyperextended. Transverse and oblique views were obtained as indicated by patients' anatomy and location of mass within retropharyngeal space. A radiologist was present during the US examination in all cases. Preoperative US was performed without sedation. Gain and depth settings were individualized to allow visualization of the carotid arteries and jugular veins without artifactual intraluminal echoes. Five patients had intraoperative US. In two of these five children, the intraoperative examination was the only US performed. The other three had both preoperative US and intraoperative guidance for abscess drainage.

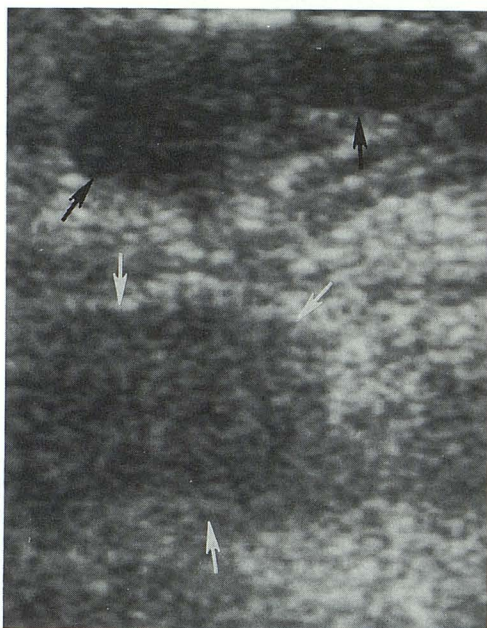
Results

All patients had CT or MR findings compatible with retropharyngeal abscess. CT findings include

low attenuation retropharyngeal masses with variable peripheral enhancement in 10 children. CT numbers were calculated by placing region of interest boxes within the low attenuation masses. CT numbers ranged from 0–12 in three patients with abscess and 2–19 in seven children with adenitis. MR showed a focal retropharyngeal mass that was hyperintense on T2-weighted images, and showed low intensity on T1-weighted images with peripheral enhancement after the administration of intravenous gadolinium. In three of these patients, surgical drainage of suspected abscess with US guidance was successful. US-guided surgical drainage of retropharyngeal inflammatory masses was attempted in two other children. In these two children, preoperative US was not performed and intraoperative US showed the mass to be solid, and no fluid was aspirated despite US-guided placement of a needle into the inflammatory mass. In six patients, US showed no drainable fluid within retropharyngeal solid masses despite CT findings compatible with abscess. These children had rapid resolution of clinical signs and symptoms after the administration of intravenous antibiotics. Serial US was used in the nonsurgical patients to show the gradual



A



B

Fig. 1. Retropharyngeal adenitis (patient 8). Axial contrast-enhanced CT (A) shows low attenuation mass with ring enhancement in right retropharyngeal space. Longitudinal US (B) shows echogenic mass (*white arrows*) compatible with adenitis. Hypoechoic superficial cervical lymph nodes are noted at the top of the image (*black arrows*). Paramedian retropharyngeal soft tissues are seen at the bottom of the print.

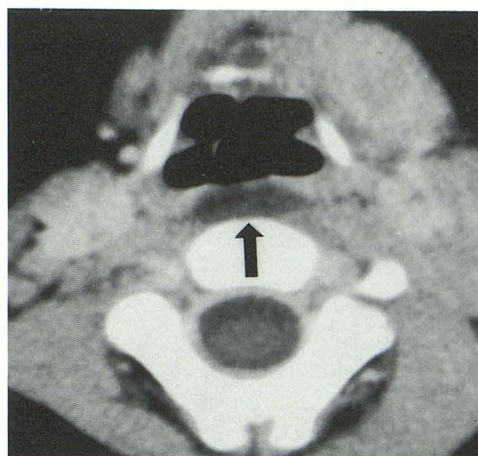
shrinkage of the masses in response to antibiotic therapy.

Discussion

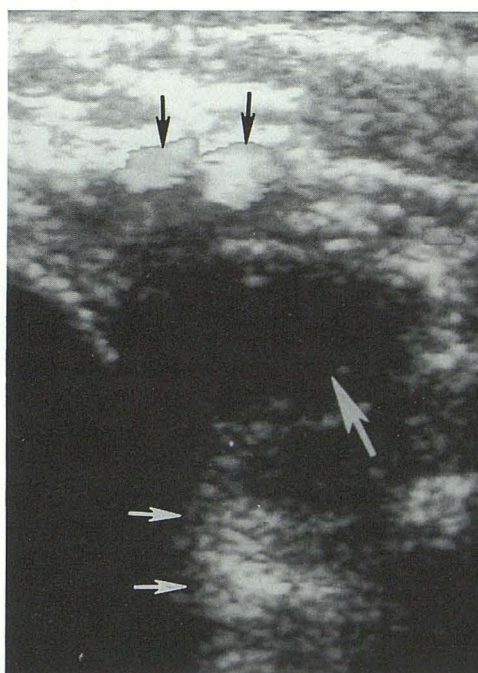
The retropharyngeal space is located between the middle and deep layers of the deep cervical fascia behind the pharyngeal constrictor muscles and anterior to the vertebral bodies. The retropharyngeal space extends upward to the skull base and communicates with the superior mediastinum. A median raphe divides the space with chains of lymph nodes on either side in a paramedian location. Extensive communication exists

between these nodes that receive drainage from the pharynx, paranasal sinuses, and middle ear.

Symptoms and signs of retropharyngeal infection in young children are caused by inflammation of the retropharyngeal lymph nodes and include fever, drooling, stridor, and unusual neck posturing (1-3). Complications of retropharyngeal abscess are well known and include airway obstruction, rupture into the trachea with aspiration,



A



B

Fig. 2. Retropharyngeal abscess (patient 2). Axial contrast-enhanced CT (A) shows low attenuation retropharyngeal mass (*black arrow*). Transverse US (B) demonstrates hypoechoic mass in retropharynx (*large white arrow*) with posterior acoustic enhancement (*small white arrows*). Flow in the internal carotid artery and jugular vein is seen anteriorly (*black arrows*). The anechoic space to the left of the figure is the trachea. Purulent material was drained at surgery using US guidance.

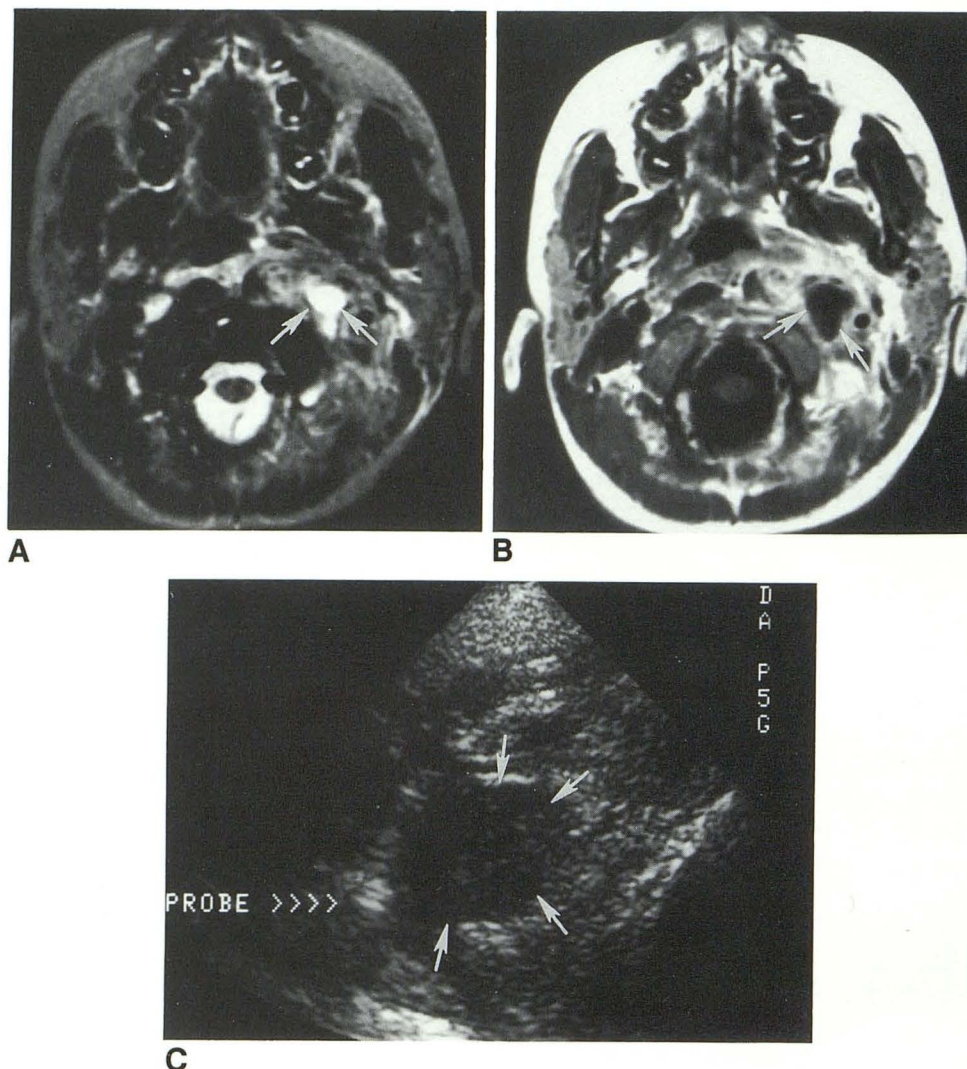


Fig. 3. Retropharyngeal adenitis (patient 7). Axial T2-weighted MR (A) image shows hyperintense left retropharyngeal mass (white arrows) with surrounding soft-tissue edema. Axial T1-weighted gadolinium enhanced scan (B) shows low signal left retropharyngeal mass with peripheral enhancement (white arrows). Intraoperative neck US (C) shows round, solid mass (white arrows) into which a transoral probe has been passed.

mediastinal extension, and vascular complications such as jugular venous thrombosis or carotid rupture (4, 5). Conventional radiographic evaluation of children with suspected retropharyngeal infection consists of a lateral radiograph taken during inspiration with the neck extended. Expiratory or flexion radiographs may cause spurious widening of the retropharyngeal tissues, especially in infants and younger children. In questionable cases, fluoroscopy may be necessary.

Contrast CT is useful in localizing retropharyngeal inflammation. In addition, complications such as vertebral osteomyelitis, jugular venous thrombosis, or mediastinal extension of an inflammatory mass can be detected. Published CT

criteria for diagnosis of retropharyngeal abscess have included focal low attenuation mass sometimes with ring enhancement (6). All 10 of our patients who had CT showed low attenuation retropharyngeal masses, but only three had drainable pus. In an attempt to separate adenitis from abscess on CT, we retrospectively measured CT numbers from the center of the retropharyngeal masses in patients with both abscess and adenitis. CT numbers ranged from 0–12 in the patients with abscess and from 2–19 in adenitis. There was no statistically significant difference in CT numbers between these two groups (unpaired Student's *t*-test, $P > .3$).

US has been shown to be useful in the evaluation of neck masses in children (7). In adenitis,

US typically shows a homogeneous, hypoechoic mass (Fig. 1). Abscesses are seen as lobulated, complex masses with partially anechoic centers (8) (Fig. 2). US was able to distinguish adenitis from abscess in all of our patients.

With early clinical suspicion and the liberal use of antibiotics, retropharyngeal abscess may be less common than adenitis. In our experience and in the experience of Ben-Ami (8, 9), sonographically solid retropharyngeal inflammatory masses (adenitis) are adequately treated with intravenous antibiotics without the need for surgical intervention. The goal of imaging, therefore, should be to define the extent of retropharyngeal inflammation and to distinguish adenitis from abscess.

In our early experience, two patients were taken to the operating room for drainage based on the combination of clinical symptoms and contrast CT or MR findings (Fig. 3). Using intraoperative US, these patients were found to have sonographically solid masses and no pus could be aspirated. These patients recovered uneventfully with intravenous antibiotic therapy alone.

Our current imaging protocol in children with suspected retropharyngeal infection is to initially obtain a lateral soft-tissue radiograph of the neck. If there is retropharyngeal soft-tissue swelling, contrast CT is performed. If a focal low attenuation mass is seen on CT, the child is begun on intravenous antibiotics and an US is performed to determine if the mass is solid, compatible with

adenitis, or complex, suggesting abscess. If an abscess is diagnosed by US, intraoperative drainage is performed using US guidance. If the mass appears solid on US, antibiotics are continued and the child may be followed-up with serial sonography to exclude subsequent abscess formation. Since we have begun using this protocol of combined modality imaging with US and contrast CT, we have avoided unnecessary surgical intervention in children with retropharyngeal adenitis without abscess.

References

1. Brown JM. Acute retropharyngeal abscesses in children. *Laryngoscope* 1919;29:9-12
2. Frank I. Retropharyngeal abscess. *JAMA* 1921;77:517-522
3. Beck AL. The influence of the chemotherapeutic and antibiotic drugs on the incidence and course of deep neck infections. *Ann Otol* 1952;61:515-532
4. Barratt GE, Koopmann CF, Coulthard SW. Retropharyngeal abscess: a ten-year experience. *Laryngoscope* 1984;94:455-463
5. Ramilo J, Harris VJ, White H. Empyema as a complication of retropharyngeal and neck abscesses in children. *Radiology* 1978;126:743-746
6. Bredenkamp JK, Maceri DR. Inflammatory torticollis in children. *Arch Otolaryngol Head Neck Surg* 1990;116:310-313
7. Lewis GJS, Leithiser REL Jr, Glasier CM, Iqbal V, Stephenson CA, Seibert JJ. Ultrasonography of pediatric neck masses. *Ultrasound Q* 1989;7:315-355
8. Ben-Ami T, Yousefzadeh DK, Aramburo MJ. Pre-suppurative phase of retropharyngeal infection: contribution of ultrasonography in the diagnosis and treatment. *Pediatr Radiol* 1990;21:23-26
9. Kraus R, Han B, Babcock DS, Oestreich AE. Sonography of neck masses in children. *AJR* 1986;146:609-613