



## Discover Generics

Cost-Effective CT & MRI Contrast Agents

 FRESENIUS  
KABI

[WATCH VIDEO](#)

# AJNR

## **Acute thrombosis of the intracranial dural sinus: direct thrombolytic treatment.**

F Y Tsai, R T Higashida, V Matovich and K Alfieri

*AJNR Am J Neuroradiol* 1992, 13 (4) 1137-1141

<http://www.ajnr.org/content/13/4/1137>

This information is current as  
of June 18, 2025.

# Acute Thrombosis of the Intracranial Dural Sinus: Direct Thrombolytic Treatment

Fong Y. Tsai,<sup>1</sup> Randall T. Higashida,<sup>2</sup> Violet Matovich<sup>1</sup> and Kenneth Alfieri<sup>1</sup>

**Summary:** Acute intracranial dural sinus thrombosis may have severe morbidity or fatal complications without appropriate treatment. Direct dural sinus venography can be performed safely with a soft Tracker catheter to document the fresh thrombus as an adjunct to CT or MR. We are reporting our experience with successful direct urokinase thrombolytic therapy in three cases of superior sagittal sinus and two cases of transverse and sigmoid sinus thrombosis. All five patients have recovered completely without any residual clinical deficit.

**Index terms:** Thrombosis, dural sinus; Dural sinuses; Thrombolysis

Cerebral venous thrombosis is an uncommon disorder with many etiologies. Clinical manifestations vary from mild transient symptoms to death. Early diagnosis and treatment are essential for patients with progressive neurologic deficits (1–3).

Five patients with acute superior sagittal or transverse sinus thrombosis were treated by direct intrasinus thrombolytic therapy utilizing urokinase. All five patients had good neurologic recovery. Our data supports the fact that direct venography of thrombosed intradural sinuses can be performed without difficulty and thrombolytic treatment may be effective in improving patient outcome. The technique, diagnostic considerations, and treatment results of dural sinus catheterization and thrombolysis are discussed.

## Methods

Direct dural sinus venography was performed by a percutaneous transfemoral venous approach. A 5-F polyurethane guiding catheter was placed from the femoral vein, through the inferior vena cava, right atrium, internal jugular vein, and jugular bulb. Five thousand units of heparin was then injected intravenously for systemic anticoagulation. A 2.7-F Tracker catheter, with an 0.016 inch

platinum steerable guidewire, was then passed coaxially through the 5-F guiding catheter and directed into the sigmoid sinus, transverse sinus, torcula, and into the superior sagittal sinus. Digital sinus venography was performed with 4 mL of Omnipaque 300 injected by hand over 2 seconds (4).

Thrombolytic therapy was performed utilizing bolus injections of urokinase, 80,000 IU over 5 minutes, at 15-minute intervals, directly into the occluded sinus. The Tracker catheter was removed after recanalization of the dural sinus was documented by repeat sinus venography. The femoral catheter was removed after one-half life of heparin (60 minutes), without protamine reversal. Following direct thrombolytic therapy, the patient was converted to oral anticoagulants and then discharged.

## Case 1

A 38-year-old man with a long history of intravenous cocaine abuse was admitted to the emergency room with seizures. He was found to have papilledema and right lower extremity weakness. A computed tomography (CT) head scan demonstrated left-sided cerebral edema and evidence suggesting sagittal sinus thrombosis (Fig. 1). A magnetic resonance (MR) scan confirmed this diagnosis. Despite intravenous heparin treatment, the patient continued to decline neurologically and became less responsive. Cerebral angiography was performed and documented complete occlusion of the superior sagittal sinus. Direct superior sagittal sinus digital venography and urokinase treatment was then performed. A total dose of 500,000 IU of urokinase was given over 2 hours.

Follow-up venography immediately after therapy, demonstrated recanalization of the posterior half of the superior sagittal sinus. Subsequent angiography 2 days later reconfirmed recanalization of the superior sagittal sinus. Seven days later, the patient had recovered completely without residual symptoms.

## Case 2

A 46-year-old man was admitted with increasingly severe headaches, blurred and double vision, and progressive

Received September 26, 1991; accepted October 15.

<sup>1</sup> Department of Radiology, University of Missouri-Kansas City, School of Medicine, 2301 Holmes Street, Kansas City, MO 64108. Address reprint requests to F. Y. Tsai, MD.

<sup>2</sup> Department of Radiology, University of California San Francisco, School of Medicine, San Francisco, CA 94143.

AJNR 13:1137–1141, Jul/Aug 1992 0195-6108/92/1304-1137 © American Society of Neuroradiology



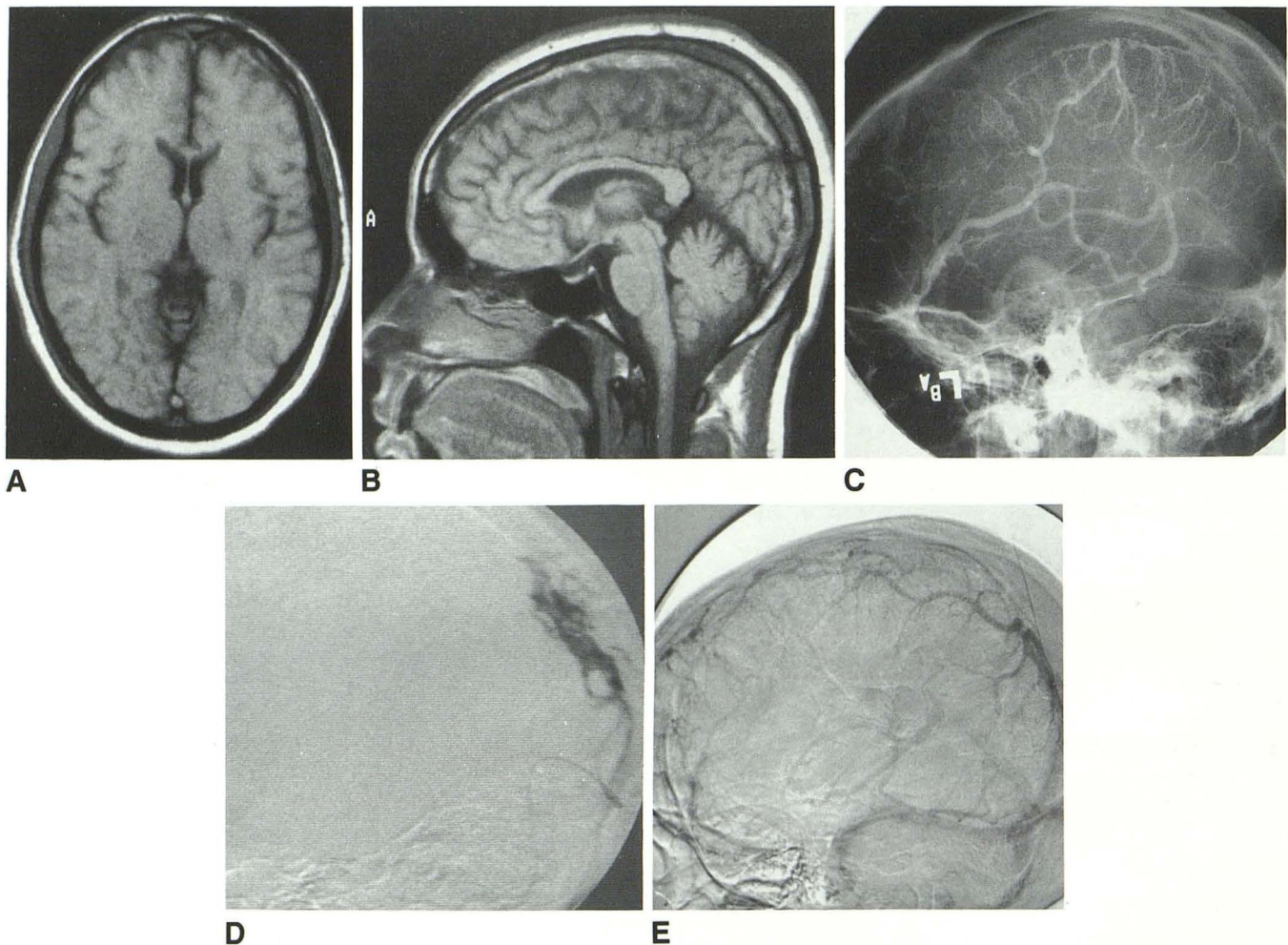


Fig. 1. *A* and *B*, MR shows increased intensity of superior sagittal sinus on T1-weighted images 550/30/2 (TR/TE/excitations). *C*, Venous phase of left carotid angiogram shows nonopacification of superior sagittal sinus. *D*, Selective superior sagittal sinus digital venography shows multiple filling defect in the posterior one third of the sagittal sinus due to thrombi. *E*, Venous phase of follow-up carotid angiogram shows good opacification of the posterior-superior sagittal sinus and some opacification of the anterior one third of the sinus.

deterioration of his mentation. He had a recent history of intravenous drug use. MR showed thrombosis of both the superior sagittal sinus and right transverse sinus (Fig. 2). Cerebral angiography and direct digital sinus venography were performed. The latter was via the left internal jugular vein. During the procedure, the Tracker catheter could not be advanced beyond the distal one third of the contralateral, right sigmoid sinus. Venography revealed occlusion of the right sigmoid sinus and superior sagittal sinus. Three hundred fifty thousand IU of urokinase was infused in the superior sagittal sinus and another 250,000 IU in the right transverse sinus from the left-sided catheter. A total of 600,000 IU of urokinase was used in the treatment. The sagittal and right transverse sinuses were open on repeat venography after treatment. Subsequently, the patient recovered without residual symptoms.

### Case 3

A 52-year-old man with a long history of alcoholism and head trauma in the past was admitted because a family

member was unable to awaken him. Examination at admission revealed right hemiparesis and a semicomatose state. A CT head scan demonstrated a slight shift of midline structures toward the right side, and an "empty delta" sign indicating superior sagittal sinus thrombosis (Fig. 3). Superior sagittal sinus venography confirmed the diagnosis. The patient was then treated with intrasinus infusion of urokinase. A total of 500,000 IU was used. After treatment, he regained consciousness, but there was some residual weakness of the right extremities.

### Case 4

A 37-year-old woman was admitted for evaluation of the sudden onset of a severe headache with increasing weakness and vertigo. Physical examination revealed no evidence of papilledema. The patient was initially treated with heparin because vertebrobasilar insufficiency was suspected. However, despite treatment, her symptoms did not improve, but worsened. An MR of the head showed multiple



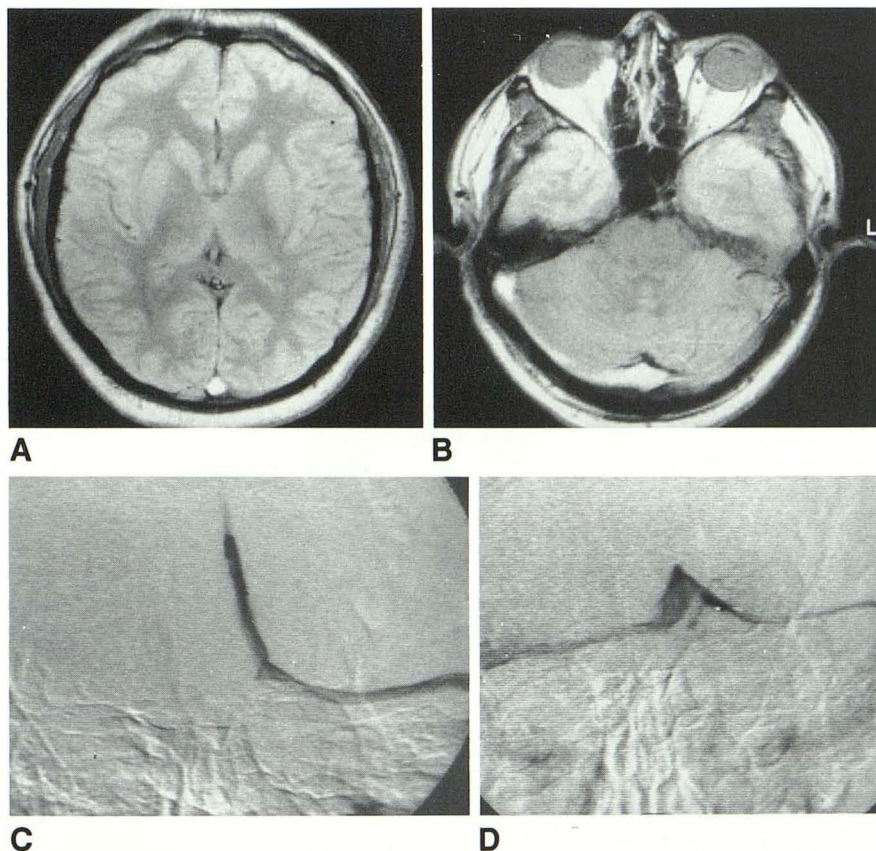


Fig. 2. A and B, Spin density (3000/100/2) MR shows increased signal intensity of the superior sagittal transverse sinus and torcula. The ventricles are small due to cerebral swelling.

C, Digital venography of superior sagittal sinus after partial treatment with urokinase shows occlusion of right transverse sinus but the superior sagittal sinus is reopacified.

D, Digital venography after final treatment shows reopening of right transverse sinus.

foci of increased T2 signal intensity in the cerebellum (Fig. 4). Also, hyperintensity was seen on T1- and T2-weighted images in the proximal left sigmoid sinus, indicating sinus thrombosis.

Direct dural sinus venography was performed via the right transverse sinus with the microcatheter passing through the torcula into the left transverse sinus. A large segment of thrombus was demonstrated in the proximal sigmoid sinus, at the junction with the left transverse sinus. Direct urokinase therapy was initiated and a total dose of 250,000 IU was given. Repeat venography showed the thrombus to be completely lysed, the sigmoid sinus becoming widely patent. The patient recovered neurologically from this episode with complete resolution of her symptoms.

### Case 5

A 48-year-old man presented with increasingly severe headache and photophobia 1 day prior to admission. He suffered from increasing weakness and rapidly decreasing mentation. MR showed evidence of left transverse sinus thrombus (Fig. 5). Emergent direct sinus venography confirmed the diagnosis. Subsequently, urokinase treatment was performed immediately after venography. The thrombus was dissolved with less than 200,000 IU. He recovered without any residual deficit.

### Discussion

Cerebral venous thrombosis is a rare syndrome associated with a large variety of disease processes. The clinical severity depends upon the extent of the thrombosis, the vessels involved, and the chronicity of the thrombi. Occasionally, patients with dural sinus thrombosis present with mild symptoms due to incomplete occlusions or well-established collaterals. Acute occlusion of the superior sagittal sinus or the dominant transverse and sigmoid sinus are usually not well tolerated. These occlusions, especially those involving the posterior one half of the superior sagittal sinus, may lead to massive cerebral edema, venous congestion, and/or infarction (1-3). The diagnosis can be made by CT, MR, or angiography (5-9). We observed three patient deaths from massive infarcts and hemorrhages from acute superior sagittal sinus occlusion that were not treated by thrombolytic therapy.

The treatment of choice for acute major dural sinus thrombosis is still not settled, but rapid recanalization of the affected vessels is essential if collateral flow is minimal. Surgical thrombectomy, anticoagulants, and intravenous thrombolytics have been used. Despite these interventions, the results have been poor (3). The prior



Fig. 3. A, Contrast-enhanced CT scan shows a filling defect in the superior sagittal sinus and slight shift of midline structures to the right.

B, Venous phase of carotid angiography shows nonopacification of superior sagittal sinus.

C, Digital venography of superior sagittal sinus shows multiple filling defects due to thrombi.

D, Digital venography of superior sagittal sinus after urokinase treatment shows good opacification of dural sinuses.

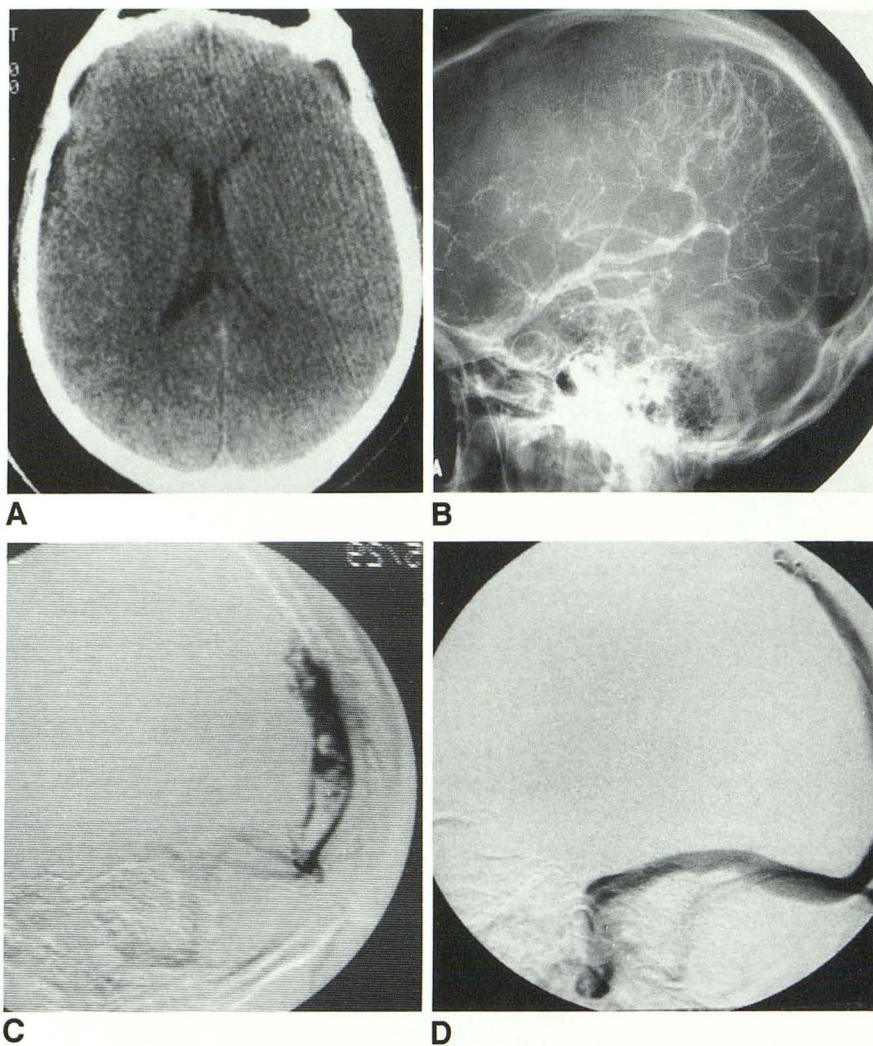
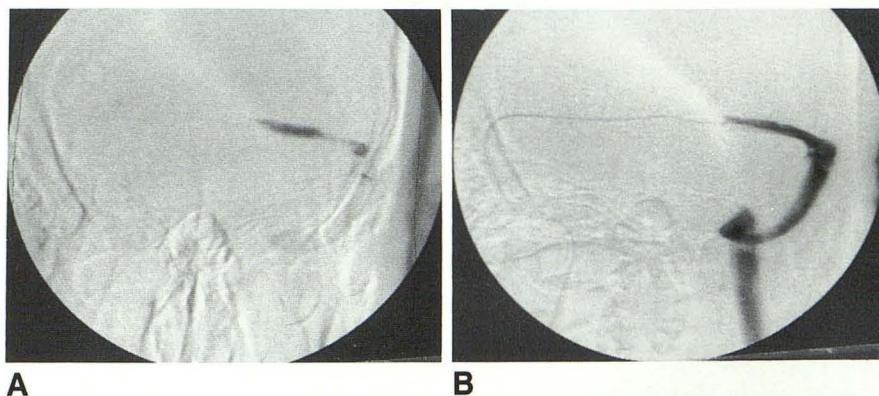


Fig. 4. A, Left transverse sinus venography shows nearly total occlusion of distal sinus.

B, Venography after complete thrombolysis shows normal transverse and sigmoid sinuses.



failure of systemic thrombolytics may be due to the low concentration of these agents at the site of the thrombus. Intraarterial injection of thrombolytics has been proven to be useful in dissolving acute arterial thrombus (10–12), especially when selectively injected. Direct injection of thrombolytic drugs into dural sinus thrombus improves the efficacy of the thrombolytics (14, 15) just as

selective arterial injections have improved the treatment of acute arterial thrombosis. However, direct urokinase treatment of dural sinus thrombi requires superselective catheterization of the dural sinus itself.

Jugular and cavernous sinus venography have been performed for the past two decades. Recent advances in angiographic technique and catheter



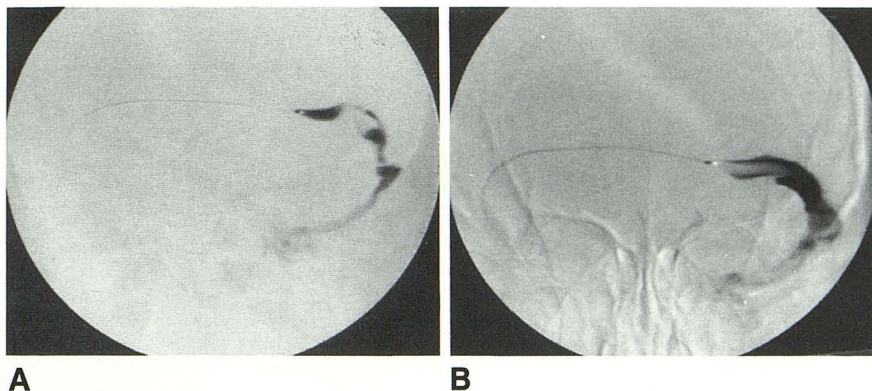


Fig. 5. A, Left transverse sinus venography shows thrombus in the distal transverse and proximal sigmoid sinuses.

B, Repeat venography after treatment with urokinase shows normal left transverse and sigmoid sinuses.

technology now enables the neuroradiologist to perform direct selective venography of intracranial dural sinuses. With this technique, venous embolization of dural AVM fistulae and tumor extensions has been performed (4, 13–15). This technique also now allows the direct infusion of thrombolytics into acute thrombus.

There are few complications associated with direct dural sinus venography. Digital venography can be performed with a very small amount of contrast material, thus avoiding injury to the dural sinuses. Systemic heparinization and continuous infusion of heparinized saline through the catheter prevents most catheter-related thrombosis. Extra caution must be taken to avoid injury to the wall of the dural sinus by gentle advancement or manipulation of the guidewire and catheter. This complication is unlikely because of the soft Tracker tip. Pressure placed upon the sinus wall can cause severe pain which can be kept to a minimum with the soft catheters now employed.

Transvenous, selective direct venography of dural sinuses is safer and easier than the direct puncture of the sagittal sinus (14, 15). Although there is risk of dislodging thrombi into the pulmonary artery system, there has been no clinical manifestation of this complication in any of the five patients we have treated.

Based on our series, direct dural sinus venography is a relatively safe procedure and direct urokinase infusion should be considered for treatment of acute dural sinus thrombosis. Although thrombolytic treatment for fresh thrombus is most effective, the response to treatment of older thrombus is not clear. Cases 1 and 2 had onsets of symptoms approximately 2 days prior to urokinase treatment, but urokinase treatments were performed within 1 day of rapid clinical deterioration. Therapy by direct urokinase infusion into

the thrombus was successful in all five cases and there was documented improvement angiographically and clinically following treatment.

## References

1. Jaeger R. Observation and resection of the superior longitudinal sinus at mid posterior to the Rolandic inflow. *Neurosurgery* 1951;18:103–109
2. Repka MS, Miller NR. Papilledema and dural sinus obstruction. *J Clin Neurol Ophthalmol* 1984;4:247–250
3. Gates PC, Barnett HJM. Venous disease in cortical veins and sinuses. In: Barnett HJM, Stein BM, Mohr JP, Yatsu FM, eds. *Stroke*. New York: Churchill Livingstone, 1986;2:731–762
4. Halbach VV, Higashida RT, Hieshima GB, Mehringer CM, Hardin CW. Transverse embolization of dural fistula involving the transverse and sigmoid sinus. *AJNR* 10:385–392
5. Zilkha A, Diaz AS. Computed tomography in the diagnosis of superior sagittal sinus thrombosis. *J Comput Assist Tomogr* 1980;4:124–126
6. Brant-Zawadzki M, Chang GY, McCarty GE. Computed tomography in dural sinus thrombosis. *Arch Neurol* 1982;39:446–447
7. McMurdo SK Jr, Brant-Zawadzki M, Bradley WG Jr, Chang GV, Berg BO. Dural sinus thrombosis: study using intermediate field strength MR imaging. *Radiology* 1986;161:83–86
8. Snyder TC, Sachdev HS. MR imaging of cerebral dural sinus thrombosis. *J Comput Assist Tomogr* 1986;10:889–891
9. Sze G, Simmons B, Krol G, Walker R, Zimmerman RD, Deck MD. Dural sinus thrombosis: verification with spin-echo techniques. *AJNR* 1988;9:679–686
10. Belkin M, Belkin B, Bucknam CA, Straub JJ, Lowe R. Intra-arterial fibrinolytic therapy. *Arch Surg* 1986;121:769–773
11. Traughber PD, Cook PS, Micklos TJ, Miller FJ. Intra-arterial fibrinolytic therapy for popliteal and tibial artery obstruction. *AJR* 1987;149:453–456
12. Sherry S. Thrombolytic therapy for deep venous thrombosis. *Semin Intervent Radiol* 1985;2:331–337
13. Halbach VV, Higashida RT, Hieshima GB, Dowd CF, Barnwell SL. Venography and venous pressure monitoring in dural sinus meningiomas. *AJNR* 1989;10:1209–1213
14. Scott JA, Pascuzzi RM, Hall PV, Becker GH. Treatment of dural sinus thrombosis with local urokinase infusion. *J Neurosurg* 1988;68:284–287
15. Higashida RT, Helmer E, Halbach VV, Hieshima GB. Direct thrombolytic therapy for superior sagittal sinus thrombosis. *AJNR* 1989;10:S4–S6