



## Discover Generics

Cost-Effective CT & MRI Contrast Agents



FRESENIUS  
KABI

WATCH VIDEO

# AJNR

## Crossed cerebellar diaschisis and loss of consciousness during temporary balloon occlusion of the internal carotid artery.

D A Eckard, P D Purdy and F Bonte

*AJNR Am J Neuroradiol* 1992, 13 (1) 55-57

<http://www.ajnr.org/content/13/1/55>

This information is current as  
of June 6, 2025.

# Crossed Cerebellar Diaschisis and Loss of Consciousness during Temporary Balloon Occlusion of the Internal Carotid Artery

Donald A. Eckard,<sup>1</sup> Phillip D. Purdy,<sup>1</sup> and Fred Bonte,<sup>1</sup>

**Summary:** We encountered a case of crossed cerebellar diaschisis during temporary balloon occlusion of the internal carotid artery in a 59-year-old woman. The rapidity of the diaschisis was unusual and SPECT scanning was adequate to show the early defect.

**Index terms:** Single photon emission computed tomography (SPECT); Cerebral blood flow; Arteries, carotid; Interventional neuroradiology, complications of

Crossed cerebellar diaschisis refers to decreased blood flow and oxygen consumption in a cerebellar hemisphere secondary to decreased function of the contralateral cerebral hemisphere. This phenomenon has been observed in infarcts, hemorrhages, tumors, and during unilateral hemispheric anesthesia (Wada test) with sodium amobarbital by using various blood flow imaging agents (1–3). We report a case of crossed cerebellar diaschisis encountered during temporary balloon occlusion of the internal carotid artery. The diaschisis developed within 10 sec of occlusion, suggesting an abrupt metabolic change encountered in both groups of neurons.

## Case Report

A 59-year-old white woman was admitted for evaluation of double vision. Physical examination revealed a right 3rd and 4th nerve palsy without other abnormalities. Computed tomography (CT) and magnetic resonance (MR) imaging were negative. Cerebral arteriography showed a small aneurysm of the right cavernous carotid artery that projected toward the region of the superior orbital fissure. The anterior communicating artery and the posterior communicating artery did not fill despite cross-compression. Following the arteriogram, the patient was noted to be lethargic, aphasic, and hemiparetic on the right. She subsequently had a Tc-99m HMPAO (Ceretek) brain blood flow study

performed by injecting 25 mCi of Tc-99m HMPAO and obtaining images with a high resolution single photon emission computed tomography (SPECT) camera (Toshiba Medical Systems, Tustin, CA). This showed slightly increased uptake in the left cortex but normal flow to the remainder of the brain including the cerebellum (Fig. 1). The patient subsequently recovered completely from the neurologic deficits sustained during the first arteriogram and returned for a trial occlusion of the right internal carotid artery prior to anticipated occlusion for aneurysm treatment. For trial occlusion, a balloon occlusion catheter (Meditech, Watertown, MA) was positioned in the right internal carotid artery, and the artery was occluded. The patient lost consciousness within several seconds of inflation, so it was quickly deflated and the patient immediately regained consciousness. Because of this unusual response to right internal carotid artery occlusion, the artery was occluded a second time with careful monitoring of the patient. Immediately after balloon inflation, 25 mCi of Tc-99m HMPAO was injected as an intravenous bolus. The patient was asked to count as the balloon was inflated and to grip the hands of two assistants. After inflating the balloon, the patient counted to seven before she again lost consciousness, thus also losing grip strength in both hands. Her heart rate remained stable. The balloon was immediately deflated and she regained consciousness, at which time she picked up her counting with the number 30. The total time of occlusion was approximately 15 sec. The brain blood flow study obtained following the carotid occlusion used the same SPECT camera as used in the initial study. It showed decreased uptake in the right cerebral hemisphere as well as decreased uptake in the contralateral (left) cerebellar hemisphere consistent with crossed cerebellar diaschisis (Fig. 2).

## Discussion

Technetium-99m labeled hexamethyl propylene amine oxine (Tc-99m HMPAO (Ceretek)) is a substance which is regionally distributed in pro-

Received February 12, 1991; revision requested May 15; revision received June 6; final acceptance July 8.

<sup>1</sup> All authors: The University of Texas Southwestern Medical Center, 5323 Harry Hines Boulevard, Dallas, TX 75235-8896. Address reprint requests to P. D. Purdy.

AJNR 13:55–57, Jan/Feb 1992 0195-6108/92/1301-0055 © American Society of Neuroradiology



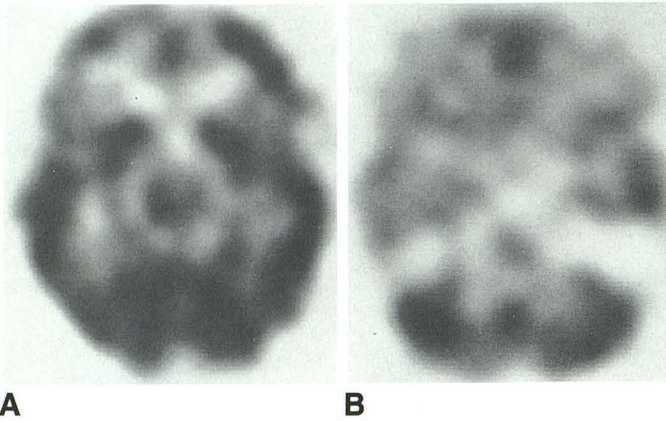


Fig. 1. Tc-99m HMPAO SPECT images obtained after initial arteriogram.

A and B, Axial images through cerebral hemisphere and cerebellum show mild hyperemia of left cerebral cortex with symmetric uptake in cerebellar hemispheres.

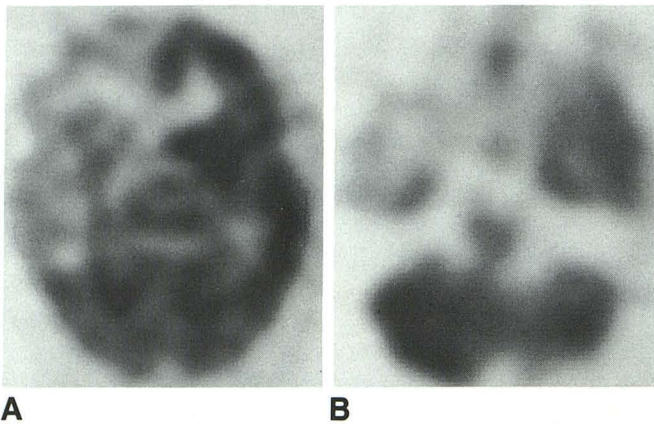


Fig. 2. Tc-99m HMPAO SPECT images obtained after temporary balloon occlusion of the right internal carotid artery.

A and B, Axial images show decreased uptake in the right cerebral hemisphere and the left cerebellar hemisphere consistent with crossed cerebellar diaschisis.

portion to local cerebral blood flow. It is a lipophilic substance that becomes trapped intracellularly where it is converted to a hydrophilic form that cannot pass the cell membrane. After the initial lipophilic phase of less than 5 min, the distribution of Tc-99m HMPAO is stable for several hours (3). Thus, it can be used as a marker of blood flow during temporary occlusion, though imaging is performed several hours later using a SPECT camera.

The concept that a transient depression of cerebral function can occur at some distance from a focal lesion was ascribed to Von Monakow in 1914 (1). He applied the term diaschisis to describe this phenomenon. In 1958, Kempinsky showed that focal injury of the cerebral cortex

resulted in a transient depressive effect upon cortical electrical activity in the contralateral cerebral hemisphere as long as the corpus callosum was intact (4). This did not occur if the corpus callosum had been severed. He proposed that the activity of one neuronal group is facilitated by the constant impulses from a second group. If this second group is destroyed, then the first group is deprived of one of its usual sources of facilitation and consequently becomes less active. Decreased neuronal activity results in decreased cerebral metabolic rate for oxygen and decreased cerebral blood flow. By using blood flow imaging techniques, it is possible to detect regions of diaschisis.

It is known that there are many connections between the cerebral hemispheres and the cerebellum. The most important of these, in terms of number of connections, is the corticopontocerebellar pathway (5). In fact, the corticopontocerebellar system, with almost 19 million projections per hemisphere, has about 40 times the connections of all other cerebellar afferent sources combined. The cerebellum receives contralateral input from all major neocortical areas via pontine nuclei which decussate to connect to the contralateral cerebellar hemisphere. The relative contributions from different cortical areas in man is not well known but has been studied in the rhesus monkey (6, 7). The most dense corticopontine projections arise in the sensorimotor cortex and from parts of the visual cortex. Many connections also arise from the premotor area. Fewer fibers arise in the more anterior frontal and lateral temporal association areas. Most of the projections to the cerebellar hemispheres relate to the motor and premotor cortex, whereas the somatosensory and parietal association areas project to the paramedian lobule and the visual cortex provides input to the paraflocculus and superior vermis. Therefore, it is not surprising to see decreased activity in both the cerebral hemisphere that has been compromised and the contralateral cerebellum.

An interesting aspect of this case is the rapidity of the diaschisis. Previous studies of brain blood flow in patients with strokes and hemorrhages have been performed at least 6 hr after the event. Recently, brain blood flow imaging has been used to investigate patients during intracarotid sodium amytal procedures (3, 8, 9). When the blood flow imaging agent was injected 20 to 60 sec following the amytal, decreased blood flow to the ipsilateral hemisphere was observed in all patients, with crossed cerebellar diaschisis seen in most pa-



tients. These studies also confirm that crossed cerebellar diaschisis is a rapid phenomenon. In this case, diaschisis occurred within approximately 10 sec of occlusion. Thus, even a brief reversible insult to a group of neurons can result in the altered metabolic function of a second group of interconnected neurons. Presumably this is due to sudden loss of facilitation.

The reason for the loss of consciousness, rather than development of hemiparesis, is not known. The temporary occlusion procedure was performed twice with the same response. The heart rate did not dramatically decrease during occlusion and blood pressure was not significantly changed from baseline. Traditionally, loss of consciousness is hypothesized to require diffuse bilateral cerebral hemispheric malfunction or pontomesencephalic reticular formation malfunction (10). This case tempts the conclusion that there are hemispheric consciousness functions that may be unilateral. Conversely, some of the loss of blood flow to the cerebellar hemisphere may also be reflected in the brainstem. Proof of either of these could represent important validation of symptoms of "lightheadedness" or "dizziness" associated with carotid artery stenosis. Further study would be needed to draw conclusions with such broad-reaching implications.

## References

1. Martin WRW, Raichle ME. Cerebellar blood flow and metabolism in cerebral hemisphere infarction. *Ann Neurol* 1983;14:168-176
2. Lindegaard MW, Skretting A, Hagar B, et al. Cerebral and cerebellar uptake of  $^{99m}\text{Tc}$  HMPAO in patients with brain tumor studied by single photon emission computerized tomography. *Eur J Nucl Med* 1986;12:417-420
3. Ryding E, Sjöholm H, Skeidsvoll H, et al. Delayed decrease in hemispheric cerebral blood flow during Wada test demonstrated by  $^{99m}\text{Tc}$ -HMPAO single photon emission computer tomography. *Acta Neurol Scand* 1989;80:248-254
4. Kempinsky WH. Experimental study of distant effects of acute focal brain injury. *Arch Neurol Psychiatr* 1958;79:376-389
5. Brodal A. Cerebrocerebellar pathways: anatomical data and some functional implications. *Acta Neurol Scand (Suppl)* 1972;51:153-195
6. Brodal P. The corticopontine projection in the rhesus monkey: origin and principles of organization. *Brain* 1978;101:251-183
7. Brodal P. The pontocerebellar projection in the rhesus monkey: an experimental study with retrograde axonal transport of horseradish peroxidase. *Neuroscience* 1979;4:193-208
8. Kurthen M, Reichmann K, Linke DB, et al. Crossed cerebellar diaschisis in intracarotid sodium amytal procedures: a SPECT study. *Acta Neurol Scand* 1990;81:416-422
9. Biersack HJ, Linke D, Brassel F, et al. Technetium- $^{99m}$  HMPAO brain SPECT in epileptic patients before and during unilateral hemispheric anesthesia (Wada test): report of three cases. *J Nucl Med* 1987;28:1763-1767
10. Plum F, Posner JB. The diagnosis of stupor and coma, 3rd ed. Philadelphia: F. A. Davis Company, 1980;87, 153.

Please see the Commentary by Reivich on page 62 in this issue.