



Discover Generics

Cost-Effective CT & MRI Contrast Agents



FRESENIUS
KABI

WATCH VIDEO

AJNR

Creutzfeldt-Jakob disease: focal symmetrical cortical involvement demonstrated by MR imaging.

S Falcone, R M Quencer, B Bowen, J H Bruce and T P Naidich

AJNR Am J Neuroradiol 1992, 13 (1) 403-406

<http://www.ajnr.org/content/13/1/403>

This information is current as
of June 4, 2025.

Creutzfeldt-Jakob Disease: Focal Symmetrical Cortical Involvement Demonstrated by MR Imaging

Steven Falcone,¹ Robert M. Quencer,¹ Brian Bowen,¹ Jocelyn H. Bruce,² and Thomas P. Naidich^{1,3}

Summary: The authors present two biopsy-proved cases of Creutzfeldt-Jakob disease. MR appears to be more sensitive than CT in detecting pathologic changes; signal abnormalities, when found, are predominantly within gray matter and may involve only peripheral cortex.

Index terms: Dementia

Creutzfeldt-Jakob disease (CrJaD) is an uncommon form of a rapidly progressive dementia that can be difficult to distinguish clinically from other forms of dementia. Nonspecific atrophic changes or normal examinations are frequently seen on computed tomography (CT) (1–13). A previous report concluded that the value of imaging studies in the diagnosis of CrJaD resides in the ability to show cortical atrophy and to exclude focal cerebral lesions (6). We report two pathologically proved cases of CrJaD that revealed focal parenchymal abnormalities by magnetic resonance (MR) imaging (both cases) and CT (one case only).

Case Report

Case 1

This 45-year-old woman developed progressive symptoms of nausea, slow wide-based gait, decreased visual acuity, slurred speech, difficulty recognizing familiar objects, decreased recent memory, and fluttering ocular movements over a 6-month period. On admission, physical examination revealed orientation to person and place but not to time, spasticity of speech, tongue and mandibular apraxia, head thrashing, increase in muscle tone, and decreased visual acuity. Cerebrospinal fluid (CSF) protein was slightly elevated to 38 mg%. A noncontrast CT scan of the brain revealed no abnormality (Fig. 1A). MR showed

bilateral, symmetrical thickening of the occipital gyri and symmetrical increased signal intensity on T2-weighted images (Figs. 1B and 1C). The abnormality was confined to the gray matter. No atrophy or abnormal postcontrast enhancement with Gd-DTPA was present (Fig. 1D). Stereotactic biopsy of the occipital lobe showed changes compatible with CrJaD. The patient was discharged 10 days after admission and was lost to follow-up.

Case 2

This 71-year-old woman had a 5½-week history of progressive headaches, decreasing visual acuity, and loss of cognitive function. Following admission, she became comatose, exhibited decorticate posturing, and did not respond to noxious stimuli. CSF protein was elevated to 84 mg%. Contrast-enhanced CT scan of the brain (Fig. 2A) showed symmetric nonenhancing, low-attenuation lesions of both occipital lobes. No atrophy was present. T2-weighted images showed symmetric high signal intensity changes of both occipital lobes with predominant gray matter involvement (Figs. 2B and 2C) and slight mass effect. CT-guided stereotactic biopsies of both occipital lobes demonstrated histopathologic findings of a spongiform encephalopathy consistent with CrJaD on the right (Fig. 3), but no pathologic changes on the left (probably due to improper sampling). Eighteen days after admission, she was discharged to a nursing home, where she died 2 months later.

Discussion

CrJaD is a universally fatal disease of the central nervous system (CNS), that was first described by Alfons Maria Jakob in 1921. Like kuru, Gerstmann-Straussler syndrome, and scrapie, CrJaD is thought to be caused by an "unconventional virus," designated the prion (14). A prion is

Received April 23, 1991; revision requested June 5; revision received September 26; final acceptance October 2.

¹ Department of Radiology, University of Miami School of Medicine, Miami, FL. Address reprint requests to R.M. Quencer, Department of Radiology, University of Miami MRI Center, 1115 N.W. 14 St., Miami, FL 33136.

² Department of Pathology, University of Miami School of Medicine, Miami, FL 33136.

³ Department of Radiology, Baptist Hospital of Greater Miami, Miami, FL 33176.

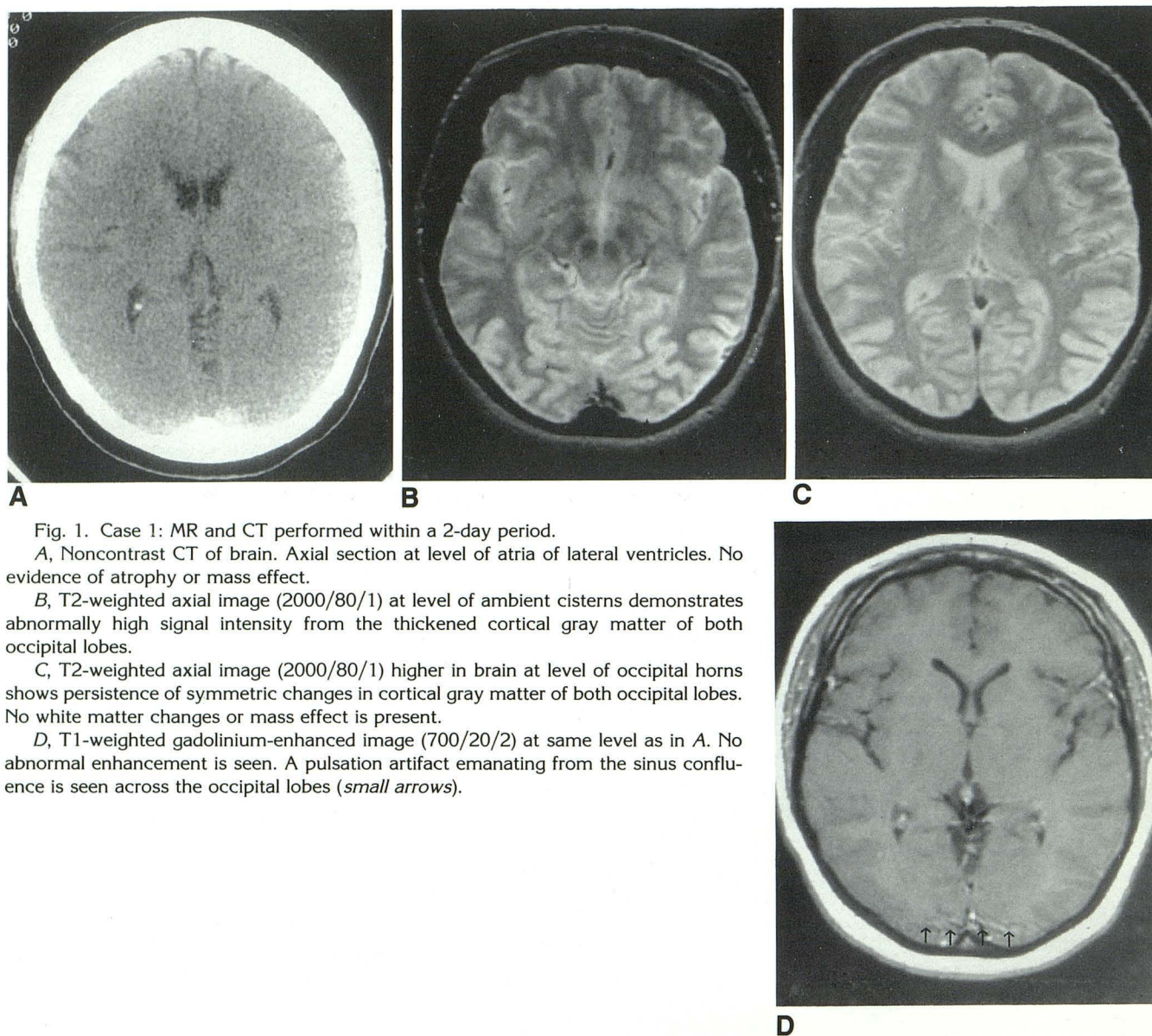


Fig. 1. Case 1: MR and CT performed within a 2-day period.

A, Noncontrast CT of brain. Axial section at level of atria of lateral ventricles. No evidence of atrophy or mass effect.

B, T2-weighted axial image (2000/80/1) at level of ambient cisterns demonstrates abnormally high signal intensity from the thickened cortical gray matter of both occipital lobes.

C, T2-weighted axial image (2000/80/1) higher in brain at level of occipital horns shows persistence of symmetric changes in cortical gray matter of both occipital lobes. No white matter changes or mass effect is present.

D, T1-weighted gadolinium-enhanced image (700/20/2) at same level as in A. No abnormal enhancement is seen. A pulsation artifact emanating from the sinus confluence is seen across the occipital lobes (*small arrows*).

defined as a "small proteinaceous infectious" particle that resists inactivation by procedures that modify nucleic acids (14). Prions are different from viruses in that they contain little or no nucleic acid and do not evoke an immune response during infection (14).

The exact mechanism by which human prion diseases cause CNS degeneration is unknown. A few cases of CrJaD have been traced to inoculation with prions secondary to injection of human growth hormone, transplantation of corneas, and implantation of cerebral electrodes (14). Ten to 15% of cases are familial (15), suggesting the possibility that a genetic locus renders patients susceptible to infection by exogenous prions (14). However, the vast majority of cases of CrJaD are

sporadic (14), and no endemic areas are known. Some suggest that meat handlers, butchers, and patients who have undergone prior neurosurgical procedures are at risk for developing CrJaD (15). No risk factor could be identified in the two cases presented here.

Patients most commonly present between the ages of 40–80 years. The clinical presentation is diverse and often difficult to distinguish from other dementias. Classically, the patient exhibits a rapidly progressive dementia associated with upper motor neuron dysfunction and myoclonic seizures. Electroencephalographic changes are characterized by diffuse slowing with superimposed bursts of sharp waves. CSF analysis is usually normal but may show slight elevation of

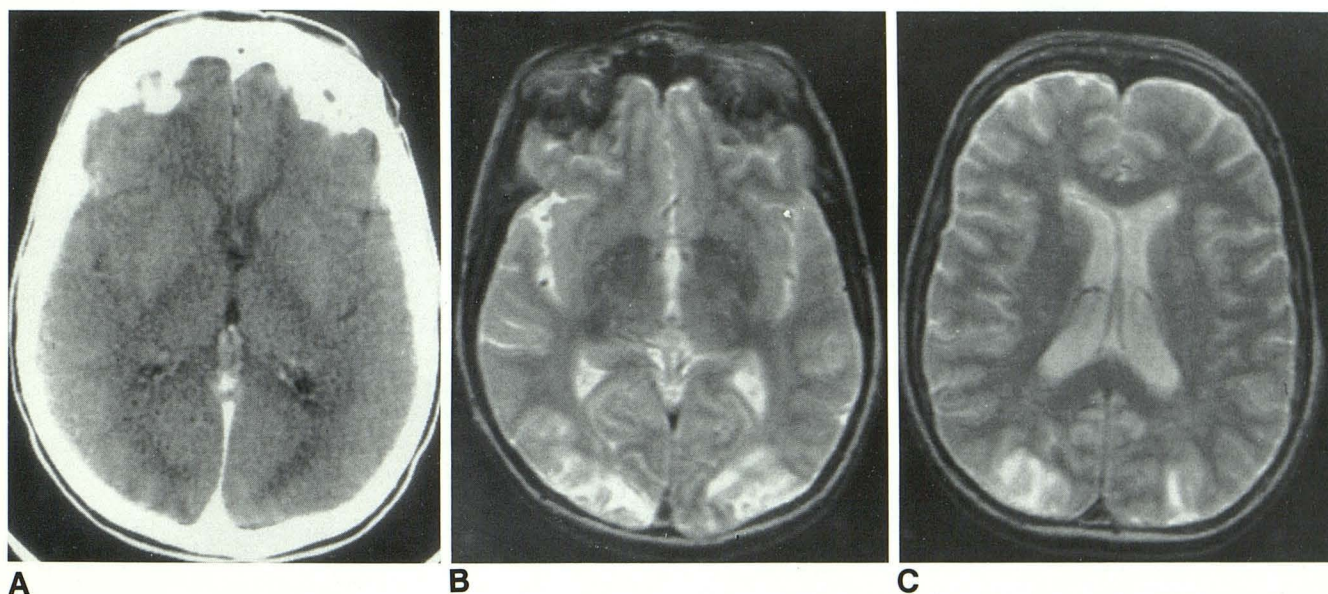


Fig. 2. Case 2: CT and MR obtained within a 2-day period.

A, Contrast-enhanced CT of brain. Axial section at level of atria of lateral ventricles. Nonenhancing symmetric low-density changes of both gray and white matter of both occipital lobes. Note lack of atrophic change.

B, T2-weighted axial image (2400/80/1) at similar level as in A. Symmetric high signal intensity change in both occipital lobes in a distribution as depicted by CT.

C, T2-weighted axial image (2400/80/1) at level of body of lateral ventricles. Note predominant gray matter involvement with lesser involvement of left occipital white matter.

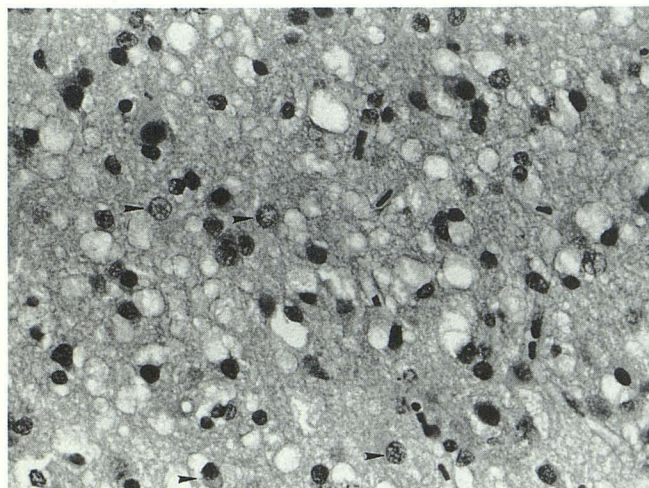


Fig. 3. Case 2: Brain biopsy specimen. The cerebral cortex shows neuronal loss, gliosis and prominent microvacuolization of the neuropil, creating a spongiform appearance. Reactive astrocytes are depicted by arrowheads. No intranuclear inclusion or inflammation is present (hematoxylin and eosin stain, $\times 400$).

protein content (15), as was present in both our patients.

CT scanning has been used to exclude focal lesions as a cause of the patients' symptoms (6). Of 33 patients with CrJaD and CT scans reported in the literature, no patient manifested a focal parenchymal abnormality (1-13). CT scanning

demonstrated focal abnormalities in one of our patients (Fig. 2A). In the largest single series of 15 patients (8), 80% of patients had normal CT scans while the remaining 20% exhibited atrophy. Some patients who initially have a normal CT scan may reveal atrophy on follow-up examinations (6, 9, 10). Nonprogressive and progressive atrophic changes are also seen commonly (2, 4, 6, 7, 11, 12). Atrophy can be so severe and so rapidly progressive that it can result in the formation of subdural hygromas (2).

MR findings have been reported in eight patients with previously documented CrJaD (1-3, 6, 12, 13). Four of the patients demonstrated atrophy only. In four of eight patients, long repetition time (T2-weighted) images displayed symmetrical abnormal high intensities in the caudate nuclei (12), striatum, thalamus, and cortex (location not specified) (3), basal ganglia (13), and periventricular white matter (1).

As might be expected from the varied clinical presentations of CrJaD, the gross and histologic changes reveal considerable topographic variation (15). Atrophy may occur diffusely or may be predominantly confined to the cortical ribbon, cerebellum, thalamus, basal ganglia, or specific tracts (15). Based on these varied clinical and pathologic presentations, CrJaD has been divided

into several variants. One of these, Heidenhain variant, is characterized by occipital lobe degeneration and visual impairment (16). Our two cases may represent examples of this variant.

Microscopically, the gray matter is most affected (14), with perhaps some preferential involvement of the frontal and temporal lobes (15). Changes reported include marked neuronal loss with reactive astrogliosis, replacement gliosis, and neuronal vacuolation with "spongiform" changes (14, 15). Such spongiform changes, as demonstrated in our cases, are accepted by many as the sine qua non of CrJaD.

Cortical gray matter involvement without cerebral atrophy may represent an early phase of the disease. If that were the case, atrophy and white matter changes secondary to neuronal loss would then become evident later. In view of the histopathologic findings, the high signal intensity changes in the cortical gray matter more likely reflect areas of gliosis and microvacuolization rather than areas of edema and inflammatory cell infiltration (15). The lack of enhancement implies an intact blood-brain barrier.

Several observations may be drawn from these two biopsy-proved cases of CrJaD, and those collected from the literature. First, MR is more sensitive than CT in detecting the pathologic changes of CrJaD. Second, when signal abnormalities are found, they are predominantly within gray matter. As in our cases, these may involve only peripheral cortex. Third, in the proper clinical setting, absence of subcortical periventricular white matter hyperintensities and absence of postcontrast MR enhancement, suggest that symmetric hyperintense cortical lesions (with or without basal ganglia involvement) are more likely to represent a degenerative or slowly progressive viral inflammatory process, rather than ischemia or bacterial infection.

References

1. Kruger H, Meesmann C, Rohrbach E, Muller J, Mertens HG. Panencephalopathic type of Creutzfeldt-Jakob disease with primary extensive involvement of white matter. *Eur Neurol* 1990;30:115-119
2. Schlenska GH, Walter GF. Serial computed tomography findings in Creutzfeldt-Jakob disease. *Neuroradiology* 1989;31:303-306
3. Gertz HJ, Henkes H, Cervos-Navarro J. Creutzfeldt-Jakob disease: correlation of MRI and neuropathologic findings. *Neurology* 1988;38:1481-1482
4. Chan YW, Ho HC, Kay CS, Li SW, Ip YM. Creutzfeldt-Jakob disease in Hong Kong: a case report. *J Neurol Sci* 1987;80:143-152
5. Jones HR Jr, Hedley-Whyte ET, Freidberg SR, Baker RA. Ataxic Creutzfeldt-Jakob disease: diagnostic techniques and neuropathologic observations in early disease. *Neurology* 1985;35:254-257
6. Kovanen J, Erkinjuntti T, Iivanainen M, et al. Cerebral MR and CT imaging in Creutzfeldt-Jakob disease. *J Comput Assist Tomogr* 1985;9:125-128
7. Westphal KP, Schachenmayr W. Computed tomography during Creutzfeldt-Jakob disease. *Neuroradiology* 1985;27:362-364
8. Galvez S, Cartier L. Computed tomography findings in 15 cases of Creutzfeldt-Jakob disease with histological verification. *J Neurol Neurosurg Psychiatry* 1984;47:1244-1246
9. Kitagawa Y, Gotoh F, Koto A, et al. Creutzfeldt-Jakob disease: a case with extensive white matter degeneration and optic atrophy. *J Neurol* 1983;229:97-101
10. Packer RJ, Cornblath DR, Gonatas NK, Bruno LA, Asbury AK. Creutzfeldt-Jakob disease in a 20 year old woman. *Neurology* 1980;30:492-496
11. Rao CV, Brennan TG, Garcia JH. Computed tomography in the diagnosis of Creutzfeldt-Jakob disease. *J Comput Assist Tomogr* 1977;1(2):211-215
12. Pearl GS, Anderson RE. Creutzfeldt-Jakob disease: high caudate signal on magnetic resonance imaging. *Southern Med J* 1989;82:1187-1180
13. Milton WJ, Atlas SW, Lavi E, Mollman JE. Magnetic resonance imaging of Creutzfeldt-Jakob disease. *Ann Neurol* 1991;29:438-440
14. Prusiner SB. Prions and neurodegenerative diseases. *N Engl J Med* 1987;317:1571-1581
15. Leestma JE. Viral infections of the nervous system: In: Davis RL, Robertson DM, eds. *Textbook of neuropathology*. Baltimore: Williams & Wilkins, 1985:771-775
16. Meyer A, Leigh D, Bagg CE. A rare presenile dementia associated with cortical blindness (Heidenhain's syndrome). *J Neurol Neurosurg Psychiatry* 1954;17:129