



## Discover Generics

Cost-Effective CT & MRI Contrast Agents



FRESENIUS  
KABI

WATCH VIDEO

# AJNR

## **MR imaging of cerebrospinal fluid rhinorrhea after operation for acoustic neurinoma.**

H Takeuchi, T Kubota, M Kabuto, M Hayashi, Y Ishii and Y Kawamura

*AJNR Am J Neuroradiol* 1992, 13 (1) 379-381

<http://www.ajnr.org/content/13/1/379>

This information is current as  
of June 22, 2025.

## MR Imaging of Cerebrospinal Fluid Rhinorrhea after Operation for Acoustic Neurinoma

Hiroaki Takeuchi,<sup>1</sup> Toshihiko Kubota,<sup>1</sup> Masanori Kabuto,<sup>1</sup> and Minoru Hayashi,<sup>1</sup> Yasushi Ishii,<sup>2</sup> and Yasutaka Kawamura<sup>2</sup>

**Summary:** MR was useful in verifying CSF rhinorrhea following removal of an intracanalicular acoustic neurinoma via the occipital route in a 29-year-old man. MR accurately identified the location of the CSF leak.

**Index terms:** Cerebrospinal fluid, leakage; Neuroma; Temporal bone, magnetic resonance; Magnetic resonance, postoperative

Cerebrospinal fluid (CSF) otorhinorrhea is the most common postoperative complication following the various approaches to the cerebellopontine angle and internal auditory meatus to remove acoustic neurinomas. We report a case in which MR images verify CSF rhinorrhea following removal of an intracanalicular acoustic neurinoma via the suboccipital route. MR images may be useful for determining CSF otorhinorrhea. However, to our knowledge, there are no reports of the MR appearance of CSF otorhinorrhea. MR images proved effective in accurately demonstrating the location of the CSF leak.

### Case Report

A 29-year-old man presented with sudden onset of left sided tinnitus and hearing disturbance. Physical examination was unremarkable, apart from showing a mild degree of sensorineural hearing loss on the left side. MR was performed with a 1.5-T Signa imaging system (General Electric Medical Systems, Milwaukee, WI). T1-weighted MR images revealed a homogeneously enhancing mass with gadolinium-DTPA in the left internal auditory meatus (Fig. 1A) which was diagnosed as an intracanalicular acoustic neurinoma. A left suboccipital craniectomy was performed to remove the tumor. The posterior wall of the internal auditory meatus was removed with a diamond burr and the intracanalicular tumor was exposed. The tumor was removed with a curette piece by piece. When the patient began to walk on the sixth postoperative day, he noticed an intermittent watery discharge into the pharynx.

A conductive hearing loss developed. Glucose determination by Dextrostix showed a positive result on the fluid that was obtained from the left ear by myringotomy. There were no findings of inflammation (meningitis, mastoiditis, etc) on physical and laboratory examination. It was thought that CSF was coming from the left eustachian tube. During the subsequent 8 days, CSF leakage was intermittently present in spite of the patient's confinement to bed. On the 14th postoperative day, a lumbar spinal catheter was inserted to continuously drain CSF. Thereafter, CSF leakage ceased for 2 weeks during the CSF drainage. However, on the 28th day after the operation, 3 hr after removing the spinal catheter, CSF leakage developed again. This time MR images were obtained. On the T2-weighted images, high signal intensities were visualized in the left posterior wall of the internal auditory meatus, air cells in the mastoid bone, middle ear cavity and the eustachian tube (Figs. 1B, 1C). T1-weighted images showed low signal intensities equal to CSF in these regions. On the next day, the left internal meatus was explored by the original approach. As the MR images had shown, small pores were present in the posterior wall of the internal auditory meatus. The bone defects were packed with muscle fragments and coated with fibrin glue. The patient had no further leakage of CSF. Six weeks after the second operation, the T2-weighted MR image showed no high signal intensity lesions in the regions where the CSF leak had been noted previously. (Fig. 1D).

### Discussion

Montgomery (1) reported an 18% incidence of CSF otorhinorrhea following the suboccipital approach to the cerebellopontine angle and the internal auditory meatus. Gordon et al (2) reported that CSF rhinorrhea developed in two (4%) of a series of 48 patients with acoustic neurinoma removed by the suboccipital route. The incidence of this complication has been reported to range from 4% to 18% (3).

Received April 3, 1991; revision requested May 31; revision received June 28; final acceptance August 2.

<sup>1</sup> All authors: Department of Neurosurgery, Fukui Medical School, Matsuoka-chou, Yoshida-gun, Fukui 910-11, Japan. Address reprint requests to H. Takeuchi.

<sup>2</sup> Department of Radiology, Fukui Medical School, Japan.



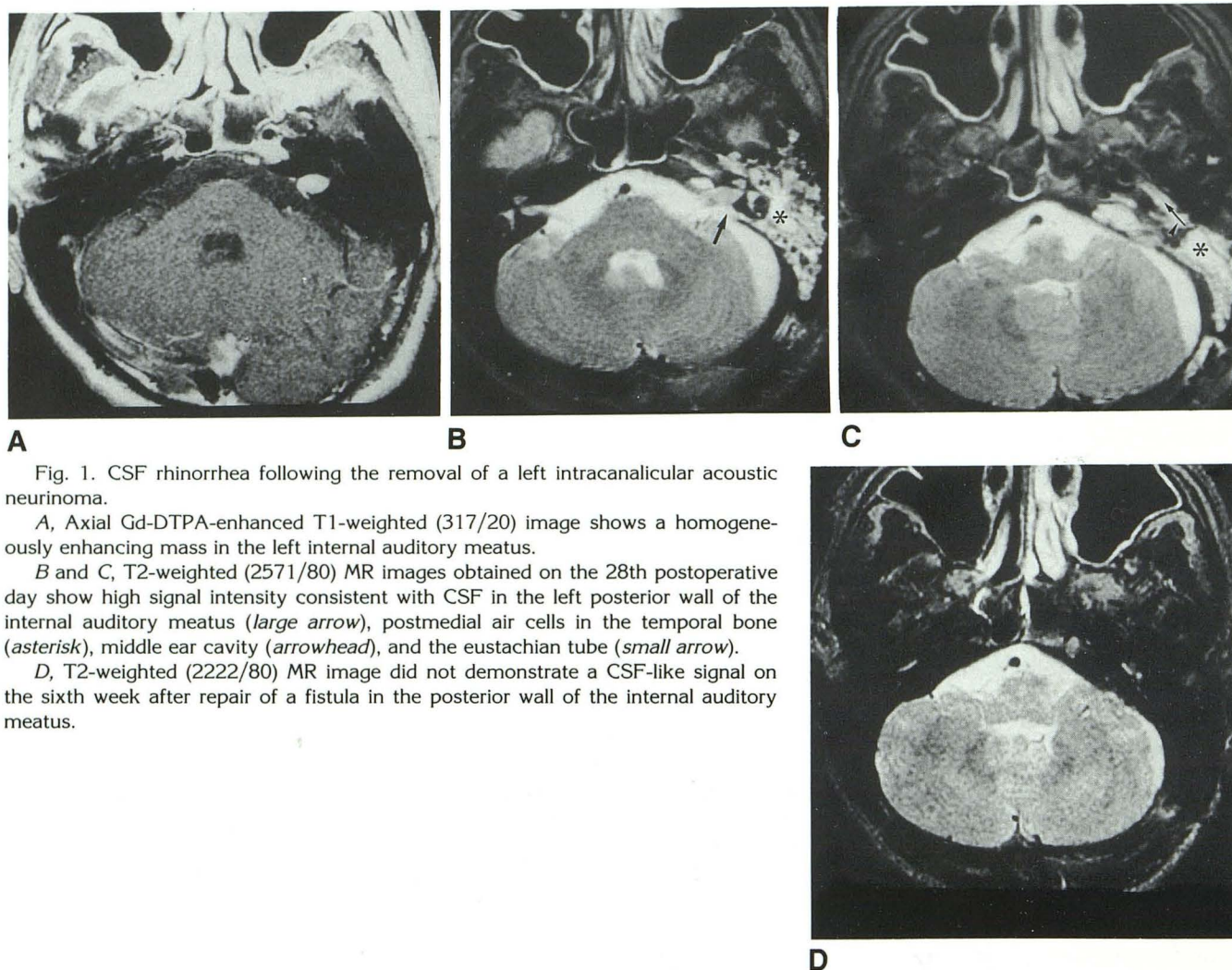


Fig. 1. CSF rhinorrhea following the removal of a left intracanalicular acoustic neurinoma.

A, Axial Gd-DTPA-enhanced T1-weighted (317/20) image shows a homogeneously enhancing mass in the left internal auditory meatus.

B and C, T2-weighted (2571/80) MR images obtained on the 28th postoperative day show high signal intensity consistent with CSF in the left posterior wall of the internal auditory meatus (*large arrow*), postmedial air cells in the temporal bone (*asterisk*), middle ear cavity (*arrowhead*), and the eustachian tube (*small arrow*).

D, T2-weighted (2222/80) MR image did not demonstrate a CSF-like signal on the sixth week after repair of a fistula in the posterior wall of the internal auditory meatus.

It is considered that there are two major sites of CSF leakage following the operation. One is the posteromedial air cell tract, which is described in this case. Allam (4) in a detailed investigation of the pneumatization of over 400 temporal bones, described the posteromedial air cell tract extending posterior to the bony labyrinth and into the posterior wall of the internal auditory meatus. Lang et al (5) reported a pneumatized posteromedial air cell tract in 13 (22%) of 60 temporal bones that were examined. Rhoton (6) appreciated the potential surgical hazard of these cells. Another site of CSF leakage is the mastoid air cells lateral to the sigmoid sinus that may be opened at the time of suboccipital craniectomy. Robson et al (7) suggested that drilling of the petrous bone will often open up mastoid air cells that communicate with the middle ear cavity. In removing acoustic neurinomas, rhinorrhea may take place across the posteromedial air cell tract into the mastoid air cells, thus forming a fistulous

tract into the middle ear cavity that then communicates through the eustachian tube to the nasal cavity.

Accurate localization and verification of the sites of leakage are of great importance in repairing the fistula and preventing meningitis. Failure to accurately localize the origin of the leak may require a more extensive exploratory surgical procedure.

In general, it is not always possible to identify the path of a CSF fistula because there are many possible anatomical passages at the base of the skull. There are many methods for detecting and localizing a fistula. Neuroradiologic procedures to identify the fistula include skull roentgenography and tomography, pneumoencephalography, x-ray computed tomography (CT), positive contrast CT cisternography, and radionuclide ventriculography, cisternography, and positron emission tomography. Radionuclide cisternography is useful when the fistula is leaking (8), but fails in



the non-drop period. This method, in combination with the use of nasal pledgets and maneuvers to increase intracranial pressure (eg, head positioning, straining, and intrathecal injection of saline), may permit verification of a CSF fistula and in its localization. However, the low resolution character of radioisotopic studies often limits the ability to precisely define the site of leakage, so that false-negative results are often obtained and exact anatomical localization is difficult with this method.

Metrizamide CT cisternography has been successful in the investigation of intermittent CSF liquorrhea (9, 10). This is reported to be an especially valid method in the dry non-leak period (9). There is no need for special maneuvers such as raising the intracranial pressure or complementing the examination with isotope cisternography. Metrizamide CT cisternography has been used to detect the exact anatomic site of fistulas (10). However, the leakage site often cannot be seen clearly with these methods because of the complexity of the temporal bone. In addition, the positive contrast achieved with metrizamide is obscured by the surrounding bone.

It is important to distinguish the increased T2-weighted signal in the temporal bone from mastoiditis. On the T1-weighted images, proteinaceous fluid shows higher signal intensity than simple fluid (11). Therefore, CSF may be distinguished from the proteinaceous fluid secondary to inflammatory reaction. While MR imaging may show increased T2W signal intensity in mastoiditis similar to paranasal sinusitis (12, 13), to our knowledge there are no MR reports of postoperative mastoiditis after the removal of neurinoma via the suboccipital route. In our case, postoperative T1 and T2-weighted signal in the temporal bone showed not proteinaceous fluid but simple fluid. Martin et al reported the high sensitivity of MR imaging performed after administration of Gd-DTPA for detection of subtle areas of otitic inflammation (14). In our case, Gd-DTPA-enhanced MR images showed no enhancement in the temporal bone.

MR imaging is a noninvasive and simple way of directly verifying the exact site of leakage and the fistulous tract. Verification of CSF rhinorrhea

is easier during leakage than when there is no leakage. In this case, MR imaging was performed in the leaking period. However, it is thought to be capable of detecting the site of leakage in the non-leak period also.

If MR images are considered to provide the most precise localization of a fistula, they may be helpful for determining the most suitable surgical procedures. However, to our knowledge, there are no other reports of the MR diagnosis of CSF otorhinorrhea. In cases of suspected CSF leakage, MR images are our first choice in verifying the exact site of the fistula and tract. T2-weighted images are especially demonstrative of CSF leak.

## References

1. Montgomery WW. Common complications following removal of vestibular schwannoma. *Adv Otorhinolaryngol* 1983;31:228-239
2. Gordon DS, Kerr AG. Cerebrospinal fluid rhinorrhea following surgery for acoustic neurinoma: report of two cases. *J Neurosurg* 1986;64:676-678
3. Ojemann RG, Martuza RL. Acoustic neurinoma. In: Youmans JR, ed. *Neurological surgery*. Philadelphia: Saunders, 1990:3316-3350
4. Allam AF. Pneumatization of the temporal bone. *Ann Otol* 1969;78:49-64
5. Lang J, Kerr AG. Pneumatization of the posteromedial air-cell tract. *Clin Otolaryngol* 1989;14:425-427
6. Rhoton AL Jr. Microsurgery of the internal acoustic meatus. *Surg Neurol* 1974;2:311-318
7. Robson AK, Clarke PM, Dilkes M, Maw AR. Transmastoid extracranial repair of CSF leaks following acoustic neurinoma resection. *J Laryngol Otol* 1989;103:842-844
8. Di Chiro G, Ommaya AK, Ashburn WL, Briner WH. Isotope cisternography in the diagnosis and follow up of cerebrospinal fluid rhinorrhea. *J Neurosurg* 1968;28:522-529
9. Fagerlund M, Liliequist B. Intermittent cerebrospinal liquorrhea: cerebral computed tomography in the non-drop period. *Acta Radiol* 1987;28:189-192
10. Drayer BP, Wilkins RH, Boehnke M, Horton JA. Cerebrospinal fluid rhinorrhea demonstrated by metrizamide CT cisternography. *Am J Roentgenol* 1977;129:149-151
11. Mitchell DG, Burk DL Jr, Vinitski S, Rifkin MD. The biophysical basis of tissue contrast in extracranial MR imaging. *Am J Roentgenol* 1987;149:831-837
12. Rak KM, Newell JD, Yakes WF, Damiano MA, Luethke JM. Paranasal sinuses on MR images of the brain: significance of mucosal thickening. *Am J Roentgenol* 1991;156:381-384
13. Som PM, Shapiro MD, Biller HF, Sasaki C, Lawson W. Sinonasal tumors and inflammatory tissues: differentiation with MR imaging. *Radiology* 1988;167:803-808
14. Martin N, Sterkers O, Nahum H. Chronic inflammatory disease of the middle ear cavities: Gd-DTPA enhanced MR imaging. *Radiology* 1990;176:399-405