



## Discover Generics

Cost-Effective CT & MRI Contrast Agents



WATCH VIDEO

# AJNR

### **A palatal dentigerous cyst arising from a mesiodente.**

P M Som, L M Shangold and H F Biller

*AJNR Am J Neuroradiol* 1992, 13 (1) 212-214

<http://www.ajnr.org/content/13/1/212>

This information is current as  
of June 3, 2025.

## A Palatal Dentigerous Cyst Arising from a Mesiodente

Peter M. Som,<sup>1,2</sup> Lee M. Shangold,<sup>2</sup> and Hugh F. Biller<sup>2</sup>

**Summary:** Dentigerous cysts can develop from unerupted primary, permanent, or rarely supernumerary teeth. When a supernumerary tooth is in the maxilla, near the midline, it is called a mesiodente. Such a mesiodente lies in the palate and a cyst developing about this tooth can extend directly up into the nasal fossae. More commonly a dentigerous cyst arising from unerupted maxillary teeth occurs about the molar, premolar, or canine teeth and the cyst extends up into the maxillary sinus. The CT and MR findings in a rare case of a dentigerous cyst of a mesiodente are presented.

**Index terms:** Palate, cysts; Nasal fossae, cysts; Teeth, abnormalities and anomalies

The overall incidence of supernumerary teeth is about one in 100 people and the ratio of their occurrence in the maxilla to that in mandible is about 8:1. Since approximately 80% of supernumerary teeth remain unerupted, the majority of them can only be demonstrated by an imaging study. Mesiodentes are supernumerary teeth that occur near the midline of the maxilla, almost always posterior to the normal central incisors. As a result, most of the permanent incisors are permitted to erupt into their normal position in the maxillary arch. A mesiodente can be either solitary or bilateral and the most common complications caused by them is malpositioning or noneruption of the normal teeth. As with other teeth that remain unerupted, there is the possibility for cyst formation. The purpose of this paper is to present a patient who had a mass in the floor of the nasal fossae that was a dentigerous cyst of a mesiodente. This rare case is documented with computed tomography (CT) and magnetic resonance (MR) imaging.

### Case Report

The patient was a 39-year-old woman who presented with a 3-month history of progressive left nasal obstruction. There was no complaint of epistaxis, rhinorrhea, or headache and she had no significant past medical history. Physical examination revealed a submucosal nontender mass in the left floor of the nose and hard palate. A CT scan (Figs. 1A-1D) showed an expansile cystic mass in the left nasal floor and hard palate. The lesion had remodeled the medial wall of the left antrum and had displaced the nasal septum to the right. Along the inferior, anterior margin of the cyst was a conical density that looked like a near normal tooth. All of the maxillary, permanent teeth were identified in normal position. An MR scan showed the cystic mass to have an intermediate T1-weighted (600/15/2) and a high T2-weighted (2800/80/2) signal intensity (Figs. 1D and 1E). The tooth-like structure seen on CT had a low signal intensity on all MR sequences. The patient had the cyst excised via a Denker's modification of a left caldwell-luc procedure. Pathology was that of a dentigerous cyst. The associated tooth was a conical, slightly deformed supernumerary tooth.

### Discussion

Supernumerary teeth are extra or accessory teeth that are believed to result from the duplication of either the primary or permanent dentition (1). A mesiodente is a supernumerary tooth that occurs in the maxilla, usually posterior to the normal central incisors. As a result, it may be situated just beneath the floor of the nasal fossae, in the hard palate (1).

Supernumerary teeth can resemble normal teeth, have conical crowns, or bear little resemblance to a normal tooth. Most mesiodentes are conical, as in our case.

The most common odontogenic cyst is the follicular cyst that represents nearly 34% of all

Received April 24, 1991; final acceptance August 12 (no revision necessary).

<sup>1</sup> Department of Radiology of the Mount Sinai Medical Center, City University of New York, Box 1234, One Gustave L. Levy Place, New York, NY 10029-6574. Address reprint requests to P. Som.

<sup>2</sup> Department of Otolaryngology of the Mount Sinai Medical Center, City University of New York, New York, NY 10029-6574.

AJNR 13:212-214, Jan/Feb 1992 0195-6108/92/1301-0212 © American Society of Neuroradiology



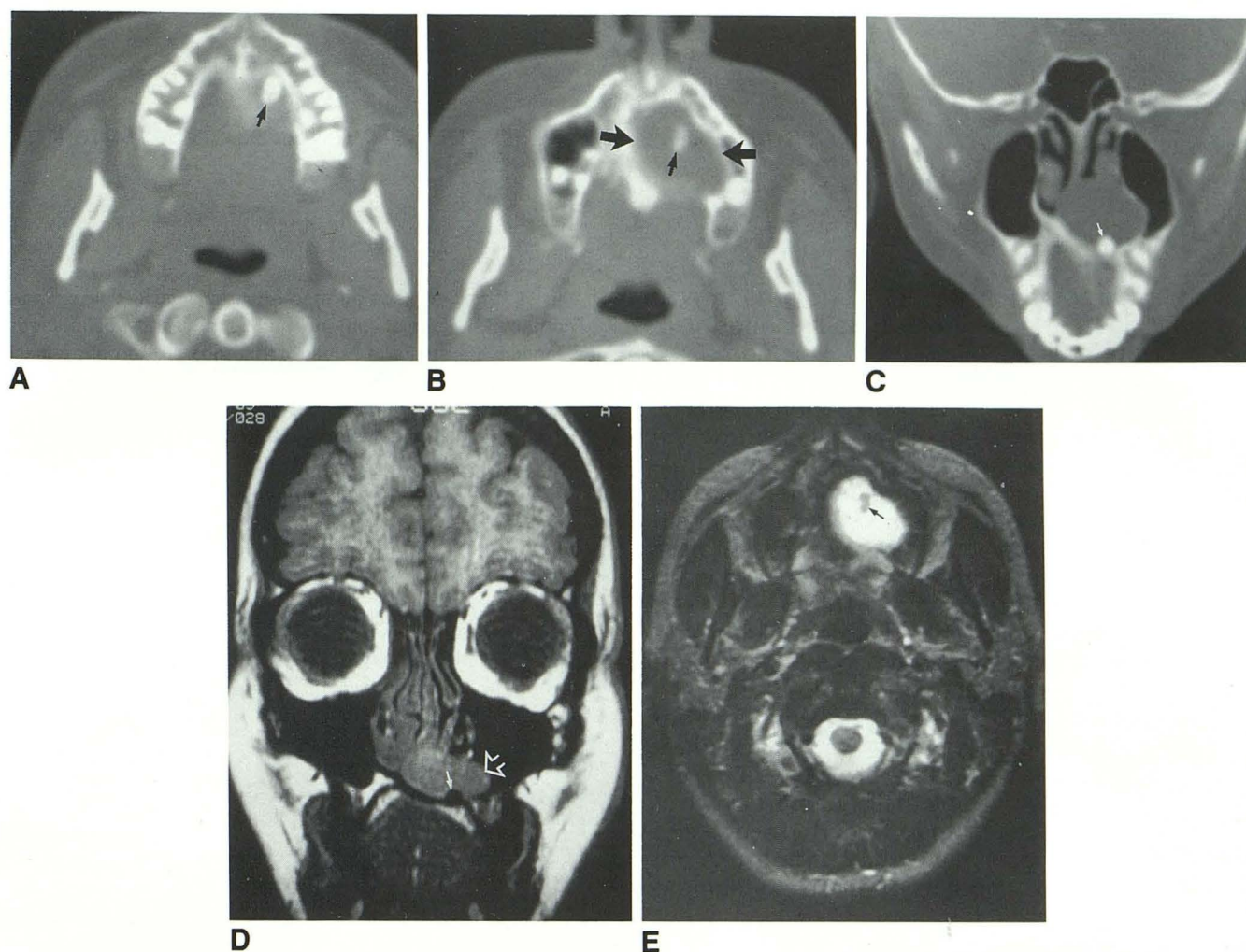


Fig. A–C, CT scans: Axial wide window setting CT scans show (A) a conical, supernumerary tooth in the left hard palate (arrow) positioned just behind the maxillary alveolus more cranial scan (B) shows the cystic erosion in the hard palate (big arrows) and the top of the tooth (small arrow). Coronal scan (C) shows the expansile, cystic palatal, and nasal floor mass, and the supernumerary tooth (arrow). Also shown are all of the anterior maxillary teeth in normal position.

D and E, MR scans: Coronal (D) T1-weighted (600/15/2) MR scan shows an expansile low signal intensity mass in the palate and floor of the nasal fossae (open arrow). There is a localized area of signal void (tooth) (arrow) in the lower margin of the mass. Axial (E) T2-weighted (2800/80/2) MR scan shows the mass to have a high signal intensity. The tooth (arrow) is seen as an area of lower signal

odontogenic cysts. The follicular cysts are subclassified into dentigerous cysts (95%) and primordial cysts (5%) (2). The dentigerous cysts are epithelial lined sacs that develop from the enamel organ in association with the crown of an unerupted tooth. They most often involve, in descending order of frequency, the third molar, the canine, and the second premolar teeth. These cysts rarely have been reported to occur in supernumerary teeth. One report in the literature and references to two more cases in Stafne's

textbook of such a dentigerous cyst occurring in a mesiodente was all we could find in a search of the literature (3, 4).

On CT, the cysts are usually unilocular, clearly margined, and the displaced tooth is at the margin of the lesion. On MR, the tooth has low signal intensity or signal void on all sequences. The cyst fluid gives low-to-intermediate T1-weighted and high T2-weighted signal intensity depending upon the protein content within the cyst fluid. Once a tooth is identified within such

a cyst, the diagnosis of a dentigerous cyst is virtually assured. A variety of cysts including palatal fissural cysts, odontogenic keratocysts, primordial cysts and periodontal cysts can occur in the palatal region, however, none of them contain a tooth within the cyst. Rudimentary teeth or denticles can be found in odontomas; however, these lesions are radiodense and are not radiographically confused with dentigerous cysts.

## References

1. Stafne EC, Gibilisco JA. In: *Oral roentgenographic diagnosis*. 4th ed. Stafne EC, Gibilisco JA, eds. Philadelphia: WB Saunders, 1975:18-20
2. Verbin RS, Barnes L. Cyst and cyst-like lesions of the oral cavity, jaws, and neck. In: *Surgical pathology of the head and neck*. Vol 2, Barnes L, ed. New York: Marcel Dekker, 1985:1233-1329
3. Papadopoulos MS. An unusual case of a dentigerous cyst due to a mesiodens. *Br J Oral Surg* 1981;19:307-308
4. Stafne EC. Supernumerary upper central incisors. *Dent Cosmos* 1931;73:976-980