



Discover Generics

Cost-Effective CT & MRI Contrast Agents



WATCH VIDEO

AJNR

Cystic temporofacial rhabdomyosarcoma with subarachnoid communication.

W L Hirsch, Jr, H D Curtin, I Janecka and L Barnes

AJNR Am J Neuroradiol 1992, 13 (1) 205-208

<http://www.ajnr.org/content/13/1/205.citation>

This information is current as
of June 19, 2025.

Cystic Temporofacial Rhabdomyosarcoma with Subarachnoid Communication

William L. Hirsch, Jr.,¹ Hugh D. Curtin,¹ Ivo Janecka,² and Leon Barnes,³

Summary: The authors present an unusual case of cystic temporofacial rhabdomyosarcoma with subarachnoid communication in a 10-year-old boy, and discuss the differential diagnosis, possible etiology, and other types of rhabdomyosarcoma.

Index terms: Face, neoplasms; Myosarcoma; Subarachnoid space, neoplasms

Rhabdomyosarcoma (RMS) is the most common soft-tissue sarcoma of childhood. The neoplasm probably originates from pluripotential mesenchyme, and may occur anywhere in the body. Thirty to 40% arise in the head and neck. Imaging studies typically show a homogeneous soft-tissue mass, often with poorly defined margins and permeative bone destruction (1–5).

We report an unusual case of embryonal RMS of the facial soft tissues. The tumor consisted of a cavity with multiple extensions that communicated with the subarachnoid space.

Case Report

A 10-year-old boy was examined by his dentist for acute nonpainful swelling of the right cheek. Attributing the swelling to dental infection, several primary teeth were extracted, and the patient was placed on amoxicillin and Augmentin. The swelling persisted, and 2 weeks later, he was seen by an otolaryngologist. Physical exam revealed a cheek mass bulging into the oral cavity. The mass was felt to be a salivary duct cyst, and a drain was inserted into the cyst from the oral cavity. Copious amounts of clear fluid was observed to escape along the drain. The same day the patient began complaining of headache. He developed fever to 103°F and meningismus; both were treated with antibiotics. The drain was removed after 1 week of continued drainage. Imaging studies were obtained. Neurologic examination, including cranial nerve function, was normal except for diminished sensation in the distribution of all three divisions of the right trigeminal nerve.

Computed tomography (CT) showed a well-defined, lobulated low-density mass involving the right cheek, prestyloid and poststyloid parapharyngeal space, the masticator space, and the temporalis fossa (Figs. 1A and 1B). There were sharply margined bone defects in the anterior wall and the floor of the middle cranial fossa, including the foramen ovale. A CT cisternogram was performed and all of the low-density lobules of the mass were opacified along with the subarachnoid space (Fig. 1C). Magnetic resonance (MR) imaging showed similar findings; the contents of the loculations had signal characteristics of cerebrospinal fluid (CSF). There were two areas of higher CT attenuation within the lesion. One was near the lateral aspect of the pterygopalatine fossa, and the other just beneath the foramen ovale in the upper masticator space. These areas enhanced on both CT and MR scans following contrast administration (Figs. 1D and 1E). Selective external carotid angiography showed a faint blush near the right pterygopalatine fossa but revealed an otherwise avascular mass. Small branches of the external carotid artery were stretched around the mass. A parotid sialogram showed normal ducts displaced by the adjacent mass. Our preoperative diagnosis was multiloculated encephalocele. The enhancing areas were difficult to explain but were attributed to brain tissue within a encephalocele or an inflammatory reaction to the transoral drain.

At surgery, the walls of the cystic cavities were extremely thin and appeared absent in several areas. The soft-tissue components corresponding to the solid areas on CT and MR had the appearance of brain. Intraoperatively, the clinical impression was one of a multiloculated meningoencephalocele. After resection, the defects in the floor of the middle cranial fossa and sphenoid sinus caused by the mass were filled with a temporalis muscle flap.

Histologic examination of the cyst wall revealed an embryonal RMS. Immunoperoxidase stains of the neoplastic cells were positive for desmin and myoglobin, indicating a muscle origin.

Postoperatively, the patient received systemic chemotherapy (Ara-C, vincristine, ifosfamide, Actinomycin D, and steroids) and cranial irradiation (308 Gy whole brain and a

Received February 15, 1991; revision requested April 19; revision received June 6; final acceptance July 8.

¹ Department of Radiology, Presbyterian University Hospital, University of Pittsburgh School of Medicine, DeSoto & O'Hara Streets, Pittsburgh, Pa 15213. Address reprint requests to W. L. Hirsch, Jr.

² Department of Otolaryngology, Eye & Ear Institute, University of Pittsburgh School of Medicine, Pittsburgh, Pa 15213.

³ Department of Pathology, Presbyterian University Hospital, University of Pittsburgh School of Medicine, Pittsburgh, Pa 15213.

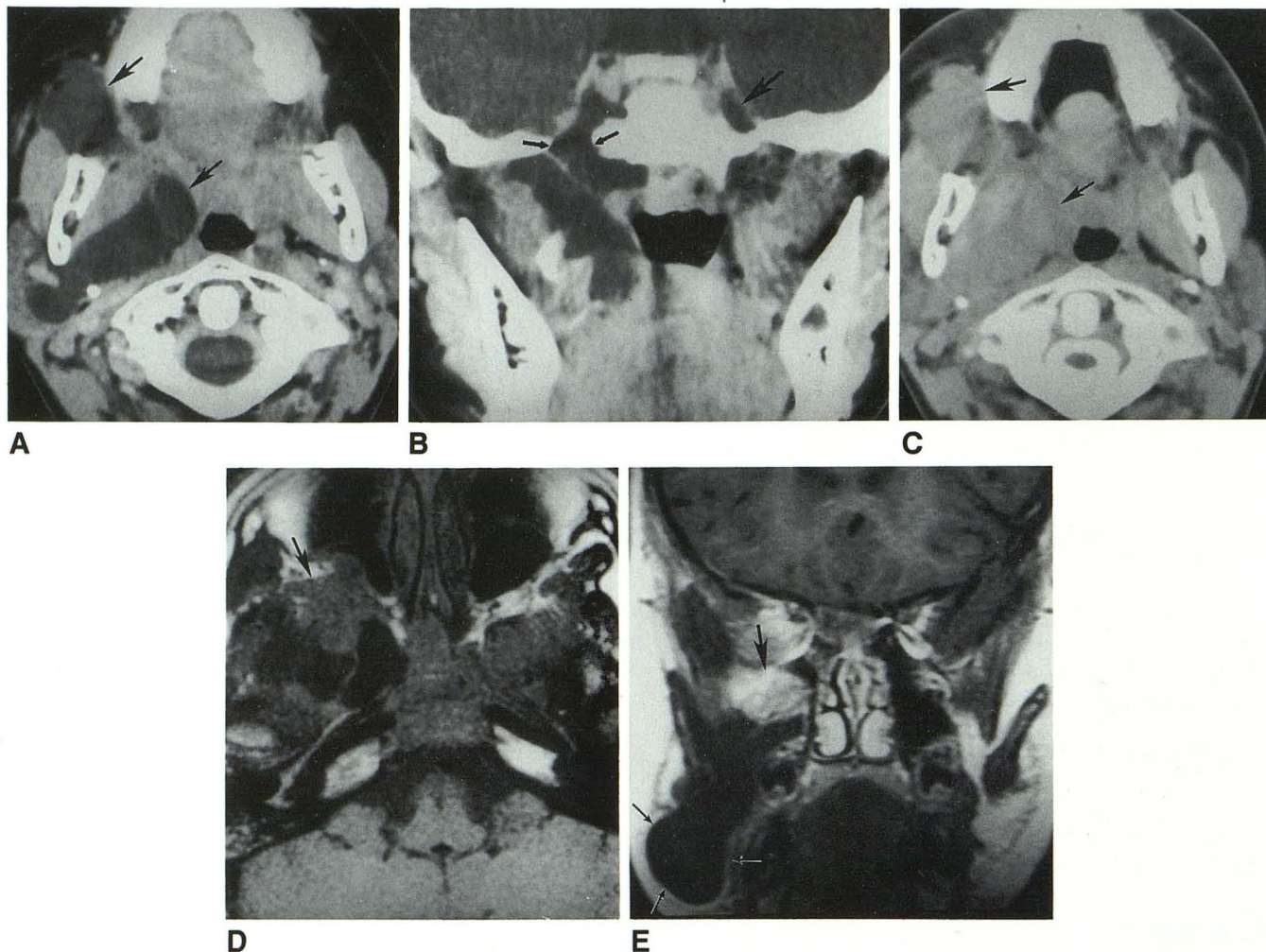


Fig. 1. A, Axial CT following intravenous contrast shows a lobulated CSF density mass involving the right prestyloid and poststyloid parapharyngeal space, the masticator space, and the temporalis fossa (arrows).

B, Coronal enhanced CT shows that the mass has an intracranial component. The right Meckel's cave is expanded and has an irregular contour. Compare with the normal cave on the left (large arrow). The intracranial and infratemporal components of the mass appear to communicate. There is a smoothly margined defect in the floor of the middle cranial fossa where foramen ovale should be (small arrows).

C, Axial CT immediately following intrathecal contrast shows opacification of the cysts (arrows), confirming that the cysts communicate with the subarachnoid space (compare with A).

D, Axial MR, 600/20/2 (TR/TE/excitations), shows the soft-tissue component of the mass replacing the normal fat in the right inferior orbital fissure and pterygopalatine fossa (arrow).

E, Coronal MR (450/20) after intravenous gadolinium shows enhancement of the soft-tissue component (arrow). The walls of the cysts (small arrows) did not enhance.

total dose of 594 Gy to the base of skull and right cheek). Because of the parameningeal location of the neoplasm, he also received intrathecal methotrexate.

The patient tolerated radiation and chemotherapy well. After 4 months, he developed a foot drop that improved when vincristine was temporarily held. Fourteen months after surgery, while still on chemotherapy, the patient was admitted for headache, progressive difficulty with gait, and recent onset of difficulty initiating urination. Physical exam revealed a Brown-Sequard syndrome referable to the L5 level. MR showed enhancing nodules throughout the intracranial and spinal CSF spaces. The patient was treated with an additional 30 Gy to the head and 160 Gy to the spine. The patient began having seizures and, over the next

2 months, developed multiple cranial nerve palsies presumably related to diffuse subarachnoid metastases. He also developed massive hydrocephalus and an enlarged, trapped fourth ventricle, which were also felt to be related to CSF metastases at the outlet of the fourth ventricle and at the cerebral aqueduct. Because of his worsening neurologic condition, his parents stopped treatment and provided comfort measures at home.

Discussion

The differential diagnosis of large temporofacial cystic lesions includes cystic hygroma/lym-

phangioma, teratoma, parotid duct cyst, abscess, congenital encephalocele (6), and cystic brain heterotopia (7). Until now, we had not encountered a cystic RMS.

The Intergroup Rhabdomyosarcoma Study divides head and neck RMS into three categories by site: 1) orbital, 2) parameningeal (middle ear, paranasal sinuses, and nasopharynx), and 3) other head and neck sites (5). The parameningeal group has a less favorable prognosis because of a predisposition to subarachnoid dissemination (2, 8–10). Histologically, RMS can be categorized as: 1) embryonal, 2) botryoid, 3) alveolar, and 4) pleomorphic (3–5). The embryonal subtype (this case) accounts for 56% of RMS and is most frequent in the head-neck region and genitourinary tract.

Imaging of RMS typically shows a homogeneous soft-tissue mass in the orbit, temporal bone, or nasopharynx. The tumor enhances to the same degree as surrounding muscle. Occasionally the tumor is well demarcated, but more often the margins are poorly defined, distorting, or infiltrating adjacent tissue planes. Bone destruction is common and well demonstrated by CT, particularly if bone algorithms are used (5, 11). Contrast enhancement and coronal scans are helpful in detecting tumor that has penetrated the skull base to involve the intracranial compartment. RMS are usually solid tumors (12). Areas of hemorrhagic necrosis may be seen in large RMS (13) and pathologically cystic spaces containing necrotic debris may occur (14, 15). Small cystic spaces within solid tumors have also been identified in pelvic RMS by ultrasound (16). However the predominantly cystic nature of the mass in this case is very unusual. To our knowledge, the communication of cystic loculations in a parameningeal RMS with the subarachnoid space has not been previously described.

We can only speculate how this unusual lesion developed. One possibility is that a RMS arose beneath the skull base and eroded through the bone into the dura. Exposure of the weakened dura to CSF pulsations might permit invagination of CSF into the tumor or formation of a peritumoral collection (Fig. 2). This would explain the expansile nature of the mass, as well as its communication with the subarachnoid space. Another possible explanation is that the tumor arose near a preexisting encephalocele. RMS are associated with a higher than expected incidence of congenital anomalies of the central nervous system, genitourinary system, and cardiovascular system (17). A necrotic tumor that ruptured into the subarachnoid space should have irregular, not

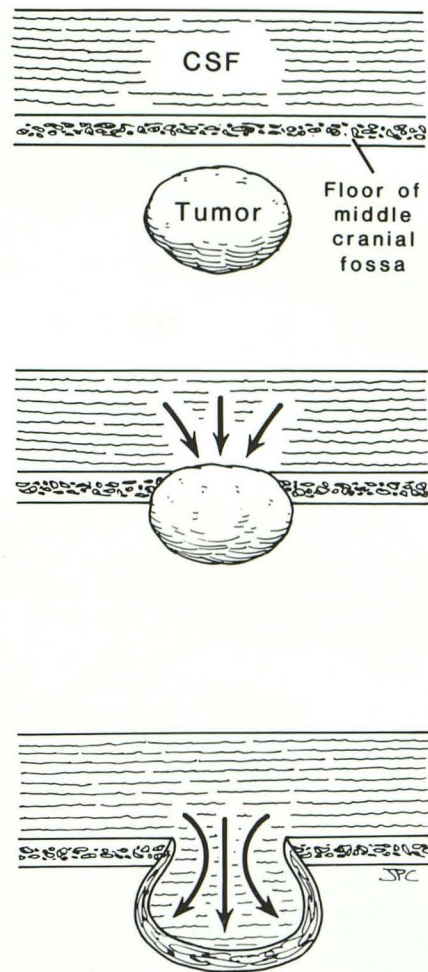


Fig. 2. Proposed mechanism for the development of this lesion. Initially the soft-tissue tumor erodes the floor of the middle cranial fossa. The mass is invaginated and its walls expanded by the pulsatile pressure of the CSF.

smooth, walls and the patient should have had some symptoms of meningeal irritation prior to the placement of the drain.

Aggressive multimodality treatment with surgery, systemic chemotherapy, and radiation therapy have improved the prognosis of RMS considerably in the past decade. Supplemental irradiation to the entire cranium and intrathecal chemotherapy are usually added to the treatment regime in parameningeal RMS, such as the case presented here. Drop metastasis to the spinal subarachnoid space are rare in patients receiving intrathecal chemotherapy, so spinal irradiation is sometimes omitted as in this case (4).

Acknowledgments

The authors gratefully acknowledge the participation of Vincent Albo for adjuvant chemotherapy and Melvin Deutsch for radiotherapy. Thanks to Dara Tomassi and

Lisa Jayson for preparing the manuscript and to Meg Saches for editorial assistance.

References

1. Renick B, Clark RM, Feldman L. Embryonal rhabdomyosarcoma: presentation as a parotid gland mass. *Oral Surg Oral Med Oral Pathol* 1988;65:575-579
2. Wharam M, Beltangady MS, Heyn RM, et al. Pediatric orofacial and laryngopharyngeal rhabdomyosarcoma. *Arch Otolaryngol Head Neck Surg* 1987;113:1225-1227
3. Szabados E, Ribari O, Jori J, Illyes M, Bohus K. Childhood rhabdomyosarcoma in otorhinolaryngology. *Acta Chir Hung* 1987;28:263-269
4. Ruymann F. Rhabdomyosarcoma in children and adolescents. *Hematol Oncol Clin North Am* 1987;1:622-654.
5. Latack JT, Hutchinson RJ, Heyn RM. Imaging of rhabdomyosarcomas of the head and neck. *AJNR* 1987;8:353-359
6. Elster AD, Branch CL. Transalar sphenoidal encephaloceles: clinical and radiologic findings. *Radiology* 1989;170:245-247
7. Wismer GL, Wilkinson AH, Goldstein JD. Cystic temporofacial brain heterotopia. *AJNR* 1989;10(suppl):S32-S33
8. Berry MP, Jenkin DT. Parameningeal rhabdomyosarcoma in the young. *Cancer* 1981;48:281-288
9. Bergamini JA, Nadimi H, Kuo PC. Rhabdomyosarcoma of the parapharyngeal space in an adult patient: an immunohistochemical study. *J Oral Maxillofac Surg* 1989;47:414-417
10. Peters E, Cohen M, Altini M, Murray J. Rhabdomyosarcoma of the oral and perioral region. *Cancer* 1989;63:963-966
11. Vade A, Armstrong D. Orbital rhabdomyosarcoma in childhood. *Radiologic Clin North Am* 1987;25:701-714
12. Feldman BA. Rhabdomyosarcoma of the head and neck. *Laryngoscope* 1982;92:424-425
13. Lawrence W, Jegge G, Foote FW. Embryonal rhabdomyosarcoma. *Cancer* 1964;17:361-376
14. Linscheid RL, Soule EH, Henderson ED. Pleomorphic rhabdomyosarcomata of the extremities and limb girdles. *J Bone Joint Surg (Am)* 1965;47:715-726
15. Horn RC, Enterline HT. Rhabdomyosarcoma: a clinicopathological study and classification of 39 cases. *Cancer* 1958;11:181-199
16. Bahnson RR, Zaontz MR, Maizels M, Shkolnik AA, Firlit C. Ultrasonography and diagnosis of pediatric genitourinary rhabdomyosarcoma. *Urology* 1989;33:64-68
17. Ruymann FB, Maddux HR, Ragab A, et al. Congenital anomalies associated with rhabdomyosarcoma: an autopsy study of 115 cases. A report from the Intergroup Rhabdomyosarcoma Study Committee (representing the Children's Cancer Study Group, and the Pediatric Intergroup Statistical Center). *Med Pediatr Oncol* 1988;16:33-39