



Discover Generics

Cost-Effective CT & MRI Contrast Agents



WATCH VIDEO

AJNR

Extraaxial cavernous hemangioma with hemorrhage.

O Krief, J P Sichez, G Chedid, B Bencherif, A Zouaoui, F Le Bras and C Marsault

AJNR Am J Neuroradiol 1991, 12 (5) 988-990
<http://www.ajnr.org/content/12/5/988.citation>

This information is current as of June 9, 2025.

Extraaxial Cavernous Hemangioma with Hemorrhage

O. Krief,¹ J. P. Sichez,² G. Chedid,¹ B. Bencherif,¹ A. Zouaoui,¹ F. Le Bras,¹ and C. Marsault¹

Intracranial cavernomas, initially described as rare lesions [1], have been seen with increasing frequency since the advent of MR imaging [2–5]. MR features of cavernomas are highly suggestive of the diagnosis, although not pathognomonic. Cavernomas are classically intraparenchymal lesions and occult to angiography. They have a pseudotumoral growth [6] and a low potential for life-threatening hemorrhage, at least in supratentorial locations [7].

We report a case of a vascular lesion in an atypical location that was identified as a cavernous hemangioma. The lesion arose in the perimesencephalic cistern, and was accompanied by symptoms of acute onset of diplopia and meningeal signs. Extracerebral cavernous hemangiomas, as reported in the literature, have slightly different clinical, angiographic, and surgical features compared with intraparenchymal lesions, and can easily be misdiagnosed as meningioma unless MR imaging is performed.

Case Report

A 43-year-old woman without previous neurologic disease was admitted for diplopia and headaches of 3 weeks duration. A CT study performed 2 weeks after onset of symptoms disclosed a hyperdense nodular lesion of the right perimesencephalic cistern (Fig. 1A). The patient waited 1 week before seeking medical treatment.

Clinical examination on admission revealed paresis of the right superior oblique muscle. MR imaging (Signa 1.5 T, General Electric, Milwaukee, WI) showed a round, 8-mm lesion in the perimesencephalic cistern beneath the tentorium cerebelli with no connection to any of the regional vessels. The lesion had a heterogeneous hyperintense signal on both short and long TR/TE sequences and enhanced after contrast injection (Figs. 1B and 1C).

Surgical removal was not attempted at the time. The patient's symptoms remained identical for 3 months, when the headaches increased acutely in intensity and frequency. A repeat MR study showed enlargement of the previously identified lesion with signal features of a "cavernomatous" lesion. The enlarged lesion now appeared intraparenchymal and bulged into the adjacent subarachnoid space (Figs. 1D–1F).

At surgery, the lesion was found to be enclosed within a thin arachnoid membrane, which was adherent to the lateral aspect of the right cerebral peduncle. The mass was completely removed, and

microscopic examination revealed a hemorrhagic lesion with internal fibrous septa suggestive of cavernous hemangioma.

Discussion

According to Russell and Rubinstein [8], cavernomas are classified along with capillary telangiectases, venous angiomas, and arteriovenous malformations as intracranial vascular hamartomas. Cavernomas classically appear as honeycomb-like dilated vascular spaces separated by endothelial-lined fibrous septa without interspersed neural tissue or elastic or smooth muscular components. The presence of intervening neural tissue distinguishes cavernomas from capillary telangiectases. According to Simard et al. [9], the presence of muscular fibers does not exclude the diagnosis of cavernomas. Thrombosis and low internal flow are the main phenomena that account for the inability to see cavernomas on standard angiographic examinations [10]. CT is disappointing in its depiction of occult cerebrovascular malformations. In a series reported by Gomori et al. [4] of 49 patients with MR characteristics of occult cerebrovascular malformations, only 29 had a positive finding on CT.

MR features are highly suggestive of cavernomas although not pathognomonic. Findings include clusters of foci of hyperintense signal on all sequences, resulting from extracellular methemoglobin corresponding to hemorrhage in different stages of evolution, which are surrounded by a hypointense rim of hemosiderin on T2-weighted images. Hemorrhagic metastases, capillary telangiectases, and thrombosed arteriovenous malformations can exhibit the same features [11, 12].

Typical locations of cavernomas include the subcortical hemispheric area and brainstem [1, 8]. Subarachnoid, subdural, and epidural cavernomas have already been described, but represent atypical locations [8]. Only five extracerebral lesions were reported by Simard et al. [9] after a review of the literature of 126 patients, one by Voigt and Yasargil [13], and none by Lobato et al. [14] in their review of 241 cases of occult cerebrovascular malformations. Most of the extraparenchymatous cavernomas have been found in the middle cranial fossa, where they may mimic meningioma [15–20].

Received October 30, 1990; revision requested February 12, 1991; revision received March 21, 1991; accepted March 26, 1991.

¹ Department of Radiology, Hôpital de la Pitié, 83 Bd de l'hôpital, 75013 Paris, France. Address reprint requests to O. Krief.

² Department of Neurosurgery, Hôpital de la Pitié, Paris, France.

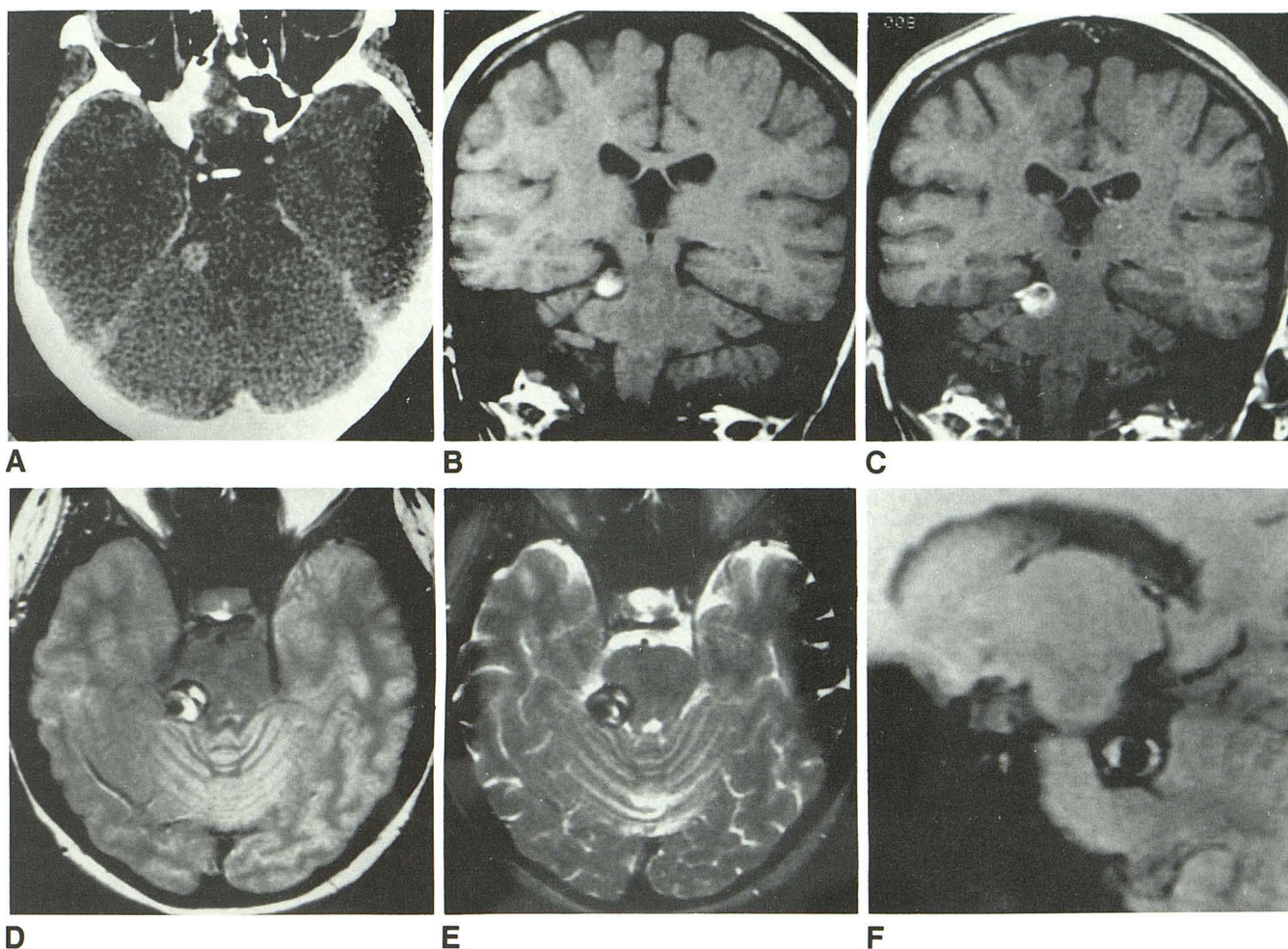


Fig. 1.—43-year-old woman with diplopia and headaches.

A, Postcontrast CT scan 2 weeks after onset of symptoms shows perimesencephalic nodular enhanced lesion.

B and C, Coronal T1-weighted MR images (550/20/2) before (B) and after (C) administration of gadopentetate dimeglumine. Precontrast image shows hyperintensity of nodular lesion mainly in its central part, with slight mass effect on adjacent brainstem. In C, there is significant postcontrast enhancement of periphery of lesion, and relationship with tentorium is clearly seen.

D and E, Repeat MR examination using T2-weighted images, 2500/20/1 (D) and 2500/90/1 (E). Lesion now shows features more typical of cavernoma, with two adjacent high-signal foci from methemoglobin surrounded by hypointense rim of hemosiderin.

F, Parasagittal gradient-echo multiplanar GRASS image (450/20/2) with flip angle = 110° shows extraparenchymal location of lesion and its relationship with cerebellar peduncle.

Cerebellopontine angle lesions have also been reported as extending into the internal auditory canal [21]. Extracerebral cavernomas, described as highly vascularized lesions with an angiographic blush, may mimic meningioma, even on CT [18, 22].

Although most of the neuropathologic textbooks make no distinction between cavernomas and cavernous hemangiomas [1, 8, 23], Lasjaunias et al. [22], relying on the reports of Harris and Jakobiec [24] on intraorbital cavernous hemangiomas, assert that the two lesions do not correspond to the same pathologic entity. Cavernomas are intraparenchymal and can grow by iterative intralesional microhemorrhage caused by weakening of the parietal septa by thrombosis or, less commonly, by angiectasia [25]. Cavernous hemangiomas are mainly extraparenchymatous and constitute a truly tu-

moral disease with an in vitro potential of proliferation of endothelial cells, as in liver or orbital locations [24, 26].

The combination of angiography, CT, and MR findings should allow an easy diagnosis of the lesion. Meningioma can now be excluded, since hemorrhage is an atypical feature of small meningioma [27]. The main differential diagnoses that could remain are leptomeningial hemorrhagic metastases especially from melanoma [11] and thrombosed aneurysm when the lesion is close to a major blood vessel [28].

ACKNOWLEDGMENT

We thank especially Dominique Mompont for revision of the manuscript.

REFERENCES

1. Zulch K. *Brain tumors*, 3rd ed. Berlin: Springer Verlag, 1986:452-453
2. New PJF, Ojemann RG, Davis KR. MR and CT of occult vascular malformations of the brain. *AJNR* 1986;7:771-779
3. Lemme-Plaghos L, Kucharczyk W, Brant-Zawadski M. MR imaging of angiographically occult vascular malformations. *AJNR* 1986;7:217-222
4. Gomori JM, Grossman RI, Goldberg HI, Hackney DB, Zimmerman RA, Bilaniuk LT. Occult cerebral vascular malformations: high-field imaging. *Radiology* 1986;158:707-713
5. Rigamonti D, Drayer BP, Johnson PC, Hadley MN, Zabramski J, Spetzler RF. The MRI appearance of cavernous malformations (angiomas). *J Neurosurg* 1987;67:518-524
6. Pozzati E, Giuliani G, Poppi M. Growth of cerebral cavernous angiomas. *Neurosurgery* 1989;25:92-97
7. Giombini S, Morello G. Cavernous angiomas of the brain. *Acta Neurochir* 1978;40:61-82
8. Russell D, Rubinstein L. *Pathology of tumours of the nervous system*, 5th ed. London: Edward Arnold, 1989:730-746
9. Simard JM, Garcia-Bengocea F, Ballinger WR Jr, Mickle JP, Quisling RG. Cavernous angiomas: a review of 126 collected and 12 new clinical cases. *Neurosurgery* 1986;18:162-172
10. Yarsargil MG. Cavernous and occult angiomas. In: *Microneurosurgery*, vol 3. Stuttgart: Thieme, 1988:415-434
11. Sze G, Krol G, Olsen WL, et al. Hemorrhagic neoplasms: MR mimics of occult vascular malformations. *AJNR* 1987;8:795-802
12. Rapacki T, Brantley M, Furlow T, Geyer C, Toro V, Georges E. Heterogeneity of cerebral cavernous hemangiomas on MR imaging. *J Comput Assist Tomogr* 1990;14:18-25
13. Voigt K, Yarsargil MG. Cerebral cavernous haemangiomas or cavernomas: incidence, pathology, localisation, diagnosis, clinical features and treatment. *Neurochirurgia* 1976;19:59-68
14. Lobato RD, Perez C, Rivas JJ, Cordobes F. Clinical, radiological, and pathological spectrum of angiographically occult intracranial vascular malformations. *J Neurosurg* 1988;68:518-531
15. Buonaguidi R, Canapicci R, Mimassi N, Ferdeghini M. Intracranial cavernous hemangioma. *Neurosurgery* 1984;14:732-734
16. Tien R, Dillon W. MR imaging of cavernous hemangioma of the optic chiasm. *J Comput Assist Tomogr* 1989;13:1087-1100
17. Fhelings M, Tucker W. Cavernous hemangioma of the Meckel's cave. *J Neurosurg* 1988;68:645-647
18. Mori K, Handa H, Hiedefuku G, Mori K. Cavernomas in the middle fossa. *Surg Neurol* 1980;14:21-31
19. Namba S. Extracerebral cavernous hemangiomas of the middle cranial fossa. *Surg Neurol* 1983;19:379-388
20. Kaard H, Khangure M, Waring P. Extraaxial parasellar cavernous hemangioma. *AJNR* 1990;11:1259-1261
21. Sundaresan N, Eller T, Ciric I. Hemangiomas in the internal auditory canal. *Surg Neurol* 1976;6:119-121
22. Lasjaunias P, Terbrugge K, Rodesch G, et al. Vraies et fausses lésions veineuses cérébrales. *Neurochirurgie* 1989;35:132-139
23. Rubinstein LJ. *Tumors of the central nervous system*, fascicle 6. Washington, DC: Armed Force Institute of Pathology, 1972
24. Harris G, Jakobiec F. Cavernous hemangiomas of the orbit. *J Neurosurg* 1979;51:219-228
25. Sigal R, Krief O, Houteville J, Halimi P, Doyon D, Pariente D. Occult cerebro-vascular malformations: follow-up with MR imaging. *Radiology* 1990;176:815-819
26. Ohbayashi M, Tomita K, Agawa S, Sichijo F, Shinno K, Matsumoto K. Multiple cavernomas of the orbit. *Surg Neurol* 1988;29:32-34
27. Kondziolka D, Bernstein M, Resch L, et al. Significance of hemorrhage into brain tumors. *J Neurosurg* 1987;67:852-857
28. Atlas S, Grossman R, Goldberg H, Hackney DB, Bilaniuk L, Zimmerman R. Partially thrombosed giant intracranial aneurysms: correlation of MR and pathologic findings. *Radiology* 1987;162:111-114