

# Generic Contrast Agents

Our portfolio is growing to serve you better. Now you have a *choice*.



FRESENIUS  
KABI

[VIEW CATALOG](#)

# AJNR

## Positioning platform for nonoblique total spine MR imaging.

J W Langston, S A Gronemeyer, S E Anderson and S L Hanna

*AJNR Am J Neuroradiol* 1991, 12 (5) 1001-1002

<http://www.ajnr.org/content/12/5/1001.citation>

This information is current as  
of May 31, 2025.

# Positioning Platform for Nonoblique Total Spine MR Imaging

James W. Langston,<sup>1</sup> Suzanne A. Gronemeyer,<sup>1</sup> Stan E. Anderson,<sup>2</sup> and Soheil L. Hanna<sup>1</sup>

If spinal MR imaging is to replace myelography, a complete spinal MR examination must be possible in a reasonable time, and nonoblique images of the spinal cord must be obtained. Previously proposed spine-coil positioning devices [1–3] do not provide for patient pivoting in the horizontal plane in order to eliminate cord obliquity, and one device [2] fails to maintain the surface coil in the center (or “sweet spot”) of the magnet bore, where the magnetic field is most homogeneous. We have developed a positioning device for spinal MR imaging that allows fast longitudinal positioning and horizontal plane pivoting to prevent spinal cord obliquity.

## Materials and Methods

A three-layer positioning platform (in development by MRI Devices, Inc., Waukesha, WI, patent pending) was constructed entirely of plastic (Fig. 1). The bottom unit contains a 14 × 31 cm rectangular surface coil and two slots filled with plastic spheres on which the middle carrier plate rolls to permit calibrated passive longitudinal (Z axis) patient movement. A top swivel plate rests on top of the middle carrier plate and pivots in the horizontal (XY) plane.

The patient is positioned so that the mid-spine is approximately over the pivot point. The spine coil and bottom coil unit are never moved from the magnet center after initial placement. T1 sagittal scout images are obtained to determine the distance the patient should be moved along the Z axis. The middle carrier plate of the platform is then rolled in or out of the magnet bore to perfectly position the patient along the Z axis. The spinal cord midline is then approximated with the aid of an oblique T1 coronal scout image (Fig. 2). The patient is rotated in the horizontal plane by calibrated rotation of the top swivel plate to make the spinal cord approximately parallel to the sagittal plane. Subsequent three-slice T1 sagittal scout imaging permits fine-tuned pivoting in the horizontal plane to perfectly align the spinal cord parallel with the sagittal plane. All scout sequences require less than 30 sec.

The definitive diagnostic examination follows (Fig. 3A). Multiple, rapid, calibrated repositioning along the Z axis for high-resolution imaging of the entire spine is accomplished without additional scout images, without moving the patient table or surface coil, and without active patient movement (Fig. 3B). The surface-coil sensitivity range

is such that coil tuning and resonant frequency or RF transmitter readjustments are unnecessary.

## Discussion

From January 1989 through August 1990, 236 spinal MR studies were performed in our institution using our positioning platform with a 1.0-T MR scanner (Magnetom 42, Siemens Medical Systems, Iselin, NJ). Patients were being examined for metastatic spinal disease or primary spinal neoplasia. Only four of the studies could not be completed because of patient motion (two), inadequate IV installation for injection of contrast agent (one), and scanner difficulties (one). Although most of our patients were children, some examinations were performed on long-term follow-up patients who are now adults. An “egg crate” mattress on top of the flat platform supports patients of all weights comfortably.

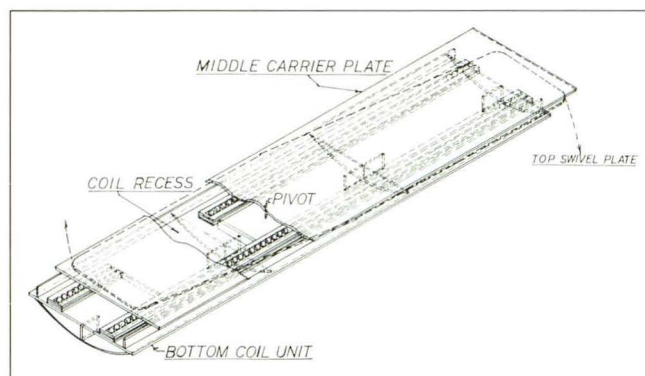


Fig. 1.—Positioning platform for nonoblique total spine MR. The stationary bottom coil unit contains a recess for the spine coil and two rows of nylon balls on which the middle carrier plate rides. After the patient and entire platform are moved to the center of the magnet, a 27-sec sagittal scout image is acquired, and the middle carrier plate is rolled in or out of the magnet bore to perfectly position the patient along the Z axis. The top swivel plate permits rotation about the pivot point in the horizontal plane.

Received October 18, 1990; revision requested December 11, 1990; revision received January 25, 1991; accepted January 28, 1991.

This work was supported in part by the National Cancer Institute, Cancer Center Support (CORE) grant P30CA21765 and by the American Lebanese Syrian Associated Charities.

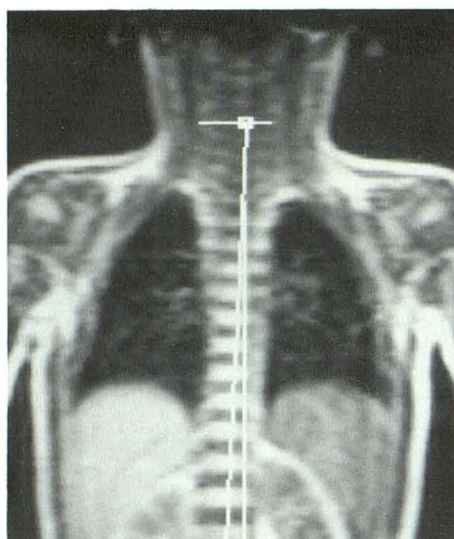
<sup>1</sup> Department of Diagnostic Imaging, St. Jude Children's Research Hospital, and Department of Radiology, University of Tennessee, 332 N. Lauderdale, P.O. Box 318, Memphis, TN 38101. Address reprint requests to J. W. Langston.

<sup>2</sup> Department of Biomedical Engineering, St. Jude Children's Research Hospital, Memphis, TN 38101.

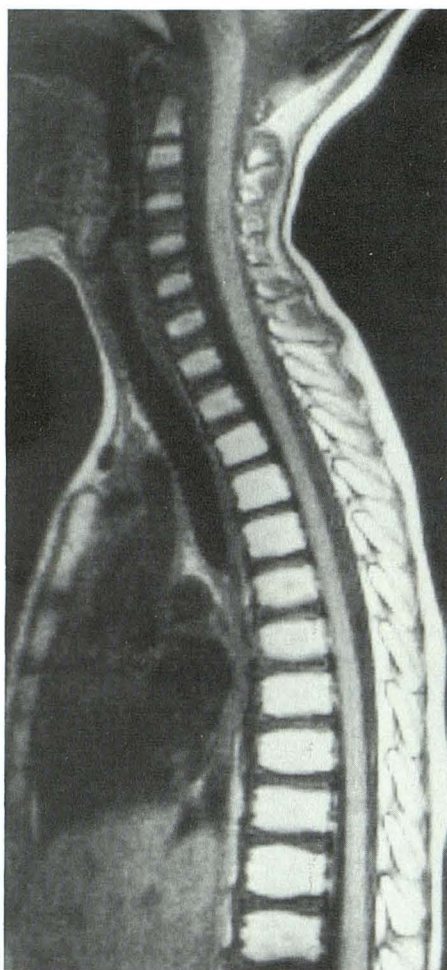


Fig. 2.—A 14-sec oblique coronal scout image and rotation of the top swivel plate are used to position the spinal cord parallel to the sagittal plane. A 27-sec sagittal scout image follows for fine tuning.

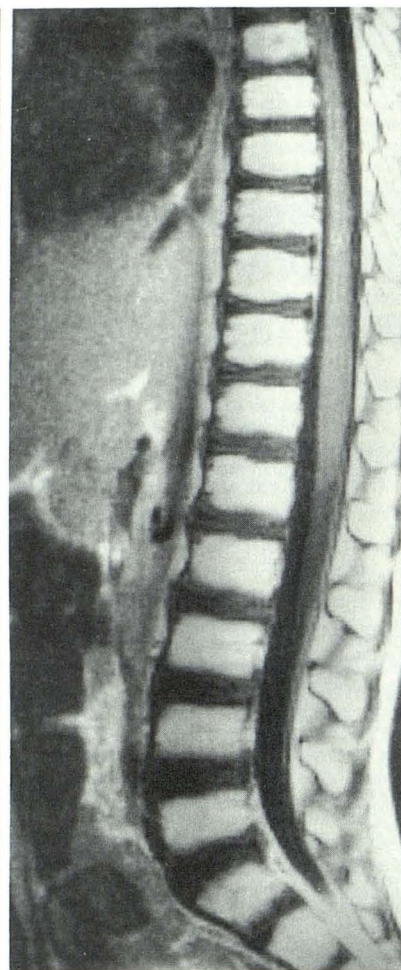
Fig. 3.—A and B, Definitive true-sagittal diagnostic images, upper level (A) and lower level (B). The patient is repositioned by rolling the middle carrier plate along the Z axis. Imaging at the new level proceeds without having to move the patient table or surface coil, without retuning the surface coil or the RF frequency or transmitter, and without



2



3A



3B

Acquisition of a total spine MR examination is important in patients at risk for metastatic spinal disease or with known neoplasia within the spinal canal. In our experience a high percentage of children in need of a total spine MR examination must be studied with either sedation or general anesthesia. It is thus essential to complete the examination in 1 hour or less, which our positioning platform routinely permits.

Since our patients are imaged repeatedly during the course of therapy and in many cases are followed for a number of years, the ability to closely compare current studies with earlier ones is quite helpful. With our platform, we are able to reproduce spine positioning very closely from study to study, which is particularly helpful in following small lesions. To our knowledge, no other spinal MR positioning device exists that permits both calibrated passive patient movement along the

Z axis and calibrated passive patient rotation in the horizontal plane. Although many scanners have oblique imaging sequences, they usually require a longer echo time, which reduces T1 weighting, contrast, and signal to noise ratio. Furthermore, alignment of the spinal cord with the sagittal imaging plane is more precise with this technique than with oblique imaging sequences.

#### REFERENCES

1. Krol G, Sze G, Amster J. Table-top support plate for imaging the entire spine with surface-coil MR. *AJNR* 1988;9:396-397
2. Williamson MR, Angtuaco EJC, Jackson JC, Pruitt WB. Spine: device to facilitate surface coil MR imaging. *Radiology* 1988;167:273-274
3. Abrahams JJ, Lange RC. Coil holder and marker system for MR imaging of the total spine. *Radiology* 1989;172:869-871