



Discover Generics

Cost-Effective CT & MRI Contrast Agents



FRESENIUS
KABI

WATCH VIDEO

AJNR

Unusual MR and CT appearance of an epidermoid tumor.

G F Gualdi, C Di Biasi, G Trasimeni, A Pingi, A Vignati and G Maira

AJNR Am J Neuroradiol 1991, 12 (4) 771-772

<http://www.ajnr.org/content/12/4/771.citation>

This information is current as
of June 9, 2025.

Unusual MR and CT Appearance of an Epidermoid Tumor

Epidermoid tumors are rare congenital lesions of ectodermal origin (0.2–1% of intracranial neoplasms). They usually are found in the cerebellopontine angle, sellar and suprasellar region, and middle cranial fossa. Histologically, they often have a thin wall lined by stratified squamous epithelium, surrounding a mixture of desquamated debris, cholesterol, keratin, and water [1]. We report a case of an epidermoid tumor that was hyperdense on CT (before and after administration of contrast material), was inhomogeneously hypointense on T1-weighted MR images, and had no signal on T2-weighted images.

Case Report

A 51-year-old man had a long-standing frontal headache that had increased in severity during the past year, and a 2-month history of visual changes. Campimetric examination showed visual loss in the lateral field of the left eye. Results of a neurologic examination were normal. Radiographs of the skull showed erosion of the dorsum sellae and of the anterior and posterior clinoid processes. MR (Figs. 1A–1C) showed a well-defined, well-margined mass in the sellar-suprasellar region. It was inhomogeneously hypointense on T1-weighted images and had no signal on T2-weighted images. After administration of gadopentetate dimeglumine, only minimal enhancement of the capsule was seen. On CT, the lesion was hyperdense before the injection of contrast material (Fig. 1D) and showed no enhancement afterward. Because of the nonspecific MR and CT findings, the diagnosis was solid sellar-suprasellar tumor of uncertain cause. At surgery, a yellowish, dense, friable (as compressed wax) mass was found. Histologic examination showed an epidermoid tumor that had a relatively thin capsule composed of connective tissue in the outer part and of stratified squamous epithelium in the inner part. The capsule lined a cavity that contained epithelial debris, crystals of cholesterol, and a large amount of keratin. No calcification was seen.

Discussion

On CT, the typical appearance of epidermoid tumors is that of well-circumscribed, lobulated, hypodense masses that show no enhancement after administration of contrast material. The low density is due to the presence of fat, including cholesterol. However, some authors [2, 3] have described epidermoid tumors that were hyperdense before injection of contrast material. A case also has been reported [4] in which slight peripheral enhancement occurred. Braun et al. [2] reported that the physiochemical basis of increased attenuation is uncertain. They think it depends on "calcification of the keratinized debris present throughout the lesion, and saponification of the debris to calcium soaps." However, it has been reported that iron present as both ferrocalsium complexes and iron-containing pigments such as hemoglobin and hemosiderin also may contribute to the hyperdensity.

On MR, epidermoid tumors usually have low intensity (close to that of CSF) on T1-weighted images and high intensity on T2-weighted images [5, 6]. The MR characteristics depend on the tumor's relative composition of cholesterol and keratin; generally, the cholesterol is in a solid state and has a low signal on T1-weighted images. However, cases have been reported in which these tumors had high signal intensity on T1-weighted images [7, 8] or low signal intensity on T2-weighted images [9, 10]. Epidermoid tumors with short T1 relaxation time have a high content of lipid composed of mixed triglycerides containing unsaturated fatty acid residues. Possible causes of the signal void on T2-weighted images include calcification, fibrosis, and paramagnetic effects. In some epidermoid tumors, a variable proportion of the cholesterol and keratin are crystalline with some microcalcifications, which could result in a reduction of T2 weighting. Iron, present as ferrocalsium complexes and iron-containing pigments also may contribute to MR hypointensity. Other causes of low signal intensity could be attributed to low hydration, high proteinaceous content, and high viscosity of the secretions rather than to paramagnetic effects [11, 12].

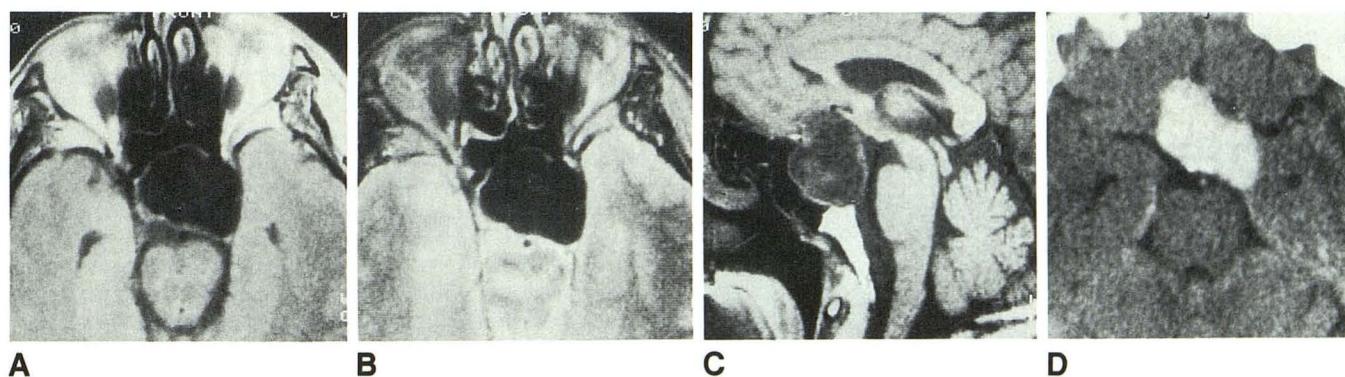


Fig. 1.—Epidermoid tumor.

A, Axial mixed-weighted MR image (1800/15/1) shows a lobulated low-intensity mass in sellar-suprasellar region. Thin peripheral rim represents capsule of mass.

B, Axial T2-weighted MR image (1800/90/1) shows no signal in mass, indicating short T2 of lesion.

C, Sagittal T1-weighted MR image (500/15/2) shows lobulated low-signal-intensity mass in sellar-suprasellar region and upward displacement of chiasm.

D, Axial unenhanced CT scan shows hyperdense lesion (70–80 H).

In our case, the lesion was hyperdense on unenhanced CT and showed no enhancement after administration of contrast material. The mass was inhomogeneously hypointense on T1-weighted and proton-density MR images and had no signal intensity on T2-weighted images. Only minimal peripheral enhancement was seen after injection of gadopentetate dimeglumine. We could not find a previous report of an epidermoid tumor that had these CT and MR appearances. Our diagnosis was solid sellar-suprasellar tumor of uncertain cause because of the nonspecific MR and CT findings. However, a possible diagnosis could be an atypical meningioma.

G. F. Gualdi
C. Di Biasi
G. Trasimeni
A. Pingi

Università degli Studi di Roma "La Sapienza"
Rome, Italy

A. Vignati
G. Maira

Università S. Cuore Policlinico A. Gemelli
Rome, Italy

REFERENCES

1. Tan TI. Epidermoids and dermoids of the central nervous system. *Acta Neurochir (Wien)* **1972**;26:13-24
2. Braun IF, Naidich TP, Leeds NE, Koslow M, Zimmermann HM, Chase NE. Dense intracranial epidermoid tumors. *Radiology* **1977**;122:717-719
3. Nagashima C, Takahama M, Sakaguchi A. Dense cerebellopontine angle epidermoid cyst. *Surg Neurol* **1982**;17:172-177
4. Mikhael MA, Mattar AG. Intracranial pearly tumors: the roles of computed tomography, angiography and pneumoencephalography. *J Comput Assist Tomogr* **1978**;2:421-429
5. Latack JT, Kartush JM, Kemink JL, Graham MD, Knake JE. Epidermoidomas of the cerebellopontine angle and temporal bone: CT and MR aspects. *Radiology* **1985**;157:361-366
6. Olson JJ, Beck DW, Crawford SC, Menezes AH. Comparative evaluation of intracranial epidermoid tumors with computed tomography and magnetic resonance imaging. *Neurosurgery* **1987**;21:357-360
7. Newton DR, Larson TC III, Dillon WP, Newton TH. Magnetic resonance characteristics of cranial epidermoids and teratomatous tumors (abstr). *AJNR* **1987**;8:945
8. Horowitz BL, Chari MV, Yames R, Bryan RN. MR of intracranial epidermoid tumors: correlation of in vivo imaging with in vitro ¹³C spectroscopy. *AJNR* **1990**;11:299-302
9. Vion-Dury J, Vincentelli F, Jiddane M, et al. MR imaging of epidermoid cysts. *Neuroradiology* **1987**;29:333-338
10. Rooney MS, Poon PY, Vortzman G. Magnetic resonance imaging of intracranial epidermoids: report of two cases. *J Can Assoc Radiol* **1987**;38:283-287
11. Dillon PW, Som PM, Fullerton GD. Hypointense MR signal in chronically inspissated sinonasal secretions. *Radiology* **1990**;174:73-78
12. Som PM, Dillon PW, Fullerton GD, Zimmerman RA, Rajagopalan B, Marom Z. Chronically obstructed sinonasal secretions: observations on T1 and T2 shortening. *Radiology* **1989**;172:515-520