



Discover Generics

Cost-Effective CT & MRI Contrast Agents



FRESENIUS
KABI

WATCH VIDEO

AJNR

MR of normal optic chiasm.

T el Gammal

AJNR Am J Neuroradiol 1991, 12 (3) 584

<http://www.ajnr.org/content/12/3/584.citation>

This information is current as
of June 8, 2025.

4. Behrman S, Carrol JD, Janota I, Matthews WS. Progressive supranuclear palsy: clinico-pathological study of four cases. *Brain* 1969;92:663-678
5. Ishino H, Otsuki S. Frequency of Alzheimer's neuro-fibrillary tangles in the cerebral cortex in progressive supranuclear palsy (subcortical argyrophilic dystrophy). *J Neurol Sci* 1976;28:309-316
6. Ambrosetto P, Michelucci R, Forti A, Tassinari CA. CT findings in progressive supranuclear palsy. *J Comput Assist Tomogr* 1984;8:406-409

Reply

On reviewing Dr. Ambrosetto's paper in the September/October 1987 issue of the *AJNR* [1], please note that in Table 1, page 850, only two (25%) of the eight patients with progressive supranuclear palsy show hippocampal lucencies. In the previous paper by Ambrosetto et al. [2], which reports on three cases on the same subject, this finding is not mentioned. Admittedly, however, prominent hippocampal lucencies are present in Figure 1 in this second paper.

In our paper [3], as shown in Table 1, page 106, the specificity of the hippocampal lucency is 75%. That is, 25% of control subjects also had a hippocampal lucency, whereas 82% of the Alzheimer group showed the finding.

In summary, 82% of our Alzheimer patients showed a hippocampal lucency. In Dr. Ambrosetto's group of patients who had progressive supranuclear palsy, 25% showed the lucency, which is approximately the same percentage as our control group.

Ajax E. George
Mony J. de Leon
NYU Medical Center
New York, NY 10016

REFERENCES

1. Ambrosetto P. CT in progressive supranuclear palsy. *AJNR* 1987;8:849-851
2. Ambrosetto P, Michelucci R, Forti A, Tassinari CA. CT findings in progressive supranuclear palsy. *J Comput Assist Tomogr* 1984;8:406-409
3. George AE, de Leon MJ, Stylopoulos LA, et al. CT diagnostic features of Alzheimer disease: importance of the choroidal/hippocampal fissure complex. *AJNR* 1990;11:101-107

MR of Normal Optic Chiasm

I enjoyed the interesting case report by Walker et al. [1] of chiasmal sarcoidosis. I would like to point out that in Figure 1B in their report, the arrow points to enhancement in relation to the optic tract, not the optic chiasm. Figures 1A-1C with this letter show MR findings of the normal optic chiasm.

Taher El Gammal
University of Alabama at Birmingham
University of Alabama Hospital
Birmingham, AL 35233

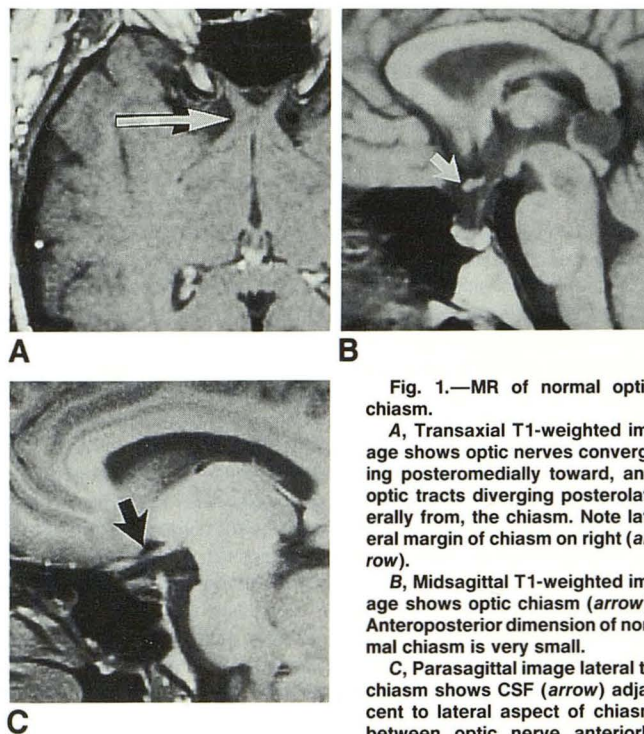


Fig. 1.—MR of normal optic chiasm.

A, Transaxial T1-weighted image shows optic nerves converging posteromedially toward, and optic tracts diverging posterolaterally from, the chiasm. Note lateral margin of chiasm on right (arrow).

B, Midsagittal T1-weighted image shows optic chiasm (arrow). Anteroposterior dimension of normal chiasm is very small.

C, Parasagittal image lateral to chiasm shows CSF (arrow) adjacent to lateral aspect of chiasm between optic nerve anteriorly and optic tract posteriorly. Chiasm itself is not visualized.

REFERENCE

1. Walker FO, McLean WT Jr, Elster A, Stanton C. Chiasmal sarcoidosis. *AJNR* 1990;11:1205-1207

Reply

Dr. El Gammal has noted correctly an error in the legend for Figure 1B on page 1206 in our recent paper [1]. This figure shows enhancement of the optic tract. The legend should be amended to read as follows: Postcontrast sagittal T1-weighted image shows intense abnormal enhancement of meningeal lining of optic tract (arrow). The chiasmal involvement is shown better in the most anterior cranial image in Figure 1C of the original report.

Francis O. Walker
Allen Elster
Bowman Gray School of Medicine
Winston-Salem, NC 27103

REFERENCE

1. Walker FO, McLean WT Jr, Elster A, Stanton C. Chiasmal sarcoidosis. *AJNR* 1990;11:1205-1207

Letters are published at the discretion of the Editor and are subject to editing.
Letters to the Editor must not be more than two double-spaced, typewritten pages. One or two figures may be included. Abbreviations should not be used.
Material being submitted or published elsewhere should not be duplicated in letters, and authors of letters must disclose financial associations or other possible conflicts of interest.
Letters concerning a paper published in the *AJNR* will be sent to the authors of the paper for a reply to be published in the same issue. Opinions expressed in the Letters to the Editor do not necessarily reflect the opinions of the Editor.