



## Discover Generics

Cost-Effective CT & MRI Contrast Agents



[WATCH VIDEO](#)

# AJNR

## Ectopia of the posterior pituitary gland or lipoma?

*AJNR Am J Neuroradiol* 1991, 12 (3) 579-581  
<http://www.ajnr.org/content/12/3/579.citation>

This information is current as  
of June 16, 2025.

## Letters

### Ectopia of the Posterior Pituitary Gland or Lipoma?

I read, with great interest, the article [1] by Benshoff and Katz, "Ectopia of the Posterior Pituitary Gland as a Normal Variant: Assessment with MR Imaging," that appeared in the July/August 1990 issue of the *AJNR*. I am writing because of my concern about the confusion that this article may create. It is my opinion that the ectopic posterior pituitary gland does not occur as a normal variant as described by Benshoff and Katz.

In a series of 16 ectopic neurohypophyses and in a review of the world literature, I have not encountered an ectopic neurohypophysis occurring as a normal variant. However, I have seen several lipomas in the region of the tuber cinereum that look just like ectopic neurohypophyses. Such a lipoma is shown in Figure 6 in the article "Pathogenesis of Intracranial Lipoma: An MR Study in 42 Patients" [2] by Truwit and Barkovich. These lipomas are differentiated from ectopic neurohypophyses by the presence of a normal infundibulum, chemical-shift artifact, normal pituitary function, slightly more posterior location, and often more elongated shape. I think that the cases presented by Benshoff and Katz [1] are lipomas rather than ectopic neurohypophyses. In both cases, the patient had a normal infundibulum and normal pituitary function. A chemical-shift artifact was present in one case, and the lesion was located posterior to the position of the normal infundibulum in the second case. It is not significant that Benshoff and Katz did not see the normal posterior sellar pituitary bright spot, as this is also difficult to detect in many normal subjects.

In summary, I think that the cases presented by Benshoff and Katz are lipomas rather than ectopic neurohypophyses. I do not think that ectopic neurohypophysis should be considered a normal variant.

James J. Abrahams  
Yale University  
New Haven, CT 06510

#### REFERENCES

1. Benshoff ER, Katz BH. Ectopia of the posterior pituitary gland as a normal variant: assessment with MR imaging. *AJNR* 1990;11:709-712
2. Truwit CL, Barkovich AJ. Pathogenesis of intracranial lipoma: an MR study in 42 patients. *AJNR* 1990;11:665-674, *AJR* 1990;155:855-864

I read with interest two articles [1, 2] in the July/August 1990 issue of the *AJNR*. In the first of these, Truwit and Barkovich [1] show in Figure 6 what they describe as a "bilobed hypothalamic/mamillary body, suprasellar lipoma." When this image is compared with those in the article by Benshoff and Katz [2], the similarities are apparent.

Benshoff and Katz ascribe increased signal in the suprasellar and mamillary region to ectopic posterior pituitary tissue. The illustration in the article by Truwit and Barkovich also shows the pituitary gland, which fails to demonstrate increased T1 signal in the posterior aspect of the sella turcica, which is seen in 90-100% of normal pituitary glands [3, 4], and which Benshoff and Katz cite as evidence, supporting their contention for normally functioning ectopic tissue.

Neither article indicates surgical or histologic verification. I would submit that, in view of the similarities of the figures, Drs. Truwit and Barkovich may have been observing ectopic pituitary tissue, whereas Drs. Benshoff and Katz may have visualized suprasellar lipomas.

David H. Berns  
Drs. Hill & Thomas Co.  
Cleveland, OH 44122

#### REFERENCES

1. Truwit CL, Barkovich AJ. Pathogenesis of intracranial lipoma: an MR study in 42 patients. *AJNR* 1990;11:665-674, *AJR* 1990;155:855-864
2. Benshoff ER, Katz BH. Ectopia of the posterior pituitary gland as a normal variant: assessment with MR imaging. *AJNR* 1990;11:709-712
3. Colombo N, Berry I, Kucharczyk J, et al. Posterior pituitary gland: appearance on MR images in normal and pathologic states. *Radiology* 1987;165:481-485
4. Fujisawa I, Asato R, Nishimura K, et al. Anterior and posterior lobes of the pituitary gland: assessment by 1.5 T MR imaging. *J Comput Assist Tomogr* 1987;11:214-220

#### Reply to Dr. Abrahams

It is unfortunate that Dr. Abrahams is confused by our article [1], but we think that several of his basic assumptions about our cases are inaccurate.

Several points support our contention that our cases represent ectopic neurohypophyses rather than lipomas. First, several authors [2, 3] have reported visualizing hyperintense signal in the posterior pituitary gland in 90-100% of patients with normal pituitary glands. This has been our experience also. In fact, the absence of the bright signal has been the basis for the majority of the papers that describe ectopic pituitary tissue in diseased states. We think that absence of the hyperintense posterior pituitary signal is unusual and, in most cases, significant.

Second, the posterior pituitary signal is brighter than fat signal in the dorsum and clivus on proton-density and T2-weighted images [2, 3]. This is shown clearly in our two cases. Pure lipomas would have considerably lower signal on these sequences. The ectopic posterior



pituitary tissue contained signal characteristics identical to what would be expected normally within the sella.

Third, ectopic neurohypophyses occur in a distinctly different anatomic location than suprasellar lipomas do. Our cases show non-descended posterior pituitary tissue along the hypothalamoneurohypophyseal tract within the median eminence. We agree with Dr. Abrahams that Figure 6 in the article by Truwit and Barkovich [4] shows a lipoma. All of the suprasellar lipomas they reported occurred posterior to the median eminence within the tuber cinereum and mamillary body region. The anterior lesions in our cases 1 and 2 are both anterior to the usual location of lipomas and are ectopic neurohypophyses. The lack of hypogenesis of adjacent structures, often seen with lipomas [4], was absent in our cases, also supporting the presence of ectopic neurohypophyses. We do concede, however, on the basis of the article by Truwit and Barkovich, that the posterior lesion in our case 1 is probably a lipoma, which explains the chemical-shift artifact present.

Finally, Dr. Abrahams's review of the world literature had an oversight. Brooks et al. [5] reported a case identical to ours in their Figure 6: "Normal variant of posterior pituitary bright signal in median eminence of hypothalamus." We agree with Brooks et al. that this entity does occur.

Barry H. Katz

Muhlenberg Regional Medical Center, Inc.  
Plainfield, NJ 07061

Ericha R. Benshoff

The Reading Hospital and Medical Center  
Reading, PA 19603

#### REFERENCES

1. Benshoff ER, Katz BH. Ectopia of the posterior pituitary gland as a normal variant: assessment with MR imaging. *AJNR* 1990;11:709-712
2. Colombo N, Berry I, Kucharczyk J, et al. Posterior pituitary gland: appearance on MR images in normal and pathologic states. *Radiology* 1987;165:481-485
3. Fujisawa I, Asato R, Nishimura K, et al. Anterior and posterior lobes of the pituitary gland: assessment by 1.5 T MR imaging. *J Comput Assist Tomogr* 1987;11:214-220
4. Truwit CL, Barkovich AJ. Pathogenesis of intracranial lipoma: an MR study in 42 patients. *AJNR* 1990;11:665-674, *AJR* 1990;155:855-864
5. Brooks BS, El Gammal T, Allison JD, Hoffman WH. Frequency and variation of the posterior pituitary bright signal on MR images. *AJNR* 1989;10:943-948, *AJR* 1989;153:1033-1038

#### Commentary

I am pleased to have the opportunity to comment on the letters to the editor by Drs. Abrahams and Berns, who disagree with the findings of the paper [1] "Ectopia of the Posterior Pituitary Gland as a Normal Variant: Assessment with MR Imaging," by Benshoff and Katz. Dr. Berns also takes issue with the labeling of Figure 6 in an article by Truwit and Barkovich [2], which he thinks is labeled incorrectly as a lipoma. I also have reviewed the reply of Drs. Benshoff and Katz to the original letter of Dr. Abrahams. The essence of the disagreement is whether the two cases described in the paper by Benshoff and Katz [1] and Figure 6 in the paper by Truwit and Barkovich [2] are ectopic posterior pituitary glands or lipomas.

Benshoff and Katz contend that high-intensity nodules present in the suprasellar and interpeduncular cisterns in two endocrinologically normal persons are ectopic posterior lobes. They base their argument on anatomic location and signal characteristics. They describe the locations of the nodules as the superior portion of the infundibulum in one case and in the median eminence in the other. They describe the MR characteristics as bright on T1-weighted images and dimin-

ished, but remaining brighter than fat, on proton-density and T2-weighted images. One case is described as showing chemical-shift artifact. Specific comment is not made on the presence or absence of chemical shift in the other case. The usual intrasellar high-intensity signal of the posterior lobe was not visible in either case.

Although the actual chemical source of the signal in the posterior lobe remains controversial, it is my opinion that relatively widespread agreement exists on the following points:

1. Visualization of the high-signal intensity in the posterior lobe indicates a hormonally intact hypothalamoneurohypophyseal system. Nonvisualization of the high signal on MR occurs in 10% to 20% of control subjects. I think that nonvisualization probably is due to the small size of the lobe or an eccentric location. Therefore, I believe undue diagnostic significance should not be placed on nonvisualization; more often than not, patients who do not have this signal do not have abnormalities.
2. The high signal is due to a neurosecretory product stored in the posterior lobe, whether that product be vasopressin, neurophysin, the phospholipid vesicular membrane, or some combination thereof. The high signal is always absent in patients who have central diabetes insipidus.
3. The signal does not originate from lipid protons and therefore does not have a chemical shift associated with it [3]. We have shown that phospholipid vesicles have a similar signal to that observed in the posterior lobe but that phospholipid signal originates from water protons interacting with the phospholipid membrane, not from the lipid moiety itself [4]. Therefore, if a phospholipid does play a role in the generation of the signal, a chemical shift would not be expected [4].
4. Injury to the hypothalamoneurohypophyseal tract can cause an accumulation of the neurosecretory product in a suprasellar location. However, the "ectopic" location is always along the anatomic path of that tract; that is, it must be in the pituitary stalk or the median eminence.

On the basis of these anatomic and MR criteria, I cannot accept that the cases presented by Benshoff and Katz are ectopic posterior lobes. In both cases, the sagittal images clearly show that the nodules are posterior to the stalk and median eminence. I think that this also is the case in Figure 6 in the Truwit and Barkovich paper [2] alluded to by Dr. Berns. The case shown in Figure 6 is identified properly as a lipoma and also falls into the 10-20% range of normal posterior pituitary lobes in which the posterior pituitary bright spot is not visualized on MR.

The coronal image in case 1 in the paper by Truwit and Barkovich is misleading. Because of the obliquity of the stalk, the nodule appears in the same coronal plane as the inferior portion of the stalk; the anterior sloping of the stalk must be recognized to avoid this error. In case 2, the lesion is in the floor of the third ventricle posterior to the median eminence. As far as signal is concerned, chemical shift is readily apparent in the first case, indicating the presence of signal from fat protons and therefore further disqualifying this nodule from consideration as an ectopic posterior lobe. It is difficult to be sure of chemical shift in the second case. In this location, it is difficult to detect chemical shift on T1-weighted images because fat becomes superimposed on dark CSF; the summation of signal is poorly demonstrated. I suspect that chemical shift is present on the proton-density image. The fat signal is shifted anteriorly, becoming superimposed on suprasellar CSF, and it has been misinterpreted as high signal from the lesion itself.

In summary, it is my opinion that Dr. Abrahams's criticisms of the article by Benshoff and Katz [1] are valid. Dr. Berns is correct in his criticism of the cases presented by Katz and Benshoff but not in his criticism of the paper by Truwit and Barkovich [2]. I do not think that an ectopic neurohypophysis can be considered a normal variant. I



believe that the presence of an ectopic neurohypophysis always indicates an injury to the hypothalamoneurohypophyseal tract, although that injury may be temporally remote.

The two cases illustrated in the paper by Benshoff and Katz have imaging characteristics much more in keeping with lipomas than with ectopic neurohypophyses.

Walter Kucharczyk  
Toronto General Hospital  
Toronto, Ontario, Canada M5G 2C4

## REFERENCES

1. Benshoff ER, Katz BH. Ectopia of the posterior pituitary gland as a normal variant: assessment with MR imaging. *AJNR* 1990;11:709-712
2. Truwit CL, Barkovich AJ. Pathogenesis of intracranial lipoma: an MR study in 42 patients. *AJNR* 1990;11:665-674, *AJR* 1990;155:855-864
3. Fujisawa I, Asato R, Nishimura K, et al. Anterior and posterior lobes of the pituitary gland: assessment by 1.5 T MR imaging. *J Comput Assist Tomogr* 1987;11:214-220
4. Kucharczyk W, Lenkinski RE, Kucharczyk J, Henkelman RM. The effect of phospholipid vesicles on the NMR relaxation of water: an explanation for the MR appearance of the neurohypophysis? *AJNR* 1990;11:693-700

**Editor's note.**—See related article by Mark et al. on pages 529-532 in this issue.

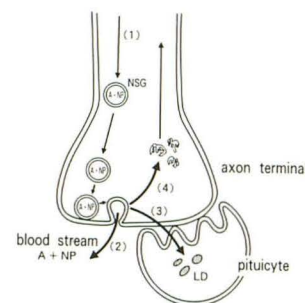
## Hyperintense Signal on MR Images of the Pituitary Gland

The source of the hyperintense signal in the posterior lobe of the pituitary gland on T1-weighted MR images is controversial. In 1987, my colleagues and I [1] hypothesized that the signal reflects the functional integrity of the hypothalamoneurohypophyseal system and that the probable source of the signal is neurosecretory granules. Subsequently, Kucharczyk's group [2] proposed the hypothesis that lipid droplets within the pituicytes are the source of the hyperintense signal. In 1988, they reported an experimental study [3] and concluded that the lipid droplet theory or the neurosecretory granule theory was correct. In the paper "The Effect of Phospholipid Vesicles on the NMR Relaxation of Water: An Explanation for the MR Appearance of the Neurohypophysis?" [4] in the July/August 1990 issue of the *AJNR*, they proposed a newer hypothesis: the phospholipid theory. The phospholipid theory states that the high concentration of the total phospholipid in the posterior lobe, existing mainly in the lipid droplets within the pituicytes and in the membranes of the axons and the neurosecretory granules, is the source of the hyperintense signal. I read their paper with great interest and found some problems.

In their discussion (p. 697 in [4]), they describe what they had done and mention the saline overload experiment in their 1988 paper [3]. In fact they did not do this experiment. In 1989, my colleagues and I [5] reported an experimental study that showed that the hyperintense signal in the posterior lobe disappeared after 2 weeks of administration of hypertonic saline solution, which stimulated the release of antidiuretic hormone from the posterior lobe. In their 1988 experiment, Kucharczyk et al. observed that the hyperintense signal increased in volume under the stimulation of release of antidiuretic hormone. The results of the two experiments were quite opposite. Which result is correct is the key to solving the controversy.

Previously, my colleagues and I [6] indicated several serious problems in the 1988 experiment. Here, I point out an additional one, which contradicts the phenomenon Kucharczyk et al. observed in the posterior lobe. An understanding of the mechanism of hormone release at the axon terminal is necessary for evaluation of their 1988 and 1990 experiments and our 1989 experiments.

**Fig. 1.—Diagram of axon terminal.** Neurosecretory granules (NSGs) containing antidiuretic hormone (A)—neurophysin (NP) complex are transported to axon terminal in posterior lobe (1). At axon terminal, contents of NSGs are released into blood-stream by exocytosis when A and NP separate (2). Membranes of NSGs become excessive when release of A is stimulated. Two hypotheses about the fate of the excessive membrane have been proposed: It is phagocytosed by pituicytes to form lipid droplets (LD) (3), or it migrates up the axon to the hypothalamus for reuse (4). Phospholipid exists in LDs within pituicytes and in membranes of NSGs, axons, and pituicytes. When function of posterior lobe is stimulated, the number of NSGs in posterior lobe decreases, but excessive membranes of NSGs and total phospholipid increase.



Glial cells in the posterior lobe are called pituicytes. Historically, it was known that lipid droplets exist within the pituicytes, especially in the rat [7]. At first, researchers thought that the pituicytes were glandular cells and that the lipid droplets were secretory granules. Those ideas were disproved by two new findings. One was the neurosecretory theory. The other was that two of the posterior lobe hormones, antidiuretic hormone and oxytocin, were found to be oligopeptides and not lipids. Some researchers [8, 9] concluded that the pituicytes were not related to the function of the posterior lobe. Still others [10, 11] proposed that excessive membranes of the neurosecretory granules at exocytosis are the source of the lipid droplets in the pituicytes (Fig. 1). They observed that the number of droplets increased when the function of the posterior lobe was stimulated. The number of neurosecretory granules decreased under such conditions. In their 1988 paper, Kucharczyk et al. [3] reported that they had observed a significant increase of both lipid droplets and neurosecretory granules in dehydration-stimulated animals. The neurosecretory granules should decrease under such conditions. Concerning the fate of the excessive membranes of the granules, another hypothesis is that the granules migrate in the axon up to the hypothalamus for reuse [12] (Fig. 1). Synthesis and release of antidiuretic hormone is thought to increase the excessive membranes at the axon terminals and consequently to increase the total amount of phospholipid in the posterior lobe because the membranes contain phospholipid. Thus, both the lipid droplet and the phospholipid theories do not explain the absence of the hyperintense signal observed in the posterior lobe in the hypertonic saline overload experiment.

In their results, Kucharczyk et al. [4] concluded that the pattern of signal intensities of liposome solutions was similar to that of the human posterior lobe. However, I believe that the liposome solutions had signal intensities markedly higher than those of the posterior lobes of volunteer subjects on proton-density and T2-weighted MR images (Figs. 3B and 3C in [4]). I think that it is incorrect to equate the liposome solutions and the human posterior lobe model. The significance of the 1990 experiment [4] is that the liposome, the size of which is similar to that of the neurosecretory granule in the posterior lobe, induced a remarkable shortening of relaxation times. I think that the mechanism observed in the 1990 experiment may explain the neurosecretory granule theory.

In 1987, my colleagues and I [13] first reported the ectopic posterior lobe in patients with pituitary dwarfism and hypothesized that the ectopic lobe is caused by stalk transection at birth because of the high correlation with abnormal delivery. In 1988, Kucharczyk's

phoma, angioliipoma, and, as described, cavernous hemangioma. Administration of contrast agent also might be helpful in preoperative differential diagnosis.

Alison B. Haimes  
Memorial Sloan-Kettering Cancer Center  
New York, NY 10021  
George Krol  
SJK Magnetic Resonance Imaging  
New York, NY 10021

#### REFERENCES

1. Feider HK, Yuille DL. An epidural cavernous hemangioma of the spine. *AJNR* 1991;243:244
2. Guthkelch AN. Hemangioma involving the spinal epidural space. *J Neurol Neurosurg Psychiatry* 1948;11:199-210
3. Brobeck O. Hemangioma of the vertebra associated with compression of the spinal cord. *Acta Radiol* 1950;34:235-243
4. Padovani R, Poppi M, Pazzati E, Tognetti F, Querzola C. Spinal epidural hemangiomas. *Spine* 1981;6(4):336-340
5. Cohen EK, Kressel HY, Perosio T, et al. MR imaging of soft-tissue hemangiomas: correlation with pathologic findings. *AJR* 1988;150:1079-1081
6. Buetow PC, Kransdorf MJ, Moser RP Jr, Jelinek JS, Berry BH. Radiologic appearance of intramuscular hemangioma with emphasis on MR imaging. *AJR* 1990;154:563-567
7. Burk DL Jr, Brunberg JA, Kanal E, Latchaw RE, Wolf GL. Spinal and paraspinal neurofibromatosis: surface coil MR imaging at 1.5 T. *Radiology* 1987;162:797-801

---

## Erratum

In the commentary by Kucharczyk that followed the letters to the editor by Abrahams and by Berns and the reply by Katz (*AJNR* 1991;12:580-581), the first sentence of the fifth paragraph should read "The coronal image in case 1 in the paper by Benshoff and Katz [not Truwit and Barkovich, as printed] is misleading." *AJNR* apologizes for this error.