



**Providing Choice & Value**

Generic CT and MRI Contrast Agents



FRESENIUS  
KABI

CONTACT REP

**AJNR**

**MR imaging of the brain in patients with  
migraine headaches.**

R E Osborn, D C Alder and C S Mitchell

*AJNR Am J Neuroradiol* 1991, 12 (3) 521-524

<http://www.ajnr.org/content/12/3/521>

This information is current as  
of July 20, 2025.

# MR Imaging of the Brain in Patients with Migraine Headaches

Robin E. Osborn<sup>1,2</sup>  
Daniel C. Alder  
Craig S. Mitchell

Forty-one patients with migraine headaches were referred for MR imaging of the brain. Intermediate and T2-weighted images were obtained to determine the frequency of areas of high intensity within the white matter. The average age of these patients was 29.8 years; only five were over 40 years old. Each patient was evaluated in the axial plane with long TR/short and long TE images. Twenty-three patients also had T1-weighted short TR/short TE MR scans; enhancement with gadopentetate dimeglumine was used in three patients. Intracranial abnormalities were seen in only six patients: foci of white matter high intensity on intermediate and T2-weighted images in five and a venous angioma in one. Prior studies have indicated that parenchymal brain abnormalities may be found in up to 46% of patients with migraines. The current study demonstrated parenchymal brain lesions in only 12%.

This study suggests that the frequency of foci of high intensity seen on long TR sequences in the migraine patient is much lower than previously reported, especially in patients under 40 years old (5.5% in our series).

*AJNR* 12:521-524, May/June 1991; *AJR* 157:August 1991

Until the advent and widespread use of MR imaging for the evaluation of the brain in patients with migraine headaches, CT was the primary method of radiologic screening. The CT results were usually normal, although atrophy, ischemic changes, and cerebral edema have been reported [1-3].

Only a few reports on the MR evaluation of patients with migraine headaches have appeared in the literature [4-6]. The prevalence of MR abnormalities in these patients has been considered to be relatively high. Previous authors found high-signal white matter foci on long TR images in migraineurs 17-46% of the time [4-6]. Since this has not been our experience, a prospective study was performed to determine the prevalence of such white matter abnormalities.

## Subjects and Methods

Forty-one patients who had been clinically diagnosed as having migraine headaches were evaluated prospectively with MR. These patients represented 41 consecutive referrals for brain MR from the neurology clinic at the Naval Hospital, San Diego, CA. Entry into the study was based on the clinical diagnosis of migraine, regardless of the patient's age and duration and severity of symptoms. Each patient was followed in the neurology clinic for 3-18 months. The criteria for diagnosis were based on a pattern of pulsatile recurrent headaches dating from childhood or adolescence, the presence of a positive family history, and other clinical factors including scintillating scotoma, aura, subjective neurologic findings, headache that was sickening or disabling, and usually a normal neurologic examination.

The current study group comprised 24 men and 17 women. Thirty-one patients had common migraine, four had classical migraine, four had complicated migraine, and one each had basilar artery and orbital migraines. All of the MR scans were interpreted by a neuroradiologist. The average age of the patients was 29.8 years (range, 18-66 years). Only five patients were over 40 years old. Review of patients' records indicated that five patients

Received August 24, 1990; revision requested November 17, 1990; revision received December 10, 1990; accepted January 1, 1991.

The views expressed in this article are those of the authors and do not reflect the official policy or position of the Department of the Navy, the Department of Defense, nor the U.S. Government.

This work was supported by The Chief, Navy Bureau of Medicine and Surgery, Washington, DC, Clinical Investigation Program, study #90-16-2749-00.

<sup>1</sup> All authors: Departments of Radiology and Clinical Investigation, Naval Hospital, San Diego, CA 92134-5000.

<sup>2</sup> Present address: Department of Radiology, Children's Memorial Hospital, 2300 Children's Plaza, Chicago, IL 60614. Address reprint requests to R. E. Osborn.

0195-6108/91/1203-0521



smoked cigarettes, one was hypertensive, one had unilateral sensorineural hearing loss, one had somatic hemiatrophy, three had remote head injuries, one took birth control pills, one was pregnant, and one had had renal lithiasis 12 years earlier. Of the patients with additional medical problems, only the patient with previous renal lithiasis had white matter lesions.

The MR studies were performed with four scanners: a 1.5-T Siemens (Iselin, NJ) Magnetom SP unit (19 patients), a 0.35-T Diasonics (Milpitas, CA) unit (14 patients), a 1.0-T Siemens Magnetom unit (three patients), and a 1.5-T General Electric (Milwaukee, WI) Signa unit (five patients). All of the scans included long TR/short and long TEs, 2500–3000/25–30, 80–90 (TR/TE), axial images. Short TR/short TE sagittal, coronal, or axial images were obtained in 23 patients. Three patients received IV gadopentetate dimeglumine. Matrix size was 128 × 256 for the General Electric scanner and 256 × 256 for the others. The field of view was 23 or 24 cm. Slice thicknesses were 5 or 6 mm.

## Results

Foci of high signal intensity involving the white matter were detected on long TR scans in five of the 41 patients. Three (two women and one man) of the five patients were over 40 years old (43, 50, and 66 years old); the other two were 30- and 36-year-old men. Of the 36 migraineurs in whom foci of high intensity were not seen, only two were over 40 years old (41- and 44-year-old men). The other 34 patients were 18–37 years old and included 15 women and 19 men.

Three of the five abnormal MR scans with abnormal white matter lesions had only one or two foci of abnormality (Fig. 1). The remaining two abnormal scans each had multiple bilateral white matter lesions (Fig. 2). No cortical lesions were seen in any of the patients. A left frontal lobe venous angioma was seen in one patient; mild to moderate degrees of chronic sinus changes manifested by mucosal thickening and retention cysts were seen in 15 patients. None of the findings in

these 16 patients were clinically considered to be related to a migraine symptomatology.

Four patients had neurologic findings and thus were classified as having complicated migraines. In only one of these patients was the MR scan abnormal. Three of the five MR scans positive for white matter lesions were obtained in three of the five patients over the age of 40 (Table 1). Enhancement with gadopentetate dimeglumine resulted in no additional findings.

## Discussion

Approximately 20% of all headaches are of the migraine type and this was the first specific type of headache to be classified [7]. Migraine headaches are associated with an initial vasoconstriction of the cerebral vasculature, which may be associated with relative cerebral ischemia. This may partially explain or suggest a theory for the aura, the clinical findings associated with classical migraine and the possible ischemic genesis for the white matter lesions seen with MR. Later cerebral vasodilatation results in the pulsatile headache. Numerous vasoactive substances have been implicated and investigated as possible contributors to the development of migraine headaches [7–9].

The origin of migraine headache remains incompletely understood, as is the cause of the white matter lesions identified with MR in some of the patients so affected [7]. We found only three MR studies in the literature that specifically addressed migraine headaches [4–6]. These authors described the findings in 24, 18, and nine patients; white matter abnormalities were found in 46%, 33%, and 17% of cases, respectively, for a combined average of 33% (17/51). Kaplan et al. [6] presented nine patients with a mean age of 39.8 years; the three patients with abnormal MR scans were aged

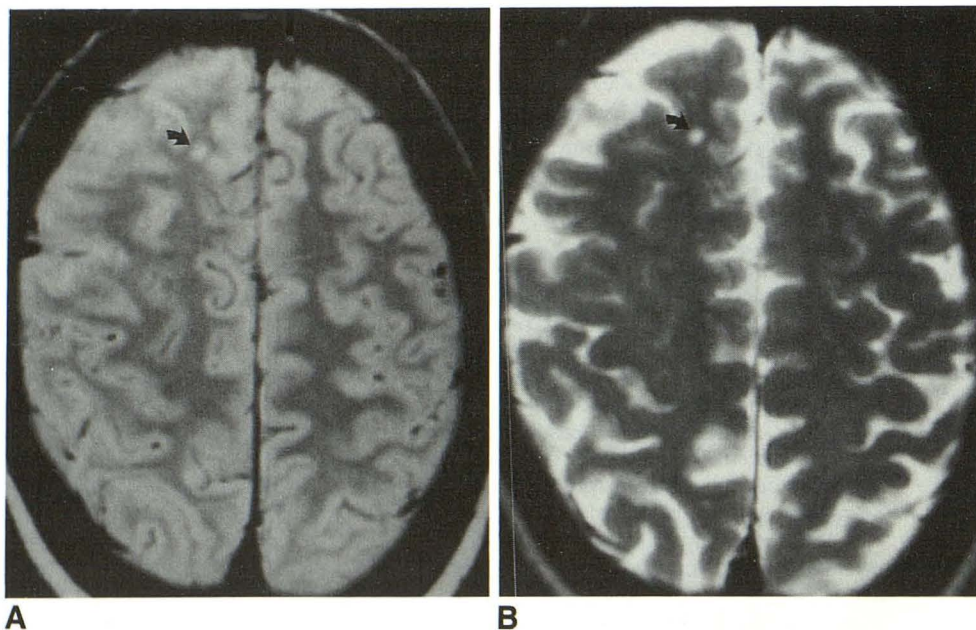


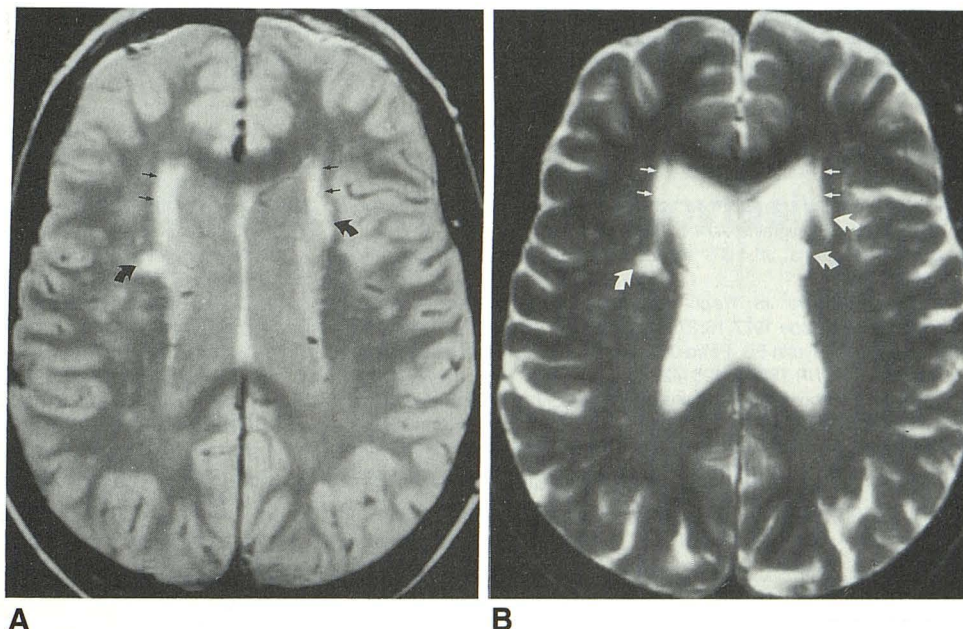
Fig. 1.—43-year-old woman with basilar artery migraine.

A and B, Focal high-intensity subcortical white matter lesion involving right frontal lobe (arrows) seen on axial long TR/short TE (2800/25) scan (A) is also present on long TR/long TE (2800/90) scan (B). Additional lesions were present on other sections.



Fig. 2.—66-year-old woman with common migraine.

A and B, Multiple bilateral periventricular foci of high intensity seen within white matter (curved arrows) on long TR/short TE scan (A) are also delineated on long TR/long TE scan (B). These scans also show "normal" periventricular halo (straight arrows).



24, 49, and 56. The average age of the 18 patients in the report by Jacome and Leborgne [5] was 30 years, which was similar to that in our patient group. The ages of their patients with abnormal MR scans were 34, 37, and 38. Soges et al. [4] reported the largest series to date of migraine patients studied with MR. The average age of their patients was 36.8 years. The average age of the 11 patients with an abnormal MR result was 36.4 years, whereas the average age of the 13 patients with normal MR scans was 33.8 years. Six of the 11 abnormal and four of the 13 normal patients were over 40 years old. In our study, the average age of the five patients with abnormal MR scans was 45 years (range, 30–66), whereas the average age of the 36 subjects with normal scan results was about 28 years (range, 18–44). Current and previous studies demonstrate that the older patients with migraines tend to be those most often shown to have foci of high signal intensity of the white matter on intermediate and T2-weighted images. Still, it was interesting to note that even when considering the patients of Soges et al. [4] who were

under the age of 40 years, 27% were found to have white matter abnormalities. This is approximately five times more than the 5.5% found in the 36 patients in our study under 40 years of age.

Although precise data do not appear to be available, normal young persons have a low rate of white matter lesions whereas elderly people have a higher rate of such lesions (30–80%) with increasing age [10–14]. The presence of white matter, high-intensity foci on long TR scans is typically non-specific and may represent or appear similar to a variety of pathologic conditions including atrophic perivascular demyelination, vascular malformations, white matter infarction, or multiple sclerosis [4, 11]. More white matter lesions are detected on MR in older patients with migraine headaches than in their younger counterparts. Five of the 17 patients with abnormal MR scans described in this and other articles [4–6] were over the age of 50 years and six of the 17 were between the ages of 40 and 49 years. Our data also showed that MR findings tended not to be abnormal in young migraineurs.

There is a variety of possible explanations for the increased frequency of abnormal white matter foci found in migraineurs over the age of 40 years. Advancing age is a consideration, especially in combination with a long duration of migraine headaches or severe or complicated migrainous events. Whether or not there is an increased prevalence of such high-intensity white matter foci in young normal vs young migraine patients (5.5% in this study) is not known and would require specific study.

In conclusion, foci of high intensity involving the white matter on intermediate and long TR MR images appear to be found less commonly in all migraineurs than previously thought, and their prevalence in younger patients is lower still. However, a relatively increased prevalence of white matter lesions in older migraineurs has yet to be proved. We suggest that these lesions may be due in part to the intolerance of an

TABLE 1: Summary of Findings in Migraine Patients with Foci of High Intensity on MR

Age (yr)	Sex	MR Findings	Diagnosis
43	F	Multiple 2- to 4-mm, round, bilateral, subcortical white matter lesions	Basilar artery migraine
50	M	Single 2-mm, right-sided, periventricular white matter lesion	Complicated migraine
36	M	One 3-mm oval, left frontal, subcortical white matter lesion; one 5-mm, oval, insular, subcortical white matter lesion	Common migraine
66	F	Multiple bilateral, subcortical, periventricular, 2- to 8-mm round and oval white matter lesions	Common migraine
30	M	Single 4-mm, oval, periventricular, left frontal white matter lesion	Common migraine

aging brain to the stresses of migrainous events long in duration or of a severe nature.

## REFERENCES

1. Du Boulay GH, Ruiz JS, Rose FC, Stevens JM, Zilkha KJ. CT changes associated with migraine. *AJNR* **1983**;4:472-473
2. Cuëtter AC, Alta JF. CT scanning in classic migraine. *Headache* **1983**;23:195
3. Mathew NT, Meyer JS, Welch KMA, Neblett CR. Abnormal CT scans in migraine. *Headache* **1977**;16:272-279
4. Soges LJ, Cacayorin ED, Petro GR, Ramachandran TS. Migraine: evaluation by MR. *AJNR* **1988**;9:425-429
5. Jacome DE, Leborgne JL. MRI studies in basilar artery migraine. *Headache* **1990**;30:88-90
6. Kaplan RD, Solomon GD, Diamond S, Freitag FG. The role of MRI in the evaluation of a migraine population. Preliminary data. *Headache* **1987**;27:315-318
7. Raskin NH. Migraine: clinical aspects and pathogenesis. In: Raskin NH, ed. *Headache*, 2nd ed. New York: Churchill Livingstone, **1988**:35-133
8. Posner JB. Headache and other pain. In: Wyngaarten JB, Smith LH, eds. *Cecil textbook of medicine*. Philadelphia: Saunders, **1988**:2129-2136
9. Johnson CE, Zimmerman RD. Imaging decisions in the evaluation of headache. *Magn Reson Imaging Decisions* **1989**;3:2-16
10. Brant-Zawadzki M, Fein G, Van Dyke C, Kiernan R, Davenport L, de Groot J. MR imaging of the aging brain: patchy white matter lesions and dementia. *AJNR* **1985**;6:675-682
11. Kirkpatrick JB, Hayman LA. White-matter lesions in MR imaging of clinically healthy brains of elderly subjects: possible pathologic basis. *Radiology* **1987**;162:509-511
12. Drayer BP. Imaging of the aging brain: Part I. Normal findings. *Radiology* **1988**;166:785-796
13. Braffman BH, Zimmerman RA, Trojanowski JQ, Gonatas NK, Hickey WF, Schlaepfer WW. Brain MR: Pathologic correlation with gross and histopathology. 2. Hyperintense white-matter foci in the elderly. *AJNR* **1988**;9:629-636
14. Hendrie HC, Farlow MR, Austrom MG, Edwards MK, Williams MA. Foci of increased T2 signal intensity on brain MR of healthy elderly subjects. *AJNR* **1989**;10:703-707